

Treatment of glenohumeral chondral defects

TIMOTHY S. LEROUX and BRIAN J. COLE

Q1 

CONTENTS

Indication	257
Operation principal	257
Preoperative assessment	258
Diagnosis	258
Clinical examination	258
Imaging: X-ray	258
Imaging: MRI/CT	258
Strategy	258
Preoperative patient information and consent	258
Operative technique	259
Postoperative management	261
Follow-up treatment	262
Tips, tricks, and pitfalls	262
Literature	262
Microfracture	262
Osteochondral autograft transfer	262
Osteochondral allograft transfer	262
References	262

INDICATION

The indication for surgical management of a glenoid or humeral head articular cartilage lesion is the failure of non-operative treatment with ongoing symptoms that include pain, joint effusion, and/or mechanical symptoms. Prior to undertaking a surgical procedure, as outlined in this chapter, the surgeon should be thorough in documenting the extent of cartilage involvement (size, location, and depth), and the presence of bipolar cartilage lesions or more extensive osteoarthritic change. This will allow the surgeon to appropriately counsel the patient on expected procedure, outcome, and natural history. From the surgeon's perspective, it will also allow for appropriate organization of surgical instruments, and, if needed, osteochondral allograft availability.

OPERATION PRINCIPAL

The main surgical principles for the management of an articular cartilage lesion in the glenoid or humeral head includes appropriate surgical planning (assessment of lesion size, number, and location), intraoperative lesion assessment (confirmation of lesion size, number, and location), and thorough debridement of the lesion to remove unstable cartilage flaps and ensure the entire extent of the lesion has been identified. It is also imperative that the surgeon have some idea as to the etiology of the cartilage lesion so as to address any associated pathology or injury that may compromise the outcome of the cartilage restoration procedure (for example, ongoing instability). The surgeon must be well versed in available reparative (microfracture) and restorative (osteochondral autograft

and allograft transplantation) cartilage procedures, and be able to tailor the procedure to patient- and lesion-specific characteristics to optimize outcome.

PREOPERATIVE ASSESSMENT

Diagnosis

CLINICAL EXAMINATION

The clinical exam should start with a detailed history, including location, severity, quality, and frequency of the pain. Activities that exacerbate the pain should be well understood, alongside any potential mechanical symptoms such as locking, catching, crepitus, and persistent or intermittent effusions. A history of trauma and surgery to the shoulder in question should be documented. It is also important to understand the patient's occupation and recreational activities, specifically a history of repetitive shoulder use or heavy labor. Given that it is not uncommon for patients with symptomatic, full-thickness cartilage lesions to provide a history of vague shoulder complaints, perhaps the most important aspect of the history should be determining the presence or absence of any other common shoulder conditions, which may also provide insight into the etiology of the cartilage lesion in question. Lastly, previous non-operative and operative treatment should be documented, including a history of prior injections, physical therapy, modifications to activity or work, and the details of any past surgery to the affected shoulder.

Following the history, a physical examination should be undertaken comparing the affected shoulder with the contralateral shoulder. Particular attention should be paid to differences in active and passive range of motion, the presence of crepitus or catching with passive motion, rotator cuff strength, pain with compressive loading of the shoulder, and the presence of any surgical scars and muscle atrophy. The examination should also rule out any associated glenohumeral pathology, specifically glenohumeral instability. Lastly, a detailed neurological and vascular examination should be completed and documented.

IMAGING: X-RAY

Pre-operative patient evaluation should always include plain radiographs of the glenohumeral joint, including a true a.p. view, a scapular-Y view, and an axillary view. The main purpose of this imaging modality is to identify changes consistent with more generalized primary or secondary glenohumeral osteoarthritis, such as joint space narrowing, osteophyte formation (inferior humeral osteophyte, the so-called "Goat's Beard"), subchondral sclerosis or cysts, or superior humeral head migration. If there is any concern for the presence of glenohumeral instability, the surgeon may also obtain two additional radiographic views, the Stryker notch view and West Point view, which are helpful in evaluating Hill-Sachs lesions and glenoid bone loss, respectively.

IMAGING: MRI/CT

The best imaging modality to assess full thickness cartilage lesions is magnetic resonance imaging (MRI); however, it is not uncommon for even full-thickness lesions to be missed, given the relatively thin cartilage overlying the glenohumeral joint. In reviewing an MRI to identify cartilage pathology, specifically fissuring, delamination, and full-thickness loss, the surgeon should focus on the T2-weighted image with or without fat suppression, and a T1-weighted fat-suppressed cartilage-sensitive sequence. Additional MRI techniques targeting the identification of cartilage pathology exist, including delayed gadolinium-enhanced MRI of cartilage (dGEMRIC), T1rho, and T2 mapping, but these may not be readily available at all centers. In addition to the integrity of the cartilage, the surgeon should also evaluate the subchondral bone, as well as the presence of any loose bodies, joint effusions, and soft tissue pathology. The surgeon should also document lesion containment, as this can impact treatment options and give insight into a potential etiology (peripheral lesions may be more commonly associated with glenohumeral instability).

In addition to MRI, a CT scan can also be helpful to further assess for the presence of more generalized osteoarthritis changes, bone loss, and glenoid version and erosion. This imaging modality is particularly important for patients who may require bone grafting.

Strategy

The overall strategy in the preoperative evaluation of patients with a glenohumeral articular cartilage lesion is to ensure the patient symptoms are the result of the cartilage lesion(s) in question, rather than an incidental finding that does not require treatment. This is the most challenging aspect of the patient evaluation and requires the surgeon to be diligent during all phases of the evaluation, so as not to miss any associated shoulder conditions that could otherwise account for the patient's symptoms or compromise the outcome of any potential surgical intervention. We treat cartilage lesions in the shoulder as a diagnosis of exclusion, whereby all other potential shoulder conditions are ruled out prior to concluding the patient symptoms are caused by the cartilage lesion(s) identified on the available imaging.

Preoperative patient information and consent

Aside from the general risks associated with any surgical procedure and anesthetic, the reported outcomes of surgery for glenohumeral cartilage lesions have been quite variable, so the patient should be aware that there is the possibility of persistent symptoms following the surgery, particularly if the procedure is a revision, the lesion is

larger ($>2 \text{ cm}^2$), the lesion is uncontained, there is bipolar disease, there is evidence of early generalized arthritic change, or there is associated shoulder pathology, such as rotator cuff injury or instability. Furthermore, the patient should be aware that cartilage procedures are intended to address symptoms, and may not change the underlying natural history of any associated arthritic condition. Depending on the procedure being undertaken, there is also an increased risk of stiffness, potentially requiring a second operation. Lastly, if an osteochondral allograft is being performed, the patient should be made aware of the small risk for disease transmission, non-union, and graft resorption.

OPERATIVE TECHNIQUE

- a. All shoulder procedures to address glenoid and/or humeral articular cartilage defects are done in the beach chair position using an arm positioner. All procedures start with a diagnostic shoulder arthroscopy to not only identify the lesion in question, but also identify any associated pathology that may require treatment. Following a thorough debridement of the lesion(s) in question, including removing unstable cartilage flaps, an evaluation is done to determine depth, size, and containment. Based on this intraoperative assessment, a final decision is made regarding treatment. For most contained defects, we perform microfracture as it is minimally invasive and easy to perform. For uncontained peripheral defects, we have had some success with microfracture plus labral advancement onto the defect. For isolated larger lesions or for patients who fail microfracture, we prefer osteochondral allograft transplantation, but given its associated cost and potential challenges with graft availability, osteochondral autograft transplantation is also a reasonable option, albeit with the added morbidity of graft harvest from the knee. These two procedures are significantly more invasive as compared microfracture, so as previously noted we typically reserve them for patients who have failed prior surgical treatment. We rarely perform autologous chondrocyte implantation or biologic resurfacing in the shoulder, given literature to suggest their inferiority and our poor experience with these techniques in the shoulder. As such, these techniques are not discussed in this chapter.
- b. *Microfracture.* Once the lesion has been thoroughly debrided and unstable cartilage flaps removed, a ring curette is used to create a stable and perpendicular cartilage wall. A curette, burr, or shaver is then used to remove the cartilage cap and expose bleeding subchondral bone. A microfracture awl or PowerPick© is then used to create microfracture holes in the lesion. Attention should be paid towards appropriate spacing and depth of the holes.

We typically aim for these holes to be 3–4 mm apart at a depth of 6–9 mm. Following the procedure we turn down the pump pressure to evaluate for punctate marrow bleeding from each hole. As mentioned above, peripheral glenoid lesions can be addressed in similar fashion, with the added potential to advance the labrum onto the lesion. We have done this successfully for several patients with a history of recurrent glenohumeral instability and shoulder pain, and imaging that demonstrates a labral tear and adjacent full-thickness glenoid cartilage loss (see Figures 33.1 and 33.2).

One addition to this technique, that has demonstrated some success in the knee, is the implantation of BioCartilage© (Arthrex, Naples, FL) over the microfractured defect. BioCartilage© is developed from allograft cartilage and contains the extracellular components of articular cartilage, including growth factors, type II cartilage, and proteoglycans. The theory is that it serves as a scaffold over the microfracture defect, potentially improving the quality of the formed tissue. In the technique, the arthroscopic pump is shut off following microfracture and the joint thoroughly dried at the lesion site. The BioCartilage© mixture paste is mixed with platelet-rich plasma (PRP) and placed over a thin layer of fibrin glue until just at the level of the healthy cartilage. Another layer of fibrin glue is placed over the top. The surgeon should be aware that there is little evidence pertaining to this technique in the shoulder, and it would be considered experimental.¹

- c. *Osteochondral allograft transplant.* Following the diagnostic shoulder arthroscopy, we convert to an open procedure that utilizes the deltopectoral

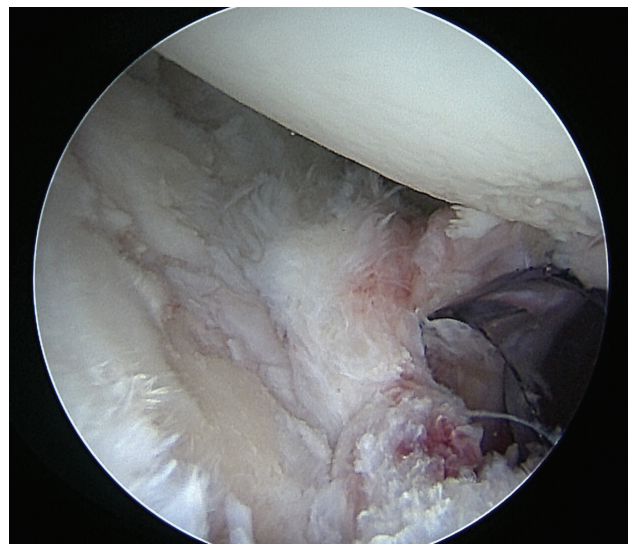


Figure 33.1 An arthroscopic image demonstrating a peripheral full-thickness articular cartilage lesion in the glenoid adjacent to a labral tear.

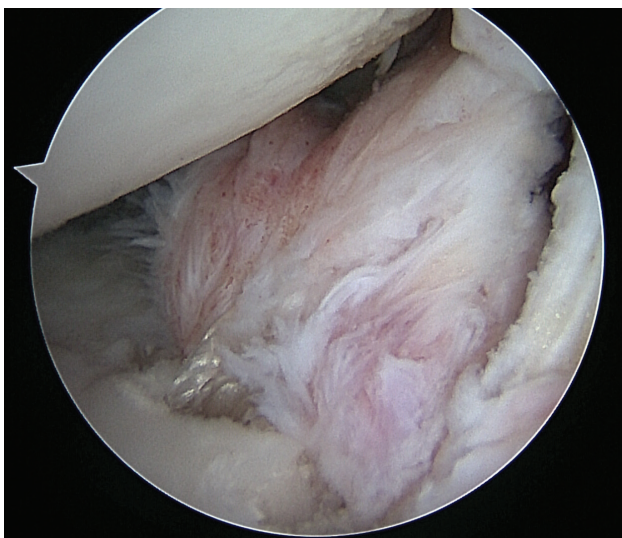


Figure 33.2 An arthroscopic image demonstrating advancement of the labral tear onto the face of the glenoid, overlying the full thickness articular cartilage defect that had previously been microfractured.

approach and interval. A subscapularis tenotomy is performed to expose the glenohumeral joint. If the lesion is readily exposed in the anterior or superior portion of the shoulder, then a limited subscapularis take down can be performed to minimize the morbidity of the procedure. The lesion is exposed, sized again, and debrided. We then turn our attention to fashioning the graft. We typically use a fresh, frozen humeral or femoral head allograft for humeral head lesions, whereas we typically use a fresh, frozen glenoid or distal tibia allograft for glenoid lesions. Fresh frozen talar dome allografts have also demonstrated a similar congruency to the humeral head and may represent an alternative graft option for humeral head defects. All grafts are obtained from commercially available systems that match the donor to the recipient. In this procedure we aim for the graft to have subchondral bone depth of 4–6 mm and a diameter that matches the recipient site. The graft is irrigated with 2–3 L of Ringer’s lactate prior to insertion. The recipient site is prepared using a drill off the commercial system at the correct size so as to encompass the entire lesion. We drill down to 4–6 mm of subchondral bone (to facilitate insertion of the graft with similar depth), but ensure we go no further than 8 mm. Care must be taken to remain centered in the lesion while drilling and irrigate throughout the drilling process to avoid unnecessary damage to adjacent healthy cartilage and subchondral bone. We try to match the radius of curvature between the graft and recipient site. Once the graft has been fashioned and the recipient site has been prepared, we carefully tamp it into place so that it is flush with native cartilage. The graft is held via a press-fit

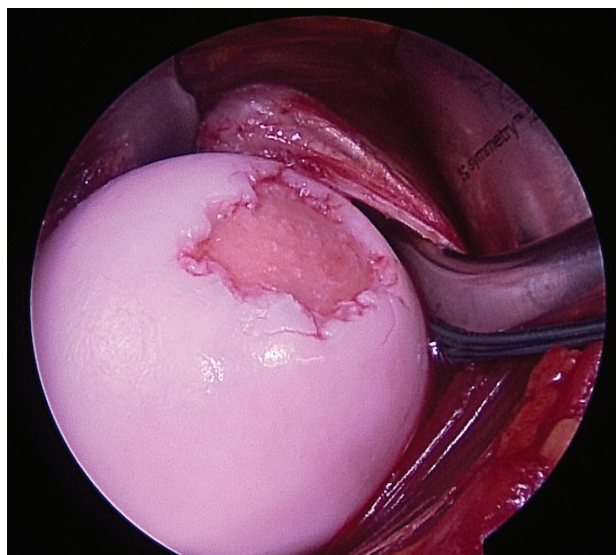


Figure 33.3 Identification of an isolated, full-thickness humeral head cartilage lesion on diagnostic arthroscopy.

technique. A thorough repair of the subscapularis is then performed, and the deltopectoral interval and approach closed in standard fashion. See Figures 33.3 through 33.9 for images reflecting the key steps of this entire procedure.

- d. *Osteochondral autograft transplant.* The approach and preparation is very similar to osteochondral allograft transplantation, including initial diagnostic arthroscopy, deltopectoral approach, and subscapularis tenotomy. In this technique, the ipsilateral or contralateral knee is used as the donor site. The graft can be harvested arthroscopically or via a small arthrotomy, depending on the preference of the surgeon. Commercially available autograft plug harvesters and implanters are used, and we typically aim for bone plugs that are 6–10 mm in diameter and 4–6 mm in depth. Care is taken to match the graft to the size and radius of curvature

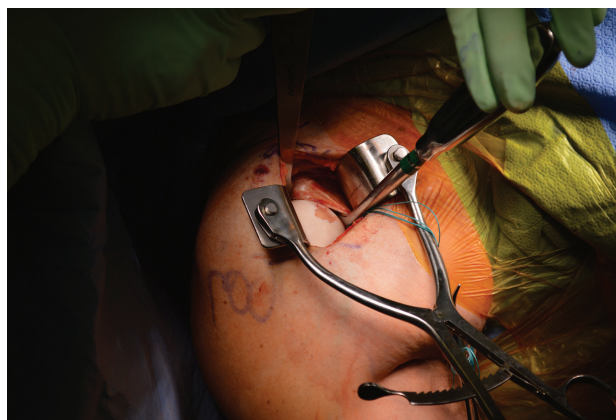

Figure 33.4 Conversion from arthroscopy to an open technique, with the previously identified articular cartilage defect exposed through a deltopectoral interval.

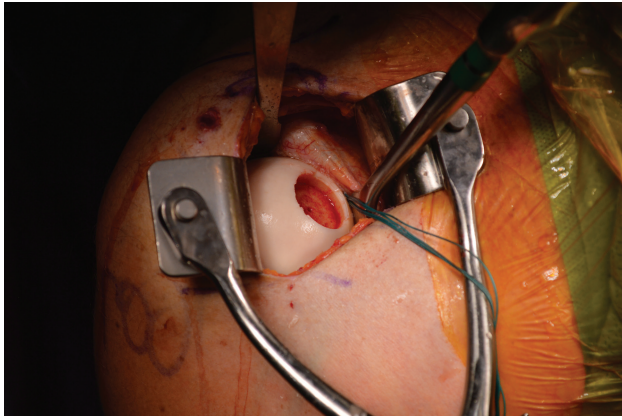


Figure 33.5 The articular cartilage lesion (recipient site) after preparatory drilling.

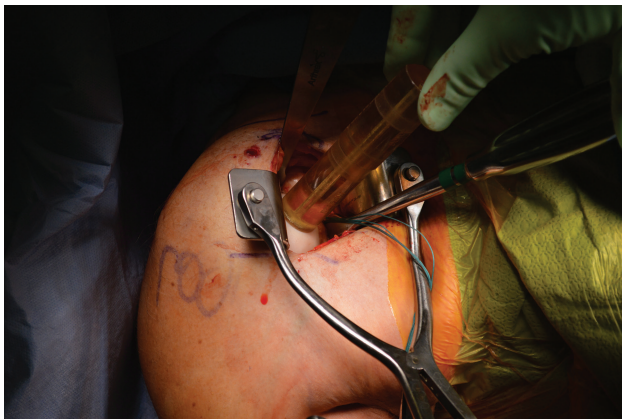

Figure 33.6 Using commercially available systems, the recipient site is sized in order to gauge the correct size of the donor allograft plug.



Figure 33.7 The donor osteochondral allograft plug fashioned from a fresh, frozen humeral head allograft.

of the lesion, and the donor site in the knee is usually the superolateral trochlea. As outlined above, the recipient site is prepared using a standard, commercially available drill that is sized to include the entire lesion, and care is taken to remain centered

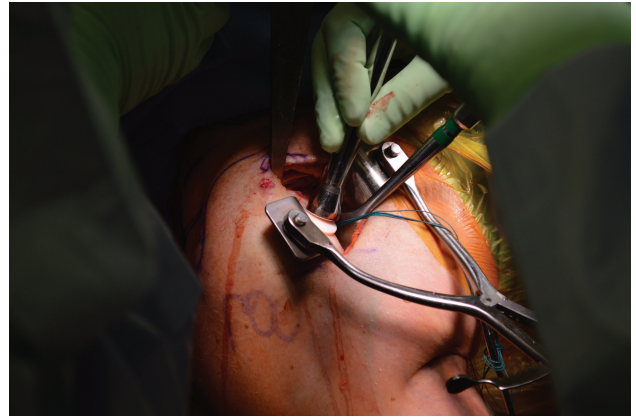


Figure 33.8 Using a commercially available system, the donor osteochondral allograft plug is tamped into place using the press-fit technique.

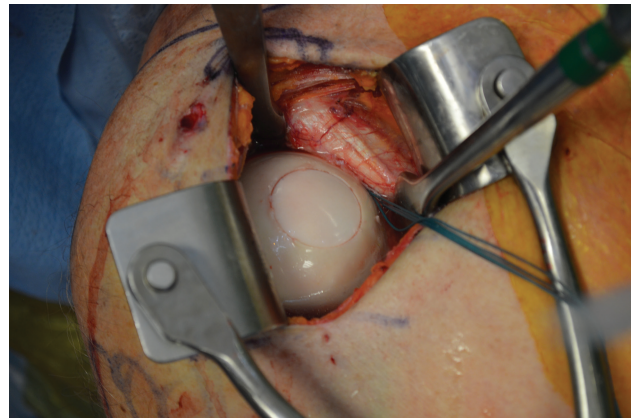


Figure 33.9 The final construct demonstrating an osteochondral allograft plug tamped in place and flush with the native humeral head cartilage.

and thoroughly irrigated while drilling the lesion. A tamp is used to implant the graft via a press-fit technique. The graft can also be fixed with headless screws, but we prefer the former press-fit technique whenever possible to minimize the potential for hardware complications.

POSTOPERATIVE MANAGEMENT

Following surgery, all patients are placed in a sling. They are discharged home on the same day with adequate analgesia. For arthroscopic procedures that do not involve subscapularis take down, early range of motion is encouraged as tolerated. For open grafting procedures that involve repair of a subscapularis take down, the repair is protected by limiting active and passive external rotation to 20° and limiting active internal rotation for 6 weeks. Patients can otherwise range their shoulder as tolerated. We do not use continuous passive motion, but this is an option for

patients following microfracture surgery, where motion is permitted without restriction. If needed, a formal physical therapy program is initiated at 6 weeks post-surgery, focusing on restoring range of motion, and later strengthening of the periscapular muscles and rotator cuff.

FOLLOW-UP TREATMENT

Following the procedure, patients are seen within the first or second week for a wound check and X-rays (for patients who underwent grafting). We then see patients back at 6 weeks, 3 months, 6 months, and 1 year post-surgery to ensure that adequate progress is being made. If there are any concerns, necessary changes are made to this algorithm. Imaging is only obtained if there is concern for graft resorption or non-union. We do not routinely image patients to assess for graft healing unless there is a specific concern.

TIPS, TRICKS, AND PITFALLS

As discussed in this chapter, the real challenge for the surgeon is not the identification of the lesion, but correlating the lesion identified on imaging to that patient's symptoms, and ensuring that the lesion in question is the certain cause of their complaints. Articular cartilage lesions are fairly common in advanced shoulder imaging, particularly in older patients; however, many of these lesions are asymptomatic. The surgeon should avoid the desire to treat asymptomatic lesions, as this can result in unnecessary complications or make an otherwise asymptomatic lesion symptomatic. It is not uncommon for us to leave articular cartilage lesions that are found incidentally during shoulder arthroscopy. Correlating patient complaints to the lesion in question will help the surgeon maximize the outcome of the procedures outlined in this chapter.

LITERATURE

Generally speaking, the literature pertaining to reparative (microfracture) and restorative (osteochondral allograft or autograft transplantation) techniques in the shoulder is limited. Much of our experience with these techniques stems from their use in the knee. We imagine that over the next few years our understanding of how these techniques fair in the shoulder in both the short- and long-term will evolve.

Microfracture

Although the literature is limited as to the efficacy of microfracture for articular cartilage lesions in the shoulder, the few studies that do exist have demonstrated a positive effect.²⁻⁵ Unfortunately, the literature has not defined

a lesion size that can guide surgeons as to which lesions are more amenable to microfracture; however, the smaller the lesion the more likely it is for a successful outcome.⁹ If drawing from the available literature, the surgeon should be aware that outcomes are superior for patients where the lesion size is $<2 \text{ cm}^2$, patient age <45 years, patient body mass index $<30 \text{ kg/m}^2$, and symptom duration >12 months.⁶ Q3

Osteochondral autograft transfer

The literature pertaining to osteochondral autograft transfer in the shoulder is largely limited to case reports,⁷⁻⁹ but one of the series is a long term follow-up of almost 9 years, demonstrating sustained benefit. Although Kircher et al. did demonstrate sustained clinical benefit, they did observe that all patients demonstrated progressive osteoarthritic changes on serial shoulder radiographs, which appeared to be the case irrespective of lesion size, number of grafts used, or any patient-reported outcome measure.⁹

Osteochondral allograft transfer

The literature pertaining to osteochondral allograft transplantation for articular cartilage lesion in the shoulder is quite sparse.⁷ A recent publication by our group demonstrated that at 2 years following the procedure, there was a sustained significant clinical benefit; furthermore, all but two grafts had incorporated.¹⁰ In this study, negative predictors of outcome included patients with bipolar disease and those with a history of using an intra-articular pain pump.¹⁰ Aside from this study, the remaining literature largely focuses on the use of osteochondral allografts for the treatment of large Hill-Sachs defects in the shoulder, not specifically focal articular cartilage defects.¹¹ Extrapolation of this data to the patients referred to in this chapter is difficult, given their history of recurrent instability and the more peripheral location of the Hill-Sachs defect as compared to central articular cartilage defects.

REFERENCES

1. Shin JJ, Mellano C, Cvetanovich GL, Frank RM, Cole BJ. Treatment of glenoid chondral defect using micronized allogeneic cartilage matrix implantation. *Arthrosc Techniq* 2014;3(4):e519-e522.
2. Slabaugh MA, Frank RM, Cole BJ. Resurfacing of isolated articular cartilage defects in the glenohumeral joint with microfracture: A surgical technique & case report. *Am J Orthop* 2010;39(7):326-332.
3. Frank RM, Van Thiel GS, Slabaugh MA, Romeo AA, Cole BJ, Verma NN. Clinical outcomes after microfracture of the glenohumeral joint. *Am J Sports Med* 2010;38(4):772-781.

4. Cole BJ, Yanke A, Provencher MT. Nonarthroplasty alternatives for the treatment of glenohumeral arthritis. *J Shoulder Elbow Surg* 2007;16(5):231S–240S.
5. Snow M, Funk L. Microfracture of chondral lesions of the glenohumeral joint. *Int J Shoulder Surg* 2008;2(4):72–76.
6. Siebold R, Lichtenberg S, Habermeyer P. Combination of microfracture and periosteal-flap for the treatment of focal full thickness articular cartilage lesions of the shoulder: A prospective study. *Knee Surg Sports Traumatol Arthrosc* 2003;11(3):183–189.
7. Chapovsky F, Kelly JD IV. Osteochondral allograft transplantation for treatment of glenohumeral instability. *Arthroscopy* 2005;21(8):1007.e1–e4.
8. Scheibel M, Barti C, Magosch P, Lichtenberg S, Habermeyer P. Osteochondral autologous transplantation for the treatment of full-thickness articular cartilage defects of the shoulder. *J Bone Jt Surg Br* 2004;86(7):991–997.
9. Kircher J, Patzer T, Magosch P, Lichtenberg S, Habermeyer P. Osteochondral autologous transplantation for the treatment of full-thickness cartilage defects of the shoulder: results at nine years. *J Bone Jt Surg Br* 2009;91-B(4):499–503.
10. Riff AJ, Yanke AB, Shin JJ, Romeo AA, Cole BJ. Midterm results of osteochondral allograft transplantation to the humeral head. *J Shoulder Elbow Surg* 2017;26(7):e207–e215.
11. Saltzman BM, Riboh JC, Cole BJ, Yanke AB. Humeral head reconstruction with osteochondral allograft transplantation. *Arthroscopy* 2015;31(9):1827–1834.

