

ARTICULAR CARTILAGE INJURIES

**TAMARA K. PYLAWKA
RICHARD W. KANG
BRIAN J. COLE**

The articular cartilage of diarthrodial joints serves several important functions: joint lubrication, stress distribution to subchondral bone to minimize peak stress, and provision of a smooth low-friction surface. Repetitive and acute impact, as well as torsional joint loading can damage articular cartilage surfaces of the knee joint. Injury to articular cartilage can lead to pain, swelling, joint dysfunction, and possibly progressive joint degeneration. Nonsurgical treatment options include oral medications, simple bracing, and physical therapy. Surgical interventions range from simple arthroscopic debridement to complex tissue engineering, including autologous chondrocyte implantation. To determine the proper treatment option, each patient's age, intensity of symptoms, activity level, and lesion characteristics should be considered. The purpose of this chapter is to provide a comprehensive overview of the etiology, diagnosis, and management of articular cartilage lesions.

EPIDEMIOLOGY

Chondral lesions affect approximately 900,000 Americans each year, leading to more than 200,000 surgical procedures to treat high-grade lesions (grade III or IV), as described in the classification section of this chapter. Curl et

al. completed a retrospective review of 31,516 arthroscopies and identified chondral lesions in 63% of cases, of which 41% were grade III and 19% were grade IV. Hjelle et al. prospectively evaluated 1,000 knee arthroscopies and identified chondral or osteochondral lesions in 61% of the patients, with 55% classified as grade III and 5% as grade IV. Chondral or osteochondral lesions vary in size and can occur in isolation or exist as multiple lesions in a single joint. Articular cartilage damage of the knee joint most commonly occurs in the weight-bearing zone of the medial femoral condyle (58% of all cartilage lesions in the knee). Other commonly affected zones include the weight-bearing zones of the lateral femoral condyle and patellofemoral joint.

ORGANIZATION AND COMPOSITION

Articular cartilage consists of a large extracellular matrix (ECM) with highly specialized cells (chondrocytes) sparsely distributed throughout the tissue, composing approximately 10% of the total wet weight of the tissue (Fig. 30-1). Chondrocytes are responsible for the homeostasis of articular cartilage, including synthesis, secretion, and maintenance of the ECM. This homeostasis is partially regulated by chondrocyte metabolic activity that responds to various agents, including (but not limited to) cytokines, growth fac-

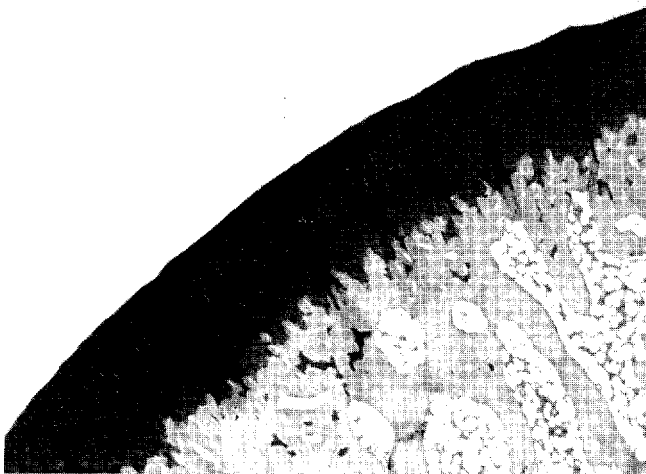


Figure 30-1 Photomicrograph demonstrating normal architecture of articular surface and the relationship to subchondral bone (safranin-O stain, X 4). (Courtesy of James Williams, PhD.)

torn, and hydrostatic and mechanical pressure changes. The principal components of the ECM include water (65% to 80% of total weight), proteoglycans (aggrecan, 4% to 7% of the total wet weight), and collagens (primarily type II, 10% to 20% of the total wet weight), with other proteins and glycoproteins in lesser amounts. Water content of articular cartilage is nonhomogeneously distributed, varying with the distance from the articular surface. Most water is contained in the molecular pore space of the ECM and concentrated at the surface and is partly responsible for joint lubrication. Water is able to move throughout the tissue by a pressure gradient or compression of the tissue. The majority of proteoglycans in cartilage are the large aggregating type (aggrecan) (Fig. 30-2). Proteoglycans are large, complex macromolecules and consist of a protein core with extensive polysaccharide (glycosaminoglycan) chains linked to this core. The role of proteoglycan is to bind water and enable cartilage to withstand large compressive loads. Collagens (mainly type II) are structural molecules distributed throughout cartilage, with fibril size and concentration vary-

ing throughout the tissue. Collagen provides cartilage the tensile strength needed to withstand shear forces. Articular cartilage is further subdivided into four distinct zones: superficial, transitional, deep, and calcified (Table 30-1, Fig. 30-3).

INJURY AND REPAIR

Acute articular cartilage injuries that lead to mechanical damage to cellular and matrix components can occur through blunt trauma, penetrating injury, friction abrasion, or abrupt changes of forces across the joint. Repair response depends on depth of penetration, volume of cartilage involved, and surface area involved. Articular cartilage lacks vascular, nervous, and lymphatic elements. It has a relatively low turnover rate, with only a limited ability to heal. Cartilage tends only to heal if the injury is minor; otherwise, for more extensive injury, restoration of the articular surface and functional capacity are dependent on surgical intervention. Injuries that do not penetrate the subchondral bone do not repair well, whereas injuries that extend into the depth of the subchondral bone initiate a vascular proliferative response through the release of mesenchymal cells of the bone marrow, leading to fibrocartilage repair tissue that consists primarily of type I collagen (Fig. 30-4). Although this method of repair may restore the articular surface, fibrocartilage is structurally and biomechanically inferior to native articular cartilage and thus is predisposed to future breakdown.

CLASSIFICATION

The mechanics and natural history of acute articular surface injuries are not well understood, but such injuries may result in isolated cartilage injuries known as a focal chondral defects, which are associated with varying grades of cartilage loss. Osteoarthritis is a progressive degenerative condition that shows a nonlinear increase in prevalence after the age of 50 years. Grossly, osteoarthritis appears as diffuse fraying, fibrillation and thinning of the articular cartilage. Chondromalacia describes the gross appearance of cartilage

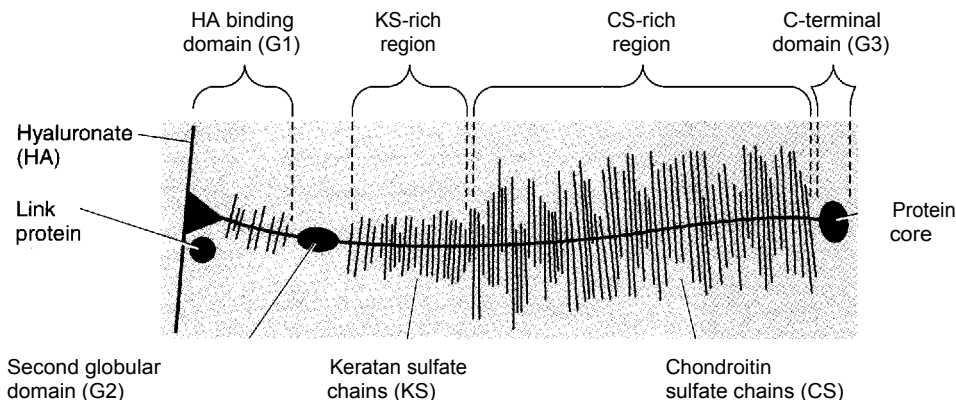


Figure 30-2 Schematic of PG aggregate molecule.

TABLE 30-1 ORGANIZATION OF ARTICULAR CARTILAGE

Zone	Chondrocyte	Collagen	Proteoglycan	Water	Properties
Superficial	Elongated in shape, horizontal to surface	Thin, parallel to surface, compact	Lowest concentration	Highest concentration	<ul style="list-style-type: none"> ■ Low fluid permeability ■ Provides resistance to shear forces ■ Secretes lubricating proteins ■ Thinnest zone
Transitional	Oblique shape, randomly distributed, sparse	Larger diameter, less organized	Highest	Lowest	<ul style="list-style-type: none"> ■ Less stiff than superficial zone ■ Distributes compressive loads to subchondral bone
Deep	Spherical shape, arranged in columns	Perpendicular to surface, extending into calcified zone			<ul style="list-style-type: none"> ■ Anchors cartilage to subchondral bone ■ Partially calcified
Tidemark calcified	<ul style="list-style-type: none"> ~ Separates deep zone (cartilage) from calcified zone (subchondral bone) ~ Small cells in cartilaginous matrix with apatitic salts ~ Collagen fibers from deep zone penetrate calcified cartilage 				

damage, including softening and fissuring to variable depths of cartilage involvement (Table 30-2). The extent of chondromalacia can be graded with arthroscopic evaluation using the Outerbridge classification scheme (Fig. 30-5). A more recent modification by the International Cartilage Repair Society classifies chondral injuries into five distinct grades (Table 30-3).

PATHOPHYSIOLOGY

Normal articular cartilage (2 to 4 mm thick) can withstand loads of up to five times body weight. Articular cartilage injuries can be separated into three types: partial thickness injuries, full thickness injuries, and osteochondral fractures.

Partial thickness articular cartilage injuries are defined by damage to the cells and matrix components limited to superficial articular involvement. This type of damage is most characterized by decreased proteoglycan (PG) concentration and increased hydration. These conditions are strongly correlated with a decrease in cartilage stiffness and an increase in hydraulic permeability leading to greater loads transmitted to the collagen-PG matrix, which increases ECM damage. Furthermore, breakdown of the ECM may lead to greater force transmitted to the underlying bone that eventually leads to bone remodeling. It has been postulated that chondrocytes can restore the matrix as long as enough viable cells exist to ensure that the rate of PG loss does not exceed the rate of synthesis and the collagen network remains intact.

Full thickness articular cartilage injuries are defined by

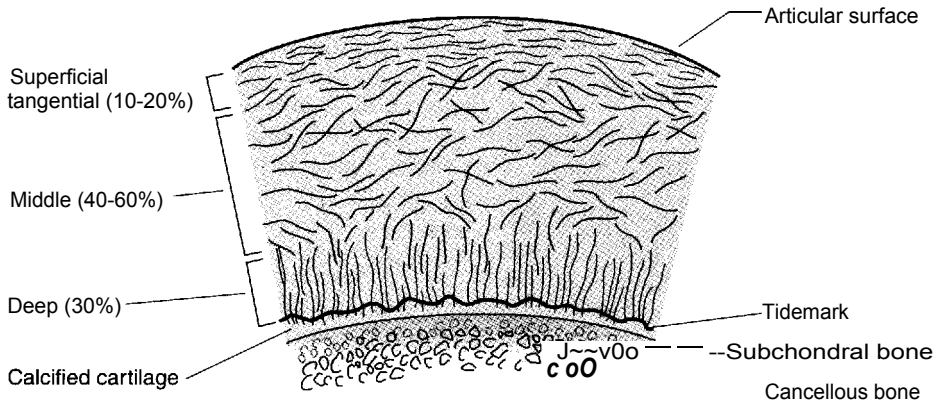


Figure 30-3 Schematic of zones of articular cartilage.

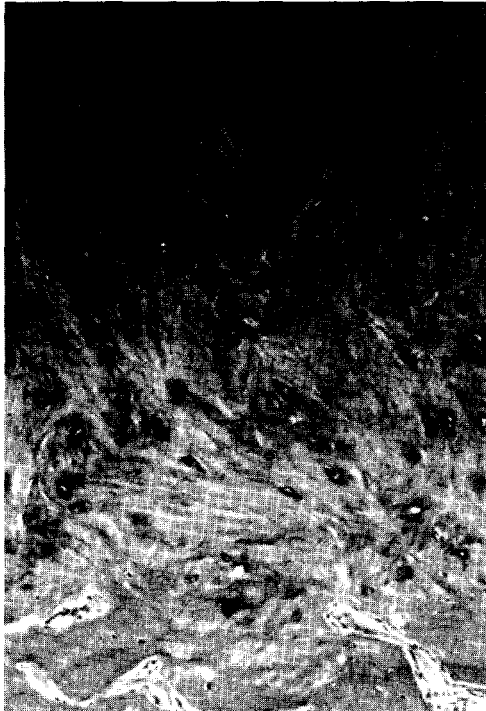
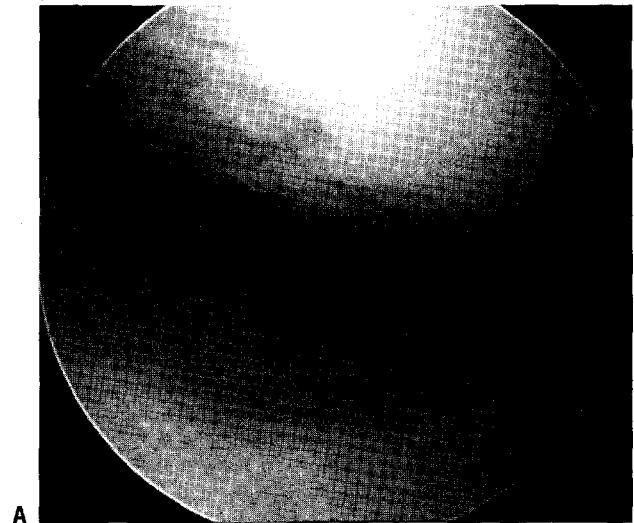


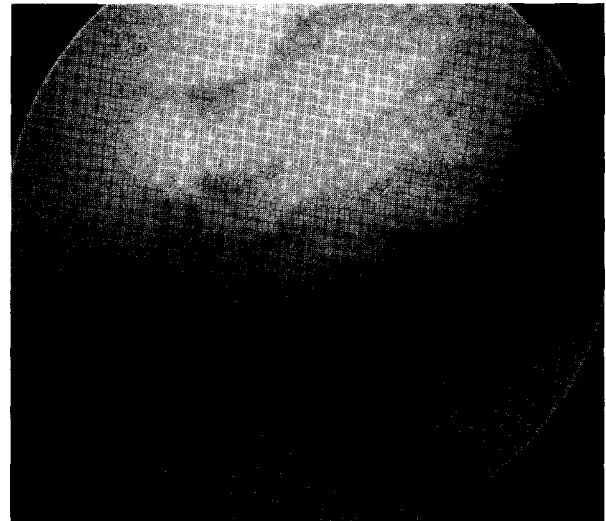
Figure 30-4 Photomicrograph of biopsy from fibrocartilage fill after marrow stimulation technique demonstrating a distinct lack of organizational structure and poor PG staining (hematoxylin and eosin, X 10).

visible mechanical disruption limited to articular cartilage. These injuries are characterized as (but not limited to) chondral fissures, flaps, fractures, and chondrocyte damage. Lack of vascular integration, and therefore lack of migration, of mesenchymal stem cells to the damaged area limits the repair of this type of injury. Mild repair occurs as chondrocytes start proliferating and synthesizing additional ECM; however, this response is short lived, and defects remain only partially healed. Thus, normal articular cartilage that is adjacent to the damaged site may undergo additional loading forces predisposing it to degeneration over time.

Osteochondral injuries are defined by a visible mechanical disruption of articular cartilage and subchondral bone. Such injuries occur when there is an acute assault on the



A



B

Figure 30-5 A: Arthroscopic photograph demonstrating an Outerbridge grade III lesion of the medial femoral condyle. B: Arthroscopic photograph demonstrating an Outerbridge grade IV lesion of the medial femoral condyle.

TABLE 30-2 OUTERBRIDGE CLASSIFICATION OF CHONDRAL INJURIES

Grade	Description
I	Softening and swelling of cartilage
II	Fissures and fragmentation in an area 1/2 inch or less in diameter
III	Fissuring and fragmentation in an area with more than 1/2-inch diameter involvement
IV	Erosion of cartilage down to subchondral bone

cartilage, leading to a fracture that penetrates deep into the subchondral bone. Subsequent hemorrhage and fibrin clot formation elicit an inflammatory reaction. The clot extends into the cartilage defect and releases vasoactive mediators and growth factors, such as transforming growth factor- β and platelet-derived growth factor, both implemented in the repair of such osteochondral defects. The resulting chondral repair tissue is a mixture of normal hyaline cartilage and fibrocartilage and is less stiff and more permeable than normal articular cartilage. Such repair tissue rarely persists and may show evidence of deterioration with depletion of PGs, increased hydration, fragmentation and fibrillation, and loss of chondrocyte-like cells. Alternatively, osteochondritis dissecans is a condition that may be developmental

TABLE 30-3 MODIFIED INTERNATIONAL CARTILAGE REPAIR SOCIETY CLASSIFICATION SYSTEM FOR CHONDRAL INJURY

Grade	Description
0	Normal cartilage
I	Superficial fissuring, softening
II	Less than 1/2 cartilage depth
III	Greater than 1/2 cartilage depth up to and not including subchondral plate
IV	Penetration through subchondral plate, exposing subchondral bone

in nature and may exist as a chronic osteochondral defect with no demonstrable evidence of a healing response (Fig. 30-6).

DIAGNOSIS

History and Physical Examination

- In general, the history, physical examination, plain radiographs, and surgical history can provide enough information to make the appropriate diagnosis.
- Cartilage injuries can occur in isolation or in association with concomitant pathology, such as varus or valgus mal-

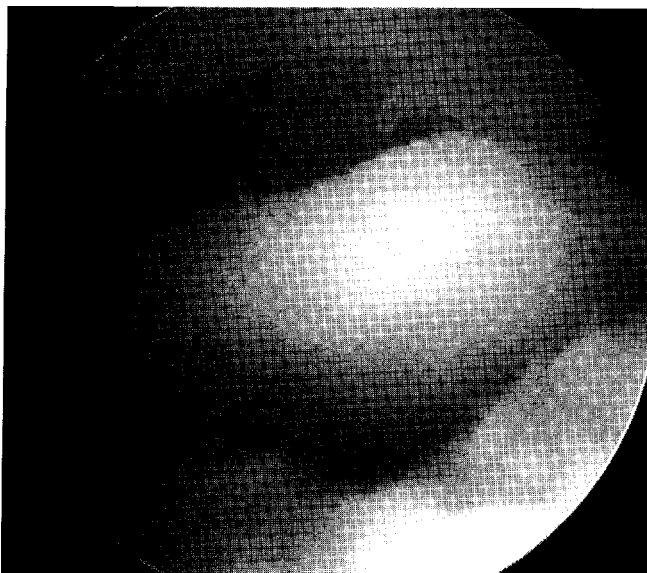


Figure 30-6 Arthroscopic photograph of a lesion of osteochondritis dissecans with a loose fragment remaining in situ.

alignment, patellofemoral malalignment, ligamentous instability, and meniscal deficiency.

Acute full-thickness chondral or osteochondral injuries commonly present with a loose body and/or mechanical symptom.

- i When chronic, symptoms may include localized pain, swelling, and a spectrum of mechanical symptoms (locking, catching, crepitus).
- An extensive history should be completed, including the onset of symptoms (insidious or traumatic), the mechanism of injury, previous injuries, previous surgical intervention, and symptom-provoking activities.
 - A comprehensive musculoskeletal examination should be performed to better assess for concurrent pathology that would alter the treatment plan.
 - w Range-of-motion testing is usually normal in patients with isolated focal chondral defects; however, adaptive gait patterns—such as in-toeing, out-toeing, or a flexed-knee gait—may develop as the patient compensates to shift weight away from the affected area.

Radiologic Examination

- Plain radiographs remain the most effective tool for initial evaluation of the joint.
 - Typical plain films include 45-degree flexion weight-bearing posteroanterior, patellofemoral, and non-weight-bearing lateral projections.
 - a These views allow assessment of joint space narrowing, subchondral sclerosis, osteophytes, and cysts.
- Other tools, such as magnetic resonance imaging, offer information concerning the articular surface, subchondral bone, knee ligaments, and menisci. However, magnetic resonance imaging generally tends to underestimate the degree of cartilage abnormalities seen at the time of arthroscopy.
- The role of the bone scan remains controversial because isolated articular surface defects that do not penetrate subchondral bone may not be identified.
- Despite advances in the aforementioned imaging techniques, arthroscopy still remains as the gold standard for diagnosis of articular cartilage injuries.

TREATMENT

Nonsurgical Treatment

- 1 Nonsurgical management includes oral medications, physical modalities (physical therapy, weight loss), bracing (knee sleeve and unloader brace), and injections (corticosteroids and hyaluronic acid derivatives).
- Such management is often ineffective in highly active and symptomatic patients and may only prove beneficial in low-demand patients, patients wishing to avoid or delay surgery, or patients with advanced degenerative osteoarthritis (a contraindication for articular cartilage restoration procedures).
 - Traditionally, treatment of articular cartilage lesions has included a combination of nonsteroidal anti-inflamma-

tory drugs, activity modification, and oral chondroprotective agents such as glucosamine or chondroitin sulfate.

Glucosamine stimulates chondrocyte and synovio-cyte activities, whereas chondroitin inhibits degradative enzymes and prevents fibrin thrombus formation in periarticular tissue. These substances improve pain, joint line tenderness, range of motion, and walking speed. No clinical data, however, show that these oral agents affect the mechanical properties or biochemical consistency of articular cartilage.

~ If nonsurgical management fails, a referral to an orthopaedic surgeon should be considered.

Indications that would suggest this type of referral are included in Box 30-1.

Surgical Treatment

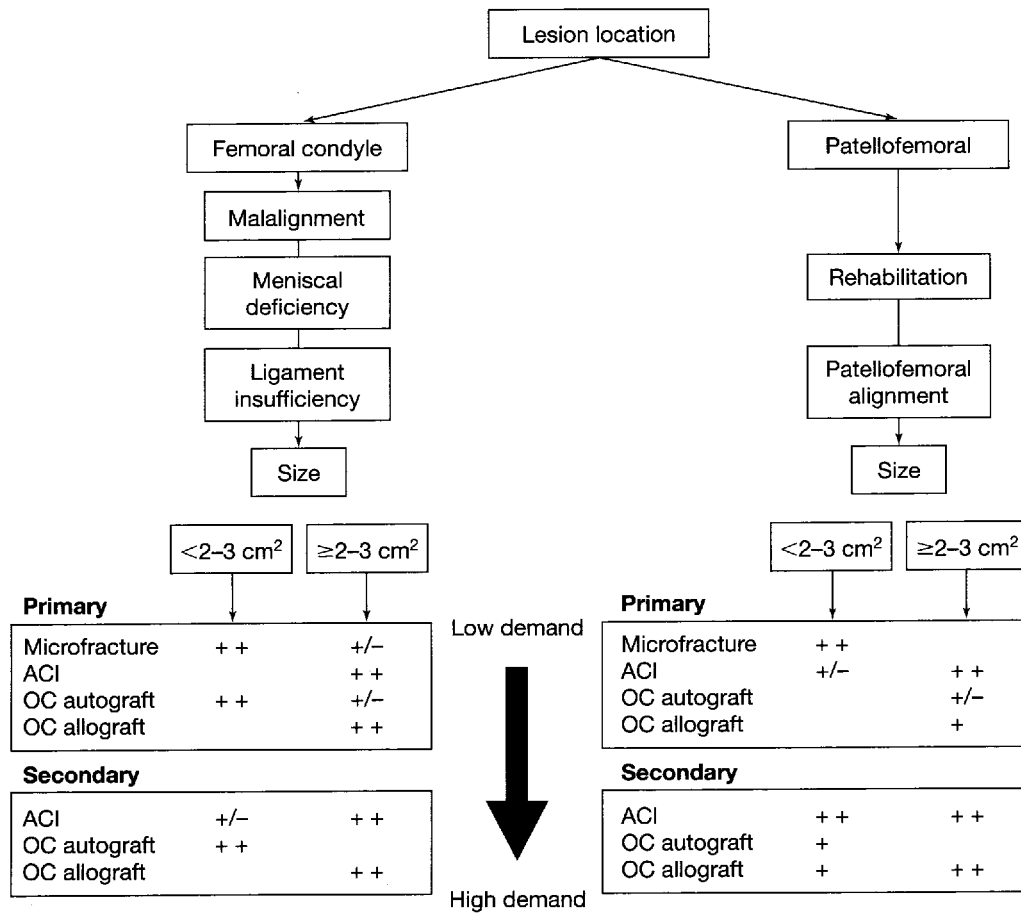
!! Treatment options to restore the articular cartilage surface involve consideration of many factors: defect size,

BOX 30-1 INDICATIONS FOR REFERRAL TO AN ORTHOPAEDIC SURGEON

- High-energy injury with direct trauma to the knee
- Acute motion loss
- Gross deformity of joint
- Acute neurovascular deficit
- Mechanical symptom (catching, locking, sensation of a loose body, crepitus)
- Failed nonsurgical management greater than 3 months in duration
- Repeated giving way or complaints of instability

depth, location, chronicity, response to previous treatment, concomitant pathology, patient age, physical demand level, and patient expectations.

■ Articular cartilage lesions of similar size may have many surgical options with no general consensus among orthopaedic surgeons.



Algorithm 30-1 The treatment of femoral condyle lesions is predicated first on correction of malalignment, meniscal deficiency, and ligament insufficiency. Treatment of patellofemoral lesions is predicated on exhaustive rehabilitative efforts followed by evaluation for malalignment. Defect size, patient physical demand level, and whether the treatment is primary or secondary determine the subsequent treatment option. OC, osteochondral; ACI, autologous chondrocyte implantation.

The treatment algorithm (Algorithm 30-1) should be regarded as an overview of surgical decision making and is dynamically evolving as longer-term data emerge about the indications and outcomes of cartilage repair procedures.

- Treatment of articular cartilage lesions and can be grouped into three categories: palliative, reparative, and restorative (Table 30-4).
- The goals of these procedures are to reduce symptoms, improve joint congruence by restoring the articular surface, and prevent further cartilage degeneration.
- Management of associated pathology such as malalignment, ligament insufficiency, or meniscal deficiency is mandatory for maximum relief of symptoms.

Palliative Treatment

- Palliative treatments include arthroscopic debridement and lavage, as well as thermal chondroplasty.
- Arthroscopic debridement and lavage is considered only as a palliative first-line treatment for articular damage and for treatment of the incidental or small cartilage defect (<2 cm²).

Simple irrigation to remove debris may temporarily improve symptoms in up to 70% of cases, and when combined with chondroplasty, the success rate may initially increase.

These techniques are used to remove degenerative debris, inflammatory cytokines (i.e., interleukin-1a), and proteases, all of which contribute to cartilage breakdown.

Postoperative rehabilitation involves weight-bearing as tolerated and strengthening exercises.

Table 30-5 provides a summary of outcomes data for arthroscopic debridement and lavage.

Limitations of debridement include the inability to definitively manage the chondral defect and the gen-

eral inability to contour, smooth, or stabilize the articular surface.

Thermal chondroplasty (laser, radio frequency energy) of superficial chondral defects allows more precise contouring of the articular surface.

Depth of chondrocyte death has been shown to extend deeper than the chondrocyte loss expected with mechanical shaving alone.

These concerns leave this procedure to be considered as investigational by many orthopaedic surgeons.

Reparative Treatment

- Reparative treatments involve surgical penetration of subchondral bone to allow for migration of marrow elements (including mesenchymal stem cells), resulting in surgically induced fibrin clot and subsequent fibrocartilage formation in the area of chondral defect.

- Several types of treatments use this technique, including microfracture, subchondral drilling, and abrasion arthroplasty.

These procedures are recommended in active patients and moderate symptoms with smaller lesions (<2 cm²) or in lower-demand patients with larger lesions (>2 cm²).

- Microfracture is the preferred marrow stimulation technique because it creates less thermal energy, compared with drilling, and provides a controlled depth of penetration with holes made perpendicular to the subchondral plate.

Defect preparation is critical and is performed by violating the calcified layer at the base of the lesion with a curette or shaver and creating vertical "shoulders" of normal surrounding cartilage.

Perforations are made close together (usually 3 to 4 mm apart), with care taken not to fracture the subchondral bone plate (Fig. 30-7).

TABLE 30-4 SURGICAL MANAGEMENT OF CHONDRAL LESIONS

Procedure	Ideal Indications	Outcome
Arthroscopic debridement and lavage	Minimal symptoms, short-term relief	Palliative
Thermal chondroplasty (laser, radio frequency energy)	Investigational, partial thickness defects Used in combination with debridement	Palliative
Marrow-stimulating techniques	Smaller lesions, persistent pain	Reparative
Autologous chondrocyte implantation	Small and large lesions with or without subchondral bone loss	Reparative or restorative
Osteochondral autograft/mosaicplasty	Smaller lesions, persistent pain	Restorative
Osteochondral allograft	Larger lesions with subchondral bone loss	Restorative

TABLE 30-5 RESULTS OF ARTHROSCOPIC DEBRIDEMENT AND LAVAGE

Study	Follow-up	Number of Patients	Results
Sprague (1981)	14 mo	78	74% good 26% fair/poor
Baumgaertner et al. (1990)	33 mo	49	52% good 48% fair/poor
Timoney et al. (1990)	4 yr	109	63% good 37% fair/poor
Hubbard (1996)	4.5 yr	76 knees	Debridement Lysholm score: 28 Lavage Lysholm score: 4
McGinley et al. (1999)	10 yr	77: all candidates for total knee replacement	Fostdebridement: 67% did not require total knee arthroplasty; 33% required total knee arthroplasty
Owens et al. (2002)	2 yr	20 bRFE 19 AD	Fulkerson score 12 mo: 80 AD, 87.9 bRFE 24 mo: 77.5 AD, 86.6 bRFE
Fond et al.(2002)	2 and 5 yr	36 patients	HSS score 2 yr: 88% good 5 yr: 69% good
Jackson et al. (2003)	4-6 yr	121 cases 71 advanced arthritic group Retrospective	87% of the advanced arthritic cases were improved

AD, arthroscopic debridement; bRFE, bipolar radio frequency energy; HSS, Hospital for Special Surgery.

For femoral condyle or tibial lesions, postoperative rehabilitation consists of protected weight-bearing for 6 to 8 weeks and may include continuous passive motion.

- 1 Table 30-6 summarizes the outcomes studies for microfracture.

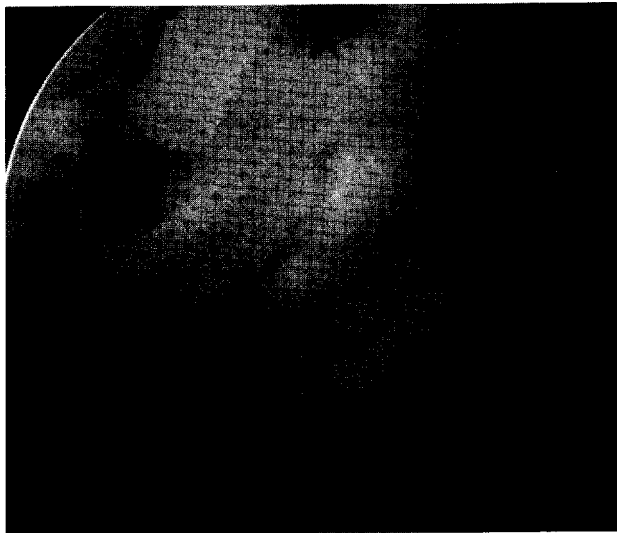


Figure 30-7 Arthroscopic photograph demonstrating microfracture technique performed for a grade IV lesion. The lesion was prepared by debriding the calcified cartilage. Next, microfracture awls were used to penetrate the subchondral bone.

Restorative Treatment

- Iv Restorative techniques involve tissue engineering (autologous chondrocyte implantation [ACI]) and osteochondral grafting.
- ~ ACI is a two-stage procedure involving a biopsy of normal articular cartilage (300 to 500 mg), usually obtained through an arthroscopic procedure, in which the cartilage is harvested from a minor load-bearing area (upper medial femoral condyle or intercondylar notch).
 - These chondrocytes are then cultured in vitro and implanted into the chondral defect beneath a periosteal patch during a second-stage procedure that requires an arthrotomy (Fig. 30-8).
 - This restorative procedure results in "hyaline-like" cartilage, which is believed to be biomechanically superior to fibrocartilage.
 - Postoperative rehabilitation entails continuous passive motion and protected weight bearing for up to 6 weeks.

TABLE 30-6 RESULTS OF MICROFRACTURE

Study	Follow-up	Number of Patients	Results
Blevins et al. (1998)	4 yr	140 recreational athletes	54 second-look arthroscopies yielded 35% with surface unchanged
Gill et al. (1998)	6 (2-12) yr	103 patients	86% return to sport 40 second-look arthroscopies yielded 50% normal
Steadman et al. (2003)	11.3 (7-17) yr	71 knees	80% improved Lysholm score 59 ---) 89 Tegner score 6 -* 9
Miller et al. (2004)	2.6 (2-5) yr	81 patients	Lysholm score 53.8 - 83 Tegner score 2.9 ---> 4.5

ACI is most often used as a secondary procedure for the treatment of medium-to-large focal chondral defects (>2 cm²).

Table 30-7 summarizes the outcomes studies for ACI.

Osteochondral grafts restore the articular surface by implanting a cylindrical plug of subchondral bone and articular cartilage.

The source of the tissue can be from the host (autograft) or from a cadaveric donor (allograft).

Several challenges face both autograft and allograft transplants: edge integration, restoring three-dimensional surface contour, and graft availability.

Osteochondral autografts are advantageous by virtue

of using the patient's own tissue, which eliminates immunological concerns.

This technique is limited by the size of the graft (<2 cm²) and involves obtaining the donor osteochondral graft from a non-weight-bearing area of the joint and placing it into the prepared defect site (Fig. 30-9).

The major risk involved with this technique is plug failure and donor site morbidity, which increases as the size of the harvested plug increases. Postoperative rehabilitation includes early range of motion and non-weight-bearing for 2 weeks with an increase to full weight-bearing from 2 to 6 weeks.

Indications for use of this technique include pri-

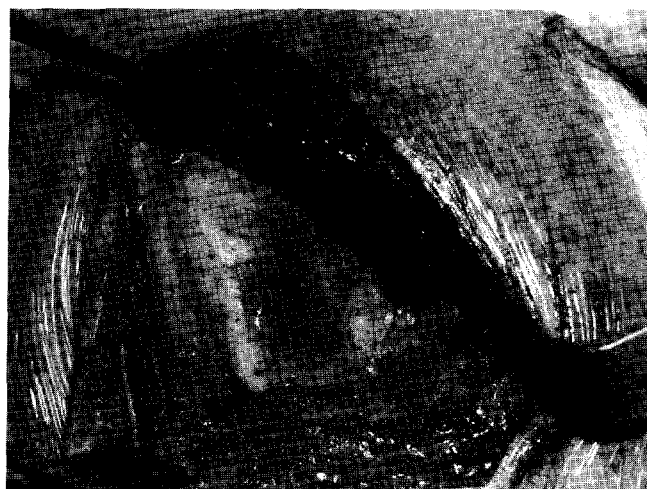
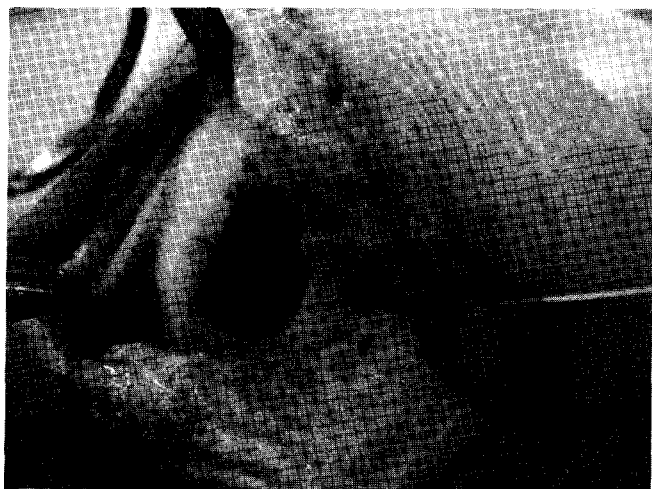
Figure 30-8 Intraoperative photographs demonstrating autologous chondrocyte implantation. Large lateral femoral condyle focal cartilage defect prepared (A) before suturing of the periosteal patch and sealing with fibrin glue (B).

TABLE 30-7 RESULTS OF AUTOLOGOUS CHONDROCYTE IMPLANTATION (ACI)

Study	Follow-up	Number of Patients	Results
Brittberg et al. (1994)	39 mo	23	6 excellent 8 good
Minas (2001)	1-2 yr	66	60% patient satisfaction
Peterson et al. (2002)	2-7 yr	61	89% good/excellent
Ochi et al. (2002)	3 yr	28 knees	93% good/excellent outcomes
Henderson et al. (2003)	3 and 12 mo	37	IKDC: 88% improvement at 12 mo MR score at 12 mo: 82% nearly normal cartilage Second-look biopsies: 70% hyaline-like material
Bentley et al. (2003)	19 mo	100	Modified Cincinnati and Stanmore: 88% good/excellent for ACI 69% good/excellent for mosaicplasty Arthroscopy (1 yr): 82% good/excellent repair for ACI 34% good/excellent for mosaicplasty
Yates (2003)	12 mo	24	78% good/excellent

IKDC, International Knee Documentation Committee; MR, magnetic resonance.

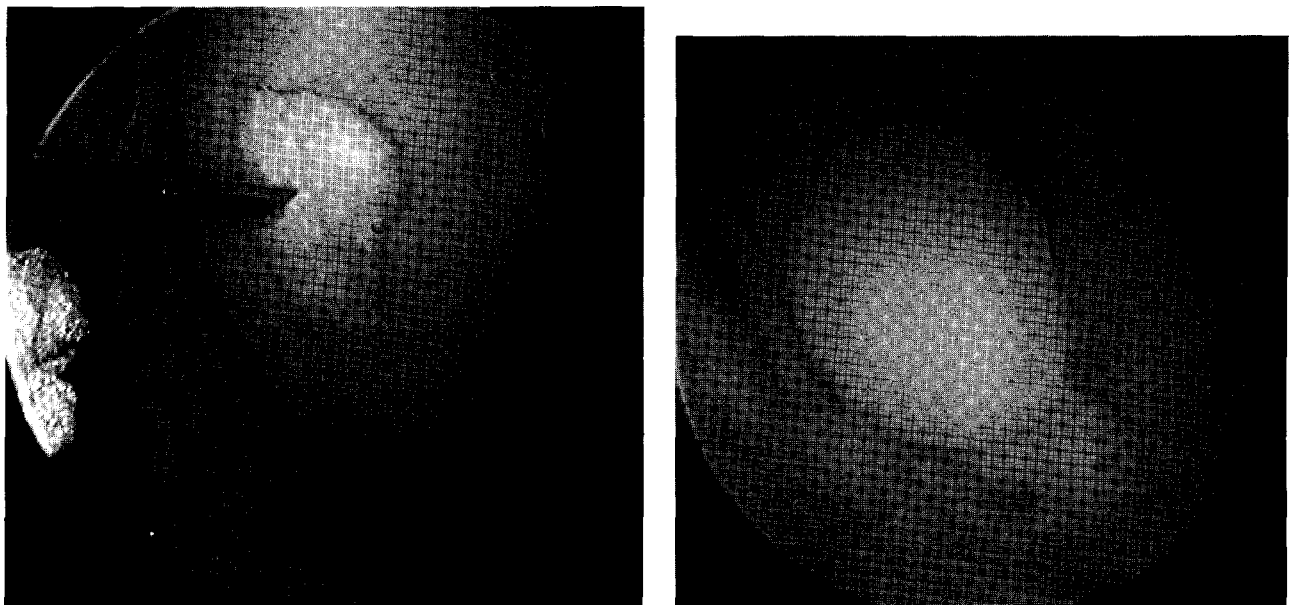


Figure 30-9 Arthroscopic photograph of a lesion treated previously with microfracture (A) being revised with a 10-mm diameter osteochondral autograft plug (B).

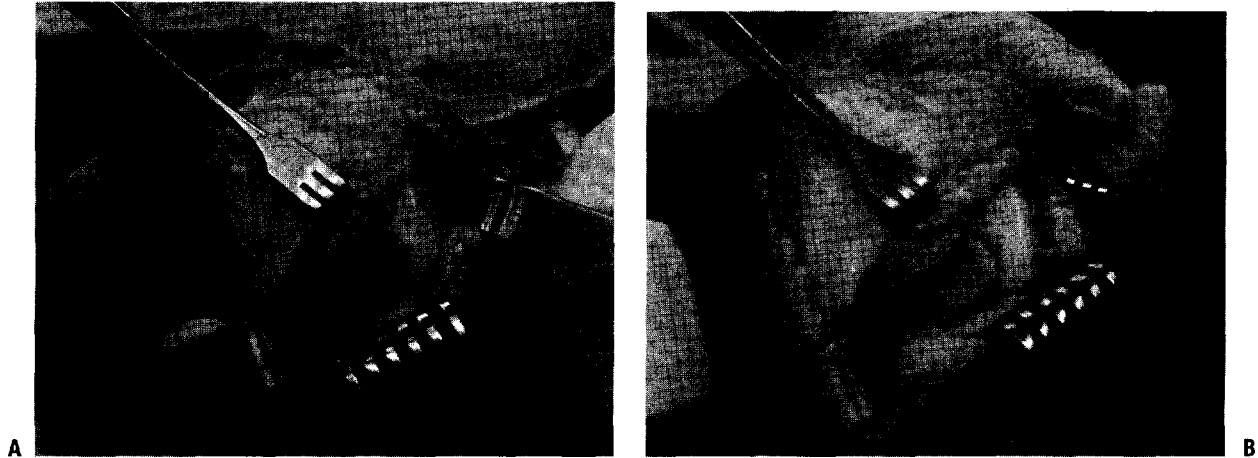


Figure 30-10 Intraoperative photograph of a defect (A) prepared to receive a fresh osteochondral allograft transplant measuring 20 mm in diameter (B).

many treatment of smaller lesions considered symptomatic and for similarly sized lesions for which a microfracture or possibly prior ACI procedure has failed.

Osteochondral allografts are used to treat larger defects (>2 cm²) that are difficult to treat with other methods.

Allografts involve the transplantation of mature, normal hyaline cartilage with intact native architecture and viable chondrocytes.

Because the graft includes subchondral bone, any disorder with associated bone loss (avascular necrosis, osteochondral fracture, and osteo-

chondritis dissecans) may also be restored (Fig. 30-10).

Major concerns such as tissue matching and immunologic suppression are unnecessary because the allograft tissue is avascular and alymphatic.

Graft preservation techniques include fresh, frozen, and prolonged cold preserved.

Fresh allografts must be used within 3 to 5 days of procurement. Thus, logistic concerns become an issue.

Frozen grafts can be stored and shipped on demand, potentially alleviating scheduling issues.

TABLE 30-8 RESULTS OF OSTEOCHONDRAL AUTOGRAFTS

Study	Number of Patients	Location	Mean Follow-up	Results
Hangody et al. (1998)	57	F, P	2 yr	91 % good/excellent
Kish et al. (1999)	52	F: competitive athletes	>1 yr	100% good/excellent 63% returned to full sports 31 % returned to sports at lower level 90% <30-year-old returned to full sports 23% >30-year-old returned to full sports
Bradley et al. (1999)	145	NA	1.5 yr	43% good/excellent 43% fair 12% poor
Hangody and Fules (2001)	461 93 24	F P, Tr T	>1 yr > 1 yr >1 yr	92% good/excellent 81 % good/excellent 80% good/excellent
Jakob et al. (2002)	52	Knee	2 yr	86% good/excellent
Hangody and Fules (2001)	831	F, T, P, Tr	10 yr	F = 92% good/excellent T = 87% good/excellent P, Tr = 79% good/excellent

F, femur; P, patella; Tr, trochlea; T, tibia.

TABLE 30-9 RESULTS OF OSTEOCHONDRAL ALLOGRAFTS

Study	Number of Patients	Mean Age (yr)	Location	Mean Follow-up	Results
Meyers (1984)	21	16-50	H	63 mo	80% success
Meyers et al. (1989)	39	38	F,T,P	3.6 yr	78% success 22% failure
Garret (1994)	17	20	F	3.5 yr	94% success
Gross (1997)	123	35	F,T,P	7.5 yr	85% success
Chu et al. (1999)	55	35	F,T,P	75 mo	76% good/excellent 16% failure
Bugbee (2000)	122	34	F	5 yr	91 % success rate at 5 yr 75% success rate at 10 yr 5% failure
Aubin et al. (2001)	60	27	F	10 yr	84% good/excellent 20% failure
Shasha et al. (2003)	65	NA	T	12 yr	Kaplan-Meier Survival Rate: 5 years-95% 10 years-80% 15 years-65% 20 years-46%

H, hip (femoral head); F, femur; Tr, trochlea; P, patella; T, tibia.

However, frozen osteochondral tissue lacks cellular viability.

The prolonged cold preservation method increases the "shelf-life" of the graft to at least 28 days and alleviates the scheduling difficulties while maintaining cell viability (78% at 28 days preservation); however, chondrocyte suppression remains an issue.

Incorporation and healing of allografts depend on creeping substitution of host bone to allograft bone.

Postoperative rehabilitation consists of immediate continuous passive motion and protected weight-bearing for 6 to 8 weeks.

This procedure is most often used as a secondary treatment option in patients who have failed previous attempts at cartilage repair.

Tables 30-8 and 30-9 summarize the outcomes studies for osteochondral autograft and allograft transplants.

SUGGESTED READING

- Brittberg M. Evaluation of cartilage injuries and cartilage repair. *Osteologie* 2000;9:17-25.
- Brittberg M, Lindahl A, Nilsson A, et al. Treatment of deep cartilage defects in the knee with autologous chondrocyte transplantation. *N Engl J Med* 1994;331:889-895.
- Buckwalter JA. Articular cartilage injuries. *Clin Orthop* 2002;402:21-37.
- Buckwalter JA, Hunziker EB, Rosenberg LC, et al. Articular cartilage: composition, structure, response to injury, and methods of facilitation repair. In: Ewing JW (ed), *Articular Cartilage and Knee Joint Function: Basic Science and Arthroscopy*. New York: Raven Press, 1990:19-56.
- Bugbee WD. Fresh osteochondral allografting. *Op Tech Sports Med* 2000;8:158-162.
- Caplan A, Elyaderani M, Mochizuki Y, et al. Overview of cartilage repair and regeneration: principles of cartilage repair and regeneration. *Clin Orthop* 1997;342:254-269.
- Chu CR, Convery FR, Akeson WH, et al. Articular cartilage transplantation. Clinical results in the knee. *Clin Orthop* 1999;360:159-168.
- Curl W, Krome J, Gordon E, et al. Cartilage injuries: a review of 31,516 knee arthroscopies. *Arthroscopy* 1997;13:456-460.
- Edwards RB, Lu Y, Markel MD. The basic science of thermally assisted chondroplasty. *Clin Sports Med* 2002;21:619-647.
- Hjelle K, Solheim E, Strand T, et al. Articular cartilage defects in 1,000 knee arthroscopies. *Arthroscopy* 2002;18:730-734.
- Kish G, Modis L, Hangody L. Osteochondral mosaicplasty for the treatment of focal chondral and osteochondral lesions of the knee and talus in the athlete. Rationale, indications, techniques and results. *Clin Sports Med* 1999;18:45-66.
- Mandelbaum BR, Romanelli DA, Knapp TP. Articular cartilage repair: assessment and classification. *Op Tech Sports Med* 8:90-97.
- Miller BS, Steadman JR, Briggs KK, et al. Patient satisfaction and outcome after microfracture of the degenerative knee. *J Knee Surg* 2004;17:13-17.
- Peterson L, Brittberg M, Kiviranta I, et al. Autologous chondrocyte transplantation: biomechanics and long-term durability. *Am J Sports Med* 2002;30:2-12.
- Poole A. What type of cartilage repair are we attempting to attain? *J Bone Joint Surg Am* 2003;85:40-44.
- Sprague NF. Arthroscopic debridement for degenerative knee joint disease. *Clin Orthop* 1981;160:118-123.
- Steadman JR, Rodkey WG, Rodrigo JJ. Microfracture: surgical technique and rehabilitation to treat chondral defects. *Clin Orthop* 2001;391:5362-S369.