

# Analysis of Interobserver and Intraobserver Variability in the Diagnosis and Treatment of SLAP Tears Using the Snyder Classification

Reuben Gobezie,<sup>\*†</sup> MD, David Zurakowski,<sup>‡</sup> PhD, Kyle Lavery,<sup>§</sup> Peter J. Millett,<sup>||</sup> MD, MSc, Brian J. Cole,<sup>||</sup> MD, MBA, and Jon J. P. Warner,<sup>§</sup> MD

From <sup>†</sup>The Case Shoulder & Elbow Service, Department of Orthopaedic Surgery, Case Western Reserve University School of Medicine, University Hospitals of Cleveland, Cleveland, Ohio, <sup>‡</sup>Department of Orthopaedic Surgery, Children's Hospital, Boston, Massachusetts, <sup>||</sup>Shoulder Service, The Steadman Hawkins Clinic, Vail, Colorado, <sup>||</sup>Rush University Medical Center, Chicago, Illinois, and <sup>§</sup>The Harvard Shoulder Service, Massachusetts General Hospital, Boston, Massachusetts

**Background:** Superior labral anterior posterior lesions are a relatively rare entity, and classification as a basis for selection of treatment has remained a point of controversy.

**Hypothesis:** There will be substantial interobserver and intraobserver variability in the diagnosis and treatment of superior labral anterior posterior tears by experienced arthroscopic specialists.

**Study Design:** Cohort study (diagnosis), Level of evidence, 2.

**Methods:** Compact discs containing 22 video vignettes of approximately 15 seconds duration were sent to the membership of the Arthroscopy Association of North America, American Shoulder and Elbow Society, and AOSSM. Each surgeon was asked to review the vignettes, classify the superior labral anterior posterior lesion type, and provide a treatment recommendation for each vignette. Seventy-three expert surgeons responded to the solicitation with a completed analysis. The same CD-ROM was re-sent to each of these 73 surgeons at a minimum of 12 months after the first viewing to obtain data on intraobserver reliability. Seventeen of the 73 surgeons returned this second CD-ROM with a complete analysis. Demographic data were also obtained from each surgeon. Multivariable logistic regression analysis was used to analyze the data, and 95% confidence intervals were established for each superior labral anterior posterior type (I-IV) with regard to diagnosis and treatment decision.

**Results:** The 22 vignettes analyzed by 73 surgeons resulted in 1606 responses. Several significant trends were noticed with regard to diagnosis and treatment from the responses: (1) surgeons had difficulty distinguishing type III lesions from type IV lesions, (2) the treatment of type III lesions is much more variable than that of any other subtype, and (3) surgeons had difficulty distinguishing normal shoulders from type II superior labral anterior posterior tears. No relationship was identified between correct treatment decisions based on diagnosis and any of the demographic factors analyzed. Our analysis of intraobserver variability showed only moderate agreement. The analysis of interobserver variability improved significantly when the diagnoses were analyzed based on treatment decision.

**Conclusions:** There is substantial interobserver and intraobserver variability among experienced shoulder arthroscopic specialists with regard to diagnosis and treatment of superior labral anterior posterior tears. Intraobserver agreement using the Snyder classification indicated only moderate agreement. Analysis of interobserver agreement based on treatment decisions results in superior concordance among experienced surgeons for the diagnosis of superior labral anterior posterior lesions.

**Keywords:** superior labral anterior posterior (SLAP) lesions; interobserver variability; intraobserver variability

\*Address correspondence to Reuben Gobezie, MD, The Case Shoulder & Elbow Service, Department of Orthopaedic Surgery, Case Western Reserve University School of Medicine, University Hospitals of Cleveland, 11100 Euclid Avenue, Cleveland, OH 44106.

Presented at the interim meeting of the AOSSM, San Diego, California, February 2007.

No conflict of interest declared.

The superior labral anterior posterior tear, or SLAP lesion, was first described by Andrews et al<sup>1</sup> in 1985. Snyder et al<sup>23</sup> classified these lesions in 1990, and their classification is widely recognized as a tenet of orthopaedic knowledge for orthopaedic surgeons worldwide. Moreover, the SLAP lesion is considered heavily in the decision-making process by many orthopaedic surgeons when formulating a treatment plan for patients with these conditions.<sup>23</sup>

The Snyder classification divides SLAP tears into 4 types.<sup>23</sup> Type I lesions represent degenerative fraying of

the superior labrum without compromise of the labral attachment to the glenoid or the biceps anchor. They are treated with debridement and are rarely considered a source of clinical symptoms.<sup>20,23</sup> Type II lesions are the most common lesions and have a biceps anchor that is detached from the superior glenoid tubercle. These lesions are treated with labral repair to the glenoid to reestablish biceps anchor stability.<sup>20,23</sup> Type III lesions consist of a bucket-handle tear of a meniscoid superior labrum with a normal biceps tendon attachment. The clinical symptoms are a result of the mobile labral fragment, and these are treated with arthroscopic debridement.<sup>6,20,23</sup> Type IV lesions also have a bucket-handle tear of the labrum, but the tear extends into the biceps tendon. The treatment of these lesions depends on the extent of biceps tearing, the stability of the superior labrum, and the age and activity level of the patient.<sup>6,20,23</sup> Generally, these lesions are treated with tenodesis/tenotomy with or without labral repair.

Several investigators have found that Snyder's classification does not permit accurate categorization of complex labral tears. Maffet et al<sup>16</sup> expanded Snyder's classification to include 3 additional types of SLAP lesions. Type V lesions consist of an anteroinferior Bankart lesion that is in continuity with a SLAP tear. Type VI lesions involve compromise of the biceps anchor combined with an unstable flap tear of the labrum. In type VII lesions, the biceps tendon–superior labrum separation extends anteriorly to involve the middle glenohumeral ligament. Morgan et al<sup>19</sup> further subclassified type II lesions into 3 distinct entities: anterior, posterior, and combined anterior–posterior lesions. The clinical importance of this distinction was that superior labral tears that extend posteriorly result in posterior superior glenohumeral instability that over time leads to rotator cuff tearing.<sup>19</sup>

The pathophysiology, biomechanics, and clinical outcomes for treatment of these lesions are active areas of research.<sup>4,9,10,21,22</sup> However, despite experience with these lesions over the last 16 years, accurate diagnosis remains difficult. Many studies evaluating the sensitivity, specificity, and positive and negative predictive values as well as interobserver and intraobserver reliability for various clinical exams and radiological imaging methods have been performed with varying success.<sup>†</sup> Current trends in diagnosis rely primarily on arthroscopic evaluation of the labral tears rather than imaging tools such as MRI, CT scans, or arthrography. However, given the relative rarity of these lesions and the complex classifications that have been developed,<sup>6,16,20</sup> it is not surprising that there is no consensus in classification and treatment decisions among surgeons. No study has evaluated the interobserver and intraobserver reliability of the diagnosis and treatment of these lesions. The purpose of this study was to assess interobserver and intraobserver variability among an experienced group of shoulder arthroscopy specialists for diagnosis and treatment of SLAP lesions using the Snyder classification.

## METHODS

Over the course of 1 year, cases were collected from the senior surgeons' (JJPW, BJC, PJM) practices that were

believed to illustrate a spectrum of superior labrum disease and normal anatomy. A total of 22 video vignettes each of approximately 15 seconds' duration were created. All video vignettes were made to show the anterior, superior, and posterior extent of the biceps origin as well as the course of the biceps. The superior labrum was probed as well. The view was with the scope in the posterior portal and the probe through an anterior portal. The arm was abducted in most cases to ensure that the superior shoulder was lax and a good view of the entire superior labrum was achieved. This was our best attempt to ensure uniform visualization in each case.

Two-hundred seventy-eight CD-ROMs were sent to the membership of the American Arthroscopy Association of North America (AANA), the AOSSM, and the American Shoulder and Elbow Society (ASES). Each of these societies has its own criteria for membership, and the general public assumes "expertise" to be a criterion for membership to the societies. Therefore, the selection of experienced arthroscopic specialists in this study was based on study participants' membership in any or all of these societies. The CD-ROM was accompanied by a letter that explained the purpose of this study and requested that the surgeon review each of the video vignettes to diagnose each vignette using Snyder's classification and provide a recommendation for treatment. Seventy-three surgeons (26%) responded to the solicitation with a completed analysis. The same CD-ROM was re-sent to each of these 73 surgeons at a minimum of 12 months after the first viewing to obtain data on intraobserver reliability. Seventeen (23%) of the 73 surgeons returned this second CD-ROM with a complete analysis. Participants included 6 surgeons from Europe and 67 surgeons from the United States. Demographic data obtained from each surgeon included the number of shoulder arthroscopic procedures performed per year, years in practice, residency arthroscopic procedure training, and fellowship subspecialty training (Table 1). Eighty-five percent of surgeons who responded were in practice for more than 2 years and 51% were in practice for at least 10 years. What was interesting, given their society memberships and their clinical volume of shoulder arthroscopic procedures, was that 64% of respondents were not fellowship-trained in arthroscopic procedures, and 64% said they had no significant exposure to arthroscopic procedures as a resident. Eighty-six percent of surgeons participating in the study perform at least 50 shoulder arthroscopic procedures per year. The baseline diagnosis for each vignette was based on the opinion of the treating surgeon and the method of treatment selected. We did not include vignettes containing any pathologic lesions other than SLAP tears and lesions of the long head of the biceps and its origin. Satisfactory treatment outcomes including the resolution of pain and return to premorbid activities in each of the 22 cases depicted in the CD-ROM allowed for verification of the baseline diagnosis. The treatment for each diagnosis was determined by the Snyder classification based on the description of the superior labrum and evaluation of stability by probing selected by the treating surgeon. The senior authors spent 1 year collecting candidate cases for each type of SLAP lesion from Snyder's classification (PJM, BC, JJPW). Each of the 3 senior authors

<sup>†</sup>References 2, 3, 5, 8, 11, 12, 15, 17, 18, 21, 24

TABLE 1  
Characteristics of the 73 Participating Surgeons

Characteristic	No. (%)
Years in practice	
<2	11 (15)
2-5	17 (23)
5-10	8 (11)
>10	37 (51)
Residency	
No	26 (36)
Yes	47 (64)
Fellowship in arthroscopic procedure	
No	23 (32)
Yes	50 (68)
Scope volume per year	
20-50	10 (14)
50-100	17 (23)
>100	46 (63)

contributed his own cases, and the most senior author (JJPW) agreed with the diagnosis and treatment from each submitted vignette and selected the best videos from more than 2000 vignettes to ensure adequate and standardized views of the superior labrum and biceps for the study.

Statistical Analysis

Analysis of the data was based on 22 video vignettes that were each evaluated by all 73 surgeons with respect to diagnosis using the Snyder classification and proposed

treatment. Interobserver and intraobserver agreement was determined using percentage concordance among surgeons as well as the  $\kappa$  coefficient as a chance-corrected measure of agreement with benchmarks of Landis and Koch<sup>14</sup> used to interpret  $\kappa$  values as follows: <0 poor, 0 to 0.20 slight, 0.21 to 0.40 fair, 0.41 to 0.60 moderate, 0.61 to 0.80 substantial, and 0.81 to 1.0 almost perfect agreement.<sup>7</sup> Intraobserver reliability was also assessed using the  $\kappa$  coefficient. Multivariable logistic regression analysis was used to identify characteristics of surgeons that were associated with making both a correct SLAP diagnosis and a correct treatment decision according to the gold standard, including years in practice, fellowship training in arthroscopic procedures, and surgical volume.<sup>8</sup> Two-tailed *P* values of < 0.05 were considered statistically significant. Statistical analysis was performed using the SPSS package version 15.0 (SPSS Inc, Chicago, Ill).

RESULTS

Normal Shoulders

Six (6/22) video vignettes were identified by 1 of the 3 senior authors as demonstrating a normal shoulder (Table 2). Sixty-eight percent of surgeons made the same diagnosis as the 3 senior authors. Seventy percent of the surgeons thought no treatment was indicated (Table 2). However, 20% of surgeons thought it was a type I SLAP lesion, and 19% indicated that debridement was necessary. Ten percent of surgeons viewing a normal shoulder indicated that repair of the

TABLE 2  
Surgeons' Diagnoses and Treatment Decisions (N = 73 Surgeons, 22 Cases)<sup>a</sup>

Type of Lesion	Diagnosis, %	Treatment Decision, %	Diagnosis and Treatment Both Correct, % (n)
Normal (6 cases)	<b>Normal: 68</b>	<b>No treatment: 70</b>	<b>66.7 (292/438)</b>
	SLAP I: 20	Debride: 19	
	SLAP II: 9	Repair labrum: 10	
	SLAP III: 2		
	SLAP IV: 1	Biceps tenodesis: 1	
SLAP I (2 cases)	Normal: 10	No treatment: 10	<b>60.3 (88/146)</b>
	<b>SLAP I: 64</b>	<b>Debride: 63</b>	
	SLAP II: 23	Repair labrum: 24	
	SLAP III: 1		
	SLAP IV: 1	Biceps tenodesis: 3	
SLAP II (9 cases)	Normal: 22	No treatment: 23	<b>51.9 (341/657)</b>
	SLAP I: 17	Debride: 17	
	<b>SLAP II: 58</b>	<b>Repair labrum: 54</b>	
	SLAP III: 1		
	SLAP IV: 2	Biceps tenodesis: 5	
SLAP III (3 cases)	Normal: 5	No treatment: 4	<b>23.3 (51/219)</b>
	SLAP I: 2	<b>Debride: 27</b>	
	SLAP II: 13	Repair labrum: 53	
	<b>SLAP III: 42</b>		
	SLAP IV: 38	Biceps tenodesis: 16	
SLAP IV (2 cases)	Normal: 0	No treatment: 0	<b>60.3 (88/146)</b>
	SLAP I: 1	Debride: 30	
	SLAP II: 4	<b>Repair labrum: 51</b>	
	SLAP III: 14		
	<b>SLAP IV: 81</b>	<b>Biceps tenodesis: 19</b>	

<sup>a</sup>Bold type indicates the "correct" answer for treatment in each category of SLAP tear.

labrum was the appropriate treatment. Improved performance with regard to the diagnosis and treatment of type I SLAP lesions was correlated with years in practice ( $P = .02$ ), increased exposure/cases in residency ( $P < .001$ ), fellowship training in arthroscopic procedures ( $P < .001$ ), and higher surgical volume ( $P < .05$ ).

### Type I SLAP Lesions

Two (2/22) video vignettes were type I SLAP lesions according to the impression of the 3 senior authors, and debridement was considered the correct treatment (Table 2). Sixty-four percent of surgeons agreed that both of these vignettes depicted a type I SLAP lesion, and 63% thought that debridement was the appropriate treatment. However, 23% thought that these 2 vignettes depicted a type II SLAP tear, and 24% thought that this lesion required labral repair. Sixty percent of surgeons indicated the correct diagnosis, in agreement with the senior authors, and treatment for this SLAP tear type (Table 2). No significant correlation between ability to reach the correct diagnosis and treatment and any of the demographic factors evaluated was found.

### Type II SLAP Tears

Nine (9/22) video vignettes were identified by the 3 senior authors to depict type II SLAP tears. Fifty-eight percent of surgeons agreed that a vignette showed a type II SLAP tear, and 54% recommended labral repair as the treatment. Twenty-two percent of surgeons thought that a vignette depicted a normal labrum, and 23% thought no treatment was necessary. Fifty-two percent of surgeons made the correct diagnosis and recommended the appropriate treatment, labral repair (Table 2). No statistically significant correlation between demographics evaluated and improved performance for making the correct diagnosis or treatment was identified.

### Type III SLAP Lesions

Three (3/22) video vignettes were identified by the 3 senior authors to depict type III SLAP tears. Forty-two percent of surgeons who responded agreed that these 3 vignettes depicted a type III SLAP lesion; however, only 27% recommended debridement (Table 2). Interestingly, 53% of surgeons recommended labral repair, whereas only 13% of surgeons classified these 3 lesions as type II lesions. Overall, 23% of surgeons made the correct diagnosis and recommended the appropriate treatment for this labral tear. No significant correlation between ability to reach the correct diagnosis and treatment and any of the demographic factors evaluated was found.

### Type IV SLAP Tears

Two (2/22) video vignettes were identified by the 3 senior authors to depict type IV SLAP tears. Eighty-one percent of surgeons agreed that the videos represented type IV

lesions, and 70% of surgeons indicated that they would either tenodesis the biceps (19%) or repair the labrum (51%) (Table 2). Because either tenodesis of the biceps or labral repair might be appropriate based on the clinical presentation of the patient according to the Snyder classification, the correct treatment for a type IV lesion was either labral repair or biceps tenodesis/tenotomy. Sixty percent of surgeons made the correct diagnosis and recommended the appropriate treatment for type IV SLAP tears. No statistically significant correlation between demographics evaluated and improved performance for making the correct diagnosis or treatment was identified.

### Intraobserver Reliability

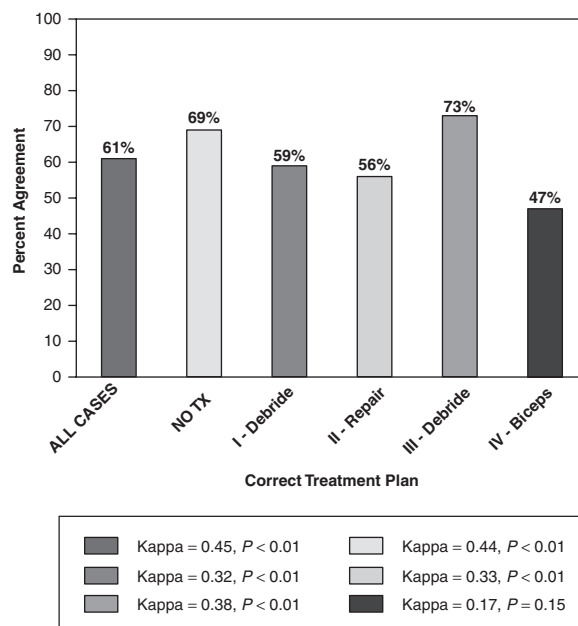
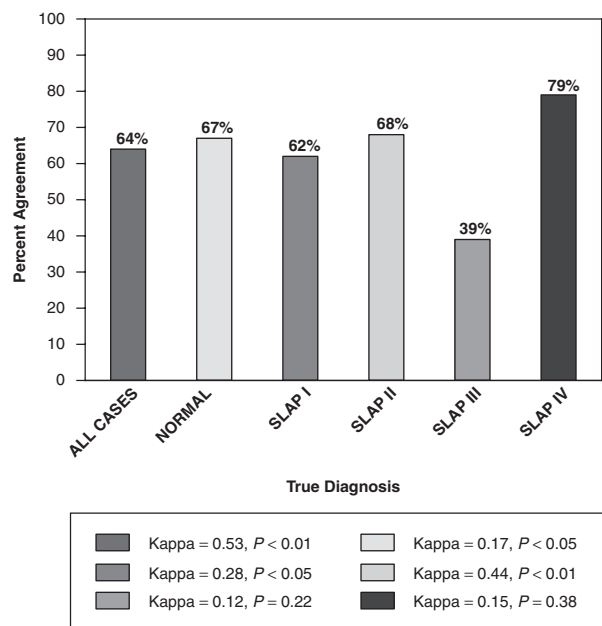
The intraobserver reliability for our surgeon respondents was analyzed for correct diagnosis and treatment independently (Table 2). The median intraobserver reproducibility  $\kappa$  coefficient for correct diagnosis using the Snyder classification was  $\kappa = 0.54$  ( $P < .01$ ), indicating moderate agreement. A breakdown of the intraobserver reproducibility  $\kappa$  coefficient for diagnosis according to type of SLAP lesion and normal is provided in Figure 1. Overall median intraobserver agreement for correct treatment recommendation was  $\kappa = 0.45$ , which also indicates moderate agreement. The  $\kappa$  coefficients for treatment of each type of SLAP lesion and normal shoulders are given in Figure 2. The 17 surgeons who responded provided 80% power to measure the true  $\kappa$  within 0.15, or within 15% of error.

### Interobserver Concordance and $\kappa$ Coefficient

If we define overall concordance as the percentage of surgeons who used the Snyder classification consistently given their proposed treatment plan, then we can calculate concordance and generate  $\kappa$  values for interobserver variability. For example, of the 1606 observations from all 73 surgeons, debridement only was chosen as the treatment plan 389 times. The concordant diagnoses in this situation would be either SLAP I (67.4%,  $n = 262$ ) or SLAP III (17.6%,  $n = 69$ ), which gives an overall concordance rate of 85%. This concordance was associated with a chance-corrected  $\kappa$  value of 0.75, which indicates moderate agreement and significantly above-chance level ( $P < .0001$ ). The levels of concordance are 94.4% for no treatment (ie, 94% of time when no treatment was indicated, surgeons diagnosed the lesion as normal), 85% for debridement, 70% for repair labrum, and 59% for repair labrum or biceps tenodesis. The  $\kappa$  values associated with these levels of concordance were 0.95 ( $P < .0001$ ) for no treatment, 0.75 ( $P < .0001$ ) for debridement of labrum, 0.68 for repair of labrum ( $P < .001$ ), and 0.32 ( $P < .05$ ) for repair of labrum and/or biceps tenodesis.

## DISCUSSION

Although diagnostic arthroscopic examination is considered the gold standard for assessment of SLAP lesions, to our knowledge our study is the first to evaluate the



**Figure 1.** Intraobserver reliability for diagnosis based on 17 surgeons' responses.

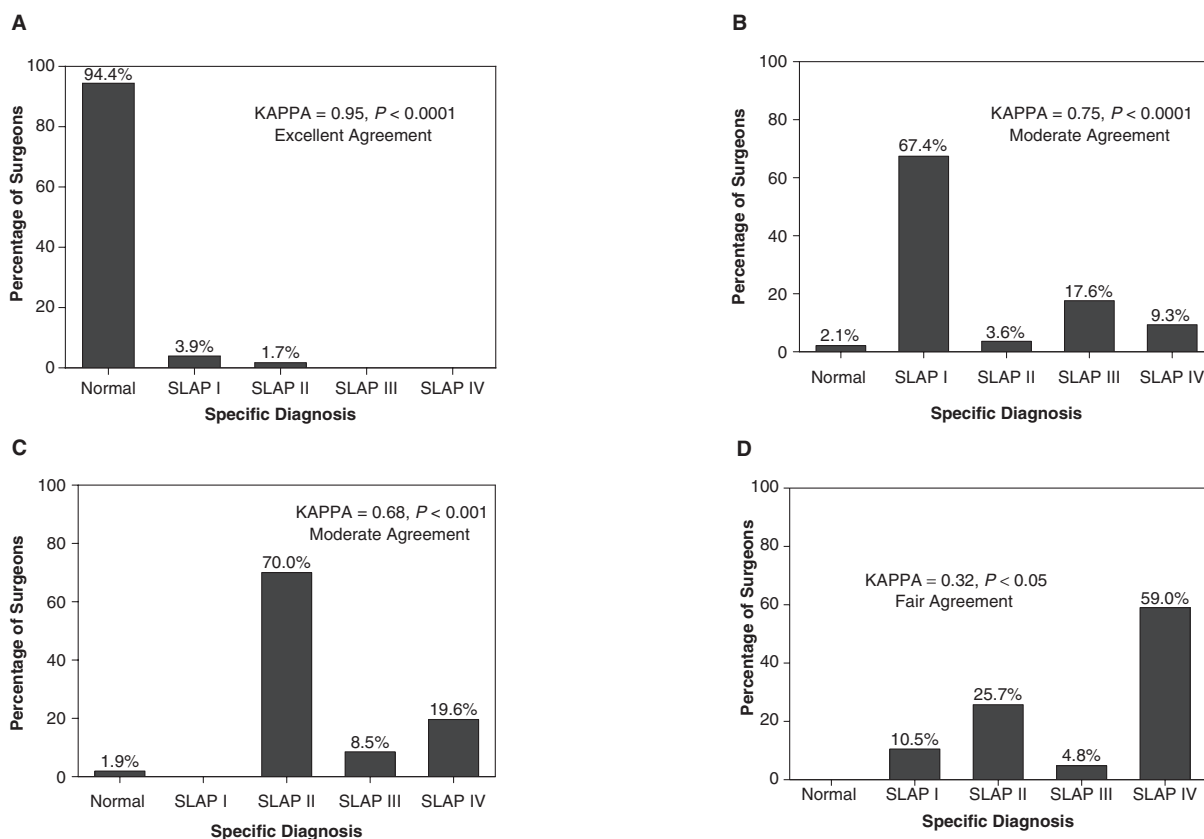
**Figure 2.** Intraobserver reliability for treatment based on 17 surgeons' responses.

interobserver and intraobserver variability among orthopaedic surgeons using the Snyder classification to make a diagnosis and determine a treatment for these tears. We found that interobserver variability among experienced arthroscopic specialists using the Snyder classification was considerable (Table 2), and the analysis of intraobserver variability showed only moderate agreement for both diagnosis and treatment ( $\kappa = 0.54$  and  $\kappa = 0.45$ , respectively) (Figures 1 and 2). When we analyzed the SLAP lesions by type according to the Snyder classification, the results showed that shoulder arthroscopic specialists had difficulty distinguishing normal shoulders from types I and II SLAP tears (Table 2). In addition, because only 52% and 23% of surgeons agreed on the diagnosis and treatment of types II and III lesions, respectively, we conclude that the Snyder classification is not helpful for guiding diagnosis and treatment for these lesions. Another possible explanation for this result with regard to type II and III SLAP tears is that there is no general consensus about the correct treatment of these lesions.

One of the most interesting results of our study was the analysis of interobserver variability when the surgeons' responses were evaluated based on their chosen treatment instead of what diagnosis was made using the Snyder classification. Our analysis revealed that surgeons agreed on the diagnosis when they were asked about how they would treat these lesions (Table 2). Both the concordance level and the magnitude of the  $\kappa$  coefficients observed in this study when treatment decision was used to assess the surgeons' ability to consistently use the Snyder classification to make a diagnosis are important. If experienced surgeons were asked whether to repair the labrum, their agreement on the diagnosis was 70%, because 440 of 629 responses indicated that the diagnosis was a type II SLAP tear and  $\kappa$  was 0.68 (Figure 3C). However, if the same surgeons were asked to make the diagnosis according to Snyder's SLAP

classification to guide their treatment, only 58% of surgeons made the correct diagnosis and 52% made the correct diagnosis and treatment (Table 2). The difference in agreement was even more dramatic for type I and III SLAP tears. The interobserver agreements using the Snyder classification for the diagnosis of type I and III SLAP tears were 64% and 42%, respectively (Table 2). In contrast, if all responses indicating that the treatment decision for the vignette was "debridement" were analyzed together, a concordance and  $\kappa$  of 0.75 indicating good or borderline excellent agreement for diagnosis was observed (Figure 3B). This analysis combines the type I and III lesions from the SLAP classification and simplifies the response options. Analyzing type IV lesions from the perspective of treatment decision with concordance, ironically, worsened the agreement among surgeons for the diagnosis of these lesions because 81% of the time surgeons agreed on the diagnosis using the SLAP classification for these tears (Figure 3D). If we accept either biceps tenodesis or labral repair as the correct answer, then 70% of surgeons agreed on the treatment of these labral tears, making the Snyder classification an effective tool for guiding diagnosis and therapy in type IV SLAP tears (Table 2). However, analyzing the responses from the perspective of treatment decision, in this case, biceps tenodesis or labral repair when the surgeon indicated there was biceps disease, results in 100% agreement on a treatment decision even if the diagnosis is agreed on 59% of the time, as a type IV, with a  $\kappa$  of 0.32 (Figure 3D).

The potential implications of these findings might significantly affect data from many previous studies designed to determine the sensitivity, specificity, and positive and negative predictive values of physical examination maneuvers and imaging studies where a single-surgeon diagnostic arthroscopic procedure was used as the gold standard.



**Figure 3.** A, surgeons who indicated “no treatment” after reviewing the 22 video vignettes with corresponding  $\kappa$  value for this response; B, surgeons who indicated “debridement” as the treatment of choice with corresponding  $\kappa$  value; C, surgeons who indicated “repair the labrum” with corresponding  $\kappa$  value; D, surgeons who indicated “repair and/or biceps tenodesis” with corresponding  $\kappa$  value.

However, the exact implication of our findings for these studies might require reanalysis. The rationale for this reanalysis is that our study included what the public likely perceives as “expert” surgeons based on membership in at least 1 of 3 professional societies, the AOSSM, the ASES, and the AANA. In this study, an evaluation of the number of years in practice, fellowship training, and, perhaps most important, the number of shoulder arthroscopic procedures performed per year reveals a heterogeneous portfolio of experience. Only 51% of surgeons surveyed were in practice for at least 10 years, and 15% had been in practice for less than 2 years. Fifteen percent of the surgeons in this study performed fewer than 50 arthroscopic procedures per year. Although the demographic factors evaluating surgeon experience using the criterion in this study did not significantly affect the outcomes in this study for the majority of labral tears, it is possible that had the survey responses from only the most experienced surgeons been studied, the results of this study might have demonstrated significant improvement in the interobserver and intraobserver reliability of the Snyder classification. This point might also be true in other studies evaluating interobserver variability among experienced arthroscopic specialists, as in an evaluation of rotator cuff tear classifications recently published by Kuhn et al,<sup>13</sup> where the criterion for expertise was performing at least 30 rotator cuff repairs per year—a relatively low volume for the most experienced

shoulder surgeons. However, the purpose of our study was to evaluate the interobserver and intraobserver variability among surgeons who treat SLAP lesions arthroscopically in the general public and are perceived as experts by the public based on their credentials including membership to specialty societies like the 3 included in this study.

There are several limitations of this study. First, 3 investigators determined the “correct” diagnosis for each vignette. However, we believe that this does not reduce the strength of our findings, because an analysis of the global data for responses (Table 2) demonstrates that no other potential combination of answers for any vignette would increase the interobserver variability attributable to the wide distribution of answers for each video. Second, it is possible that some of the videos were not of satisfactory quality. Third, it is possible that some of the lesions presented in the video vignettes were complex lesions and could not be classified accurately enough by some arthroscopic specialists using the 4 original types proposed by Snyder. However, it is statistically unlikely that the interobserver reliability observed in this study would improve by increasing the number of labral tear types available to each of the surgeons. Another weakness to this study is related to the overall response rate. Of the original 287 surgeons surveyed, the initial response rate was 73 and the secondary response rate was 17. However, only statistically significant findings were reported, and the study was sufficiently powered to draw these significant conclusions.

## CONCLUSIONS

This study demonstrates that there is significant interobserver variability among experienced shoulder arthroscopic specialists in diagnosing SLAP tears and determining their treatment using the Snyder classification. We have also demonstrated that intraobserver variability using this classification system shows only moderate agreement. Analysis of interobserver agreement based on treatment decision results in superior concordance among experienced surgeons for the diagnosis of SLAP lesions. Our data suggest that previous studies using diagnostic arthroscopic procedures by a single surgeon to define the gold standard might need to be scrutinized carefully and that reanalysis of variability with the Snyder classification should be performed among very experienced surgeons based on years in practice and surgical volume to ascertain whether this might significantly affect the performance of the Snyder classification in the diagnosis and treatment of SLAP tears. Further studies on SLAP lesions should include an assessment of interobserver variability when using a diagnostic arthroscopic procedure as the standard.

## REFERENCES

1. Andrews JR, Carson WG Jr, McLeod WD. Glenoid labrum tears related to the long head of the biceps. *Am J Sports Med.* 1985;13:337-341.
2. Bencardino JT, Beltran J, Rosenberg ZS, et al. Superior labrum anterior-posterior lesions: diagnosis with MR arthrography of the shoulder. *Radiology.* 2000;214:267-271.
3. Chan KK, Muldoon KA, Yeh L, et al. Superior labral anteroposterior lesions: MR arthrography with arm traction. *AJR Am J Roentgenol.* 1999;173:1117-1122.
4. Clavert P, Bonnomet F, Kempf JF, Boutemy P, Braun M, Kahn JL. Contribution to the study of the pathogenesis of type II superior labrum anterior-posterior lesions: a cadaveric model of a fall on the outstretched hand. *J Shoulder Elbow Surg.* 2004;13:45-50.
5. De Maeseneer M, Van Roy F, Lenchik L, et al. CT and MR arthrography of the normal and pathologic anterosuperior labrum and labral-bicipital complex. *Radiographics.* 2000;20(spec no):S67-S81.
6. Higgins LD, Warner JJ. Superior labral lesions: anatomy, pathology, and treatment. *Clin Orthop Relat Res.* 2001;390:73-82.
7. Hosmer DW, Lemeshow S. *Applied Logistic Regression.* 2nd ed. New York, NY: Wiley; 2000.
8. Hunter JC, Blatz DJ, Escobedo EM. SLAP lesions of the glenoid labrum: CT arthrographic and arthroscopic correlation. *Radiology.* 1992;184:513-518.
9. Ilahi OA. Anatomical variants in the anterosuperior aspect of the glenoid labrum. *J Bone Joint Surg Am.* 2004;86:432-433; author reply 433.
10. Ilahi OA, Labbe MR, Cosculluela P. Variants of the anterosuperior glenoid labrum and associated pathology. *Arthroscopy.* 2002;18:882-886.
11. Kim SH, Ha KI, Ahn JH, Kim SH, Choi HJ. Biceps load test II: a clinical test for SLAP lesions of the shoulder. *Arthroscopy.* 2001;17:160-164.
12. Kim SH, Ha KI, Han KY. Biceps load test: a clinical test for superior labrum anterior and posterior lesions in shoulders with recurrent anterior dislocations. *Am J Sports Med.* 1999;27:300-303.
13. Kuhn JE, Dunn WR, Ma B, et al. Interobserver agreement in the classification of rotator cuff tears. *Am J Sports Med.* 2007;35:437-441.
14. Landis JR, Koch GG. The measurement of observer agreement for categorical data. *Biometrics.* 1977;33:159-174.
15. Lee JH, Van Raalte V, Malian V. Diagnosis of SLAP lesions with Grashey-view arthrography. *Skeletal Radiol.* 2003;32:388-395.
16. Maffei MW, Gartsman GM, Moseley B. Superior labrum-biceps tendon complex lesions of the shoulder. *Am J Sports Med.* 1995;23:93-98.
17. Mimori K, Muneta T, Nakagawa T, Shinomiya K. A new pain provocation test for superior labral tears of the shoulder. *Am J Sports Med.* 1999;27:137-142.
18. Monu JU, Pope TL Jr, Chabon SJ, Vanarthos WJ. MR diagnosis of superior labral anterior posterior (SLAP) injuries of the glenoid labrum: value of routine imaging without intraarticular injection of contrast material. *AJR Am J Roentgenol.* 1994;163:1425-1429.
19. Morgan CD, Burkhart SS, Palmeri M, Gillespie M. Type II SLAP lesions: three subtypes and their relationships to superior instability and rotator cuff tears. *Arthroscopy.* 1998;14:553-565.
20. Nam EK, Snyder SJ. The diagnosis and treatment of superior labrum, anterior and posterior (SLAP) lesions. *Am J Sports Med.* 2003;31:798-810.
21. O'Brien SJ, Pagnani MJ, Fealy S, McGlynn SR, Wilson JB. The active compression test: a new and effective test for diagnosing labral tears and acromioclavicular joint abnormality. *Am J Sports Med.* 1998;26:610-613.
22. Pagnani MJ, Deng XH, Warren RF, Torzilli PA, Altcheck DW. Effect of lesions of the superior portion of the glenoid labrum on glenohumeral translation. *J Bone Joint Surg Am.* 1995;77:1003-1010.
23. Snyder SJ, Karzel RP, Del Pizzo W, Ferkel RD, Friedman MJ. SLAP lesions of the shoulder. *Arthroscopy.* 1990;6:274-279.
24. Tung GA, Entzian D, Green A, Brody JM. High-field and low-field MR imaging of superior glenoid labral tears and associated tendon injuries. *AJR Am J Roentgenol.* 2000;174:1107-1114.