

3

Meniscus Transplantation

GRANT H. GARCIA, DAVID R. CHRISTIAN, MICHAEL L. REDONDO, JOSEPH N. LIU, ADAM B. YANKE AND BRIAN J. COLE

CHAPTER OUTLINE

Introduction, 17

Preoperative Assessment and Complications, 17

Preoperative Imaging, Sizing, and Preservation Techniques, 18

Intraoperative (Slot) Technique and Potential Complications, 19

Complications Caused by Neglecting Concomitant Procedures, 19

Preventing Complications With Concomitant Procedures, 21

Anterior Cruciate Ligament Reconstruction and Meniscus Allograft Transplantation, 21

High Tibial Osteotomy and Meniscus Allograft Transplantation, 21

Postoperative Follow-Up and Complications, 22

Outcomes, 23

Conclusion, 24

Introduction

Initial treatment of most meniscus tears involves either excision or repair to prevent further propagation. The medial meniscus bears 40% of the tibiofemoral load, whereas the lateral meniscus bears 70% of the load.¹ With a better understanding of the meniscal deficient biological environment, surgeons have transitioned in some cases from removal to meniscal preservation.^{2,3} If preservation is not possible, it is now understood that transplantation of cadaveric meniscus may lead to prevention of early osteoarthritis changes.⁴ Most meniscal transplant patients require careful selection. In general, most of these patients are relatively young (<50 years) with an intact articular surface and moderate to severe pain postmeniscectomy.⁵ If there are anatomic alignment abnormalities or more extensive cartilage wear, further concomitant procedures may be needed.

Previously it was thought that chondral defects were a contraindication for meniscal transplantation; however, further data suggest it is not a significant risk factor for failure.⁶ Although concomitant meniscal transplant and cartilage restoration is a recent phenomenon, short-term outcomes are good. Rue et al.⁷ looked at patients who underwent combined meniscal transplantation and

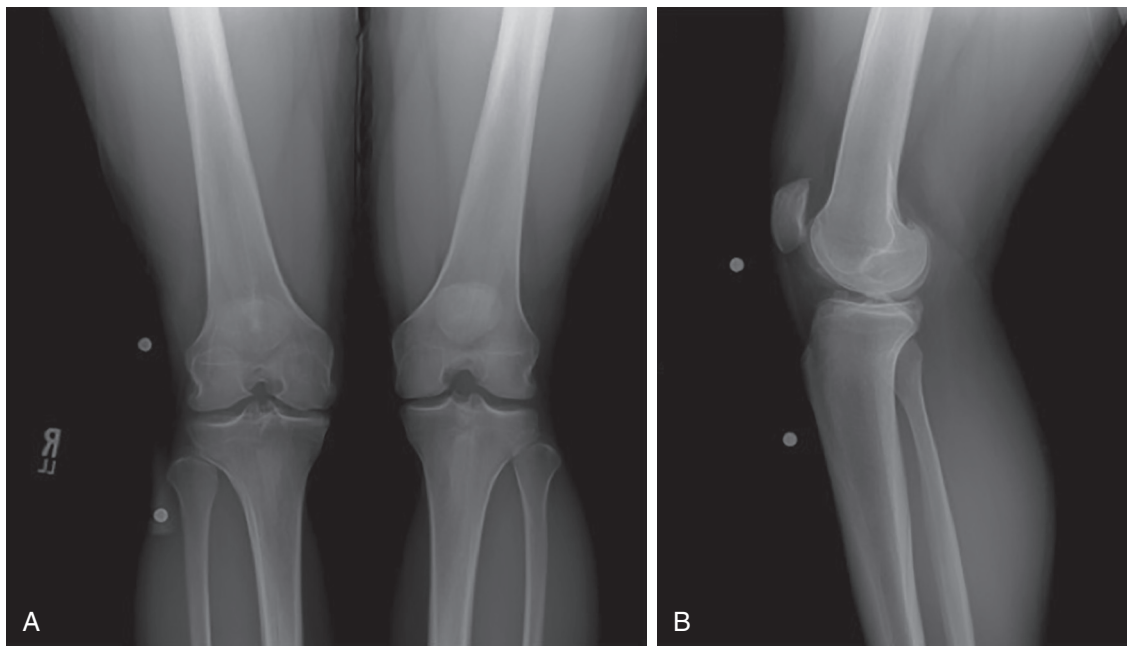
cartilage restoration and found that 71% were completely satisfied with their results. If careful selection is performed, combined procedures can offer excellent pain relief and improved function.^{8,9}

Complications generally arise from a number of factors including improper preoperative assessment, poor indications, missed concomitant pathology, inadequate graft preparation, improper surgical technique, and insufficient postoperative management. All these factors will be addressed in this chapter, as well as evidence-based outcomes and preventative measures to reduce complication risk and improve results of this high-demand and complex patient population.

Preoperative Assessment and Complications

A good preoperative assessment of patients in this population is essential because they may have other factors contributing to pain or dysfunction. A variety of features must be considered when evaluating a potential candidate for meniscal allograft transplantation (MAT).^{10,11} Obtaining a thorough history including previous injuries, comorbidities, and treatments is imperative. Furthermore, not all patients with meniscal deficiency are candidates for MAT, and a surgeon must understand appropriate indications. All previous operative notes, intraoperative photos, and imaging modalities must be reviewed in detail. Recent operative reports and arthroscopy images can be helpful to rule out diffuse arthritic changes. On examination, range of motion is usually preserved, joint effusion is present depending on recent physical activity, and occasionally palpation will reveal joint line or femoral condyle tenderness. Associated pathology, such as malalignment and ligamentous instability, should be noticed, because it would have to be addressed in a staged or concurrent fashion.

Complications can be prevented by evaluating correctable comorbidities (malalignment, ligament deficiency, uncorrected localized chondral damage in the involved compartment). Understanding general indications is essential, and these are outlined here:¹²



• **Fig. 3.1** (A) Posteroanterior and (B) lateral radiographs with 10-cm sizing marker used to calculate a patient's tibial dimensions for appropriate meniscus allograft sizing.

- 1) Patients younger than 50 years old with a chief complaint of pain limiting their desired activities
- 2) Body mass index less than 35 kg/m² and previous total meniscectomy with pain localized to the affected compartment
- 3) Normal or correctable coronal and sagittal alignment
- 4) Normal or correctable ligamentous stability
- 5) Normal or correctable articular cartilage
- 6) Willingness to comply with rehabilitation protocol

Full-thickness chondral defects have traditionally been considered a contraindication to meniscal transplantation.¹² Several recent reports have demonstrated results of concurrent meniscal transplantation and cartilage repair that are similar to isolated meniscal transplantation.¹³ As a result, we commonly perform concurrent cartilage transplantation with MAT. Failure to recognize these comorbidities or improper indications can lead to early graft failure, lack of pain reduction, and low patient satisfaction.¹² Finally, MAT performed as a prophylactic measure in the absence of appropriate symptoms is highly controversial and not advocated by the senior author.¹⁴ Following these criteria is a critical part of preventing postoperative complications, graft failure, and poor patient outcomes.

Preoperative Imaging, Sizing, and Preservation Techniques

Preoperative imaging and sizing is essential to prevent both intraoperative and postoperative complications. Routinely, we obtain weight-bearing anteroposterior (AP) and posteroanterior 45-degree flexion radiographs, nonweight-bearing 45-degree flexion lateral view, axial view of the patellofemoral joint, and a long-leg mechanical axis view to evaluate

malalignment. Magnetic resonance imaging (MRI) is helpful to assess the extent of previous meniscectomy, the degree of subchondral edema in the involved compartment, and the presence of other articular comorbidities, such as ligamentous or chondral injury. Bone marrow edema underlying the cartilage defect may indicate a source of pain, and the surgeon should take this into consideration when performing MAT. Correlating this imaging with previous arthroscopic images is crucial.

Sizing the meniscal allograft is one of the most important technical aspects of a successful surgery to prevent postoperative complications. Dienst et al.¹⁵ published a cadaveric biomechanical study evaluating the effects of sizing meniscal allografts on contact stresses in the lateral compartment. An oversized graft led to greater contact stresses on the articular surface, whereas undersized grafts led to near-normal contact stresses but increased stresses on the allograft itself. They concluded that a size mismatch of 10% or less was needed for the allograft to function properly.¹⁵ Additionally, width should be considered. Huang et al.¹⁶ evaluated the cross-sectional parameters of meniscal allografts compared with native menisci in cadaveric knees and found increased contact pressures when allografts did not match native menisci, with the greatest predictor of differences being the width of the menisci.

Currently, radiographic measurements, as described by Pollard et al.,¹⁷ are used to appropriately size the meniscus. As a consistent relationship exists between meniscal size and bony landmarks, most tissue banks currently size the meniscus with tibial plateau width and length measurements (Fig. 3.1).¹⁸ Sizing using MRI is reserved for cases that are not as well defined because MRI for graft size matching often underestimates meniscus length and width. We recommend

using radiographs for meniscal sizing to prevent some of these potential complications.

In addition to imaging, a diagnostic arthroscopy is useful to obtain a better understanding of the pathology in the patient's knee and aid in proper surgical planning.¹⁹ In all cases except when a recent (last 6 months) arthroscopy has been performed, we perform a diagnostic arthroscopy to assess the state of the femoral and tibial cartilage and confirm a majority of the meniscus is incompetent or missing.

Once sizing is complete, the appropriate preservation technique is selected based on the tissue bank. Meniscal allografts are ideally harvested within 24 hours after death and frozen. Although other graft preservation methods are used, fresh-frozen remains the most commonly used allograft preservation method.²⁰ Graft shrinkage has been reported, which can alter the accuracy of meniscal sizing and compromise the outcome, so careful evaluation of your tissue bank protocols are essential because specific techniques can vary between tissue banks. Cryopreservation was found to induce significant apoptotic cell death in meniscal tissue, with a reported cell viability of only 10–40%.¹⁹ Furthermore, the storage of the graft itself after harvest and before transplantation must be scrutinized because a high number of freeze-thaw cycles may be detrimental to graft function.²¹ Our ideal technique is a meniscus harvest within 24 hours after death and preservation using the fresh-frozen technique because in many cases this gives the best viability and allows for proper surgical planning.

Intraoperative (Slot) Technique and Potential Complications

Numerous complications can occur during the procedure, and an in-depth understanding of surgical anatomy is necessary. In addition, the type of complication that can arise is based on specific techniques and if concomitant procedures are used.

For a MAT slot technique, surgical landmarks include the patella, patellar tendon, tibial plateau, and fibular head. During the posterolateral approach or a lateral MAT, structures most at risk during the procedure include the peroneal nerve and lateral collateral ligament. For the posteromedial approach, the saphenous nerve is most at risk. Also, needle passage during the meniscocapsular repair can injure the posterior neurovascular bundle. One more devastating complication is tibial vein or arterial perforation. This can occur with preparation of the slot, and is most likely to occur with lateral MAT given the anatomy of the arteries and vein.¹²

The potentially worst and most preventable complications occur with preparation of the tibial slot. We initially start with slot preparation using electrocautery to center the anterior and posterior horn attachment sites with a line. This also prevents veering too close to the anterior cruciate ligament (ACL) insertion or too close to the main articulating portion of the plateau. Using this line as a guide, a 4-mm burr is used to create a superficial reference slot in the tibial plateau, making sure to follow the posterior slope of

the tibia. Slot dimensions should be confirmed by placing a hooked depth gauge in the reference slot, which also measures the AP length of the tibial plateau. Using a drill guide referencing off the hooked probe, a guide pin is drilled into the proximal tibia, just distal and parallel to the reference slot. The pin is advanced to, but not through, the posterior cortex, being mindful to avoid overpenetration, which could injure the posterior neurovascular bundle. If penetration is a concern, intraoperative fluoroscopy and/or a posterior lateral or posterior medial portal may be needed to visualize the pin and protect it from further penetration if this occurs. The pin is subsequently overreamed with an 8-mm cannulated drill bit, again taking care to maintain the posterior cortex and avoid capturing the pin with the drill and advancing ahead of the working end. A box cutter is then used to create an 8-mm -wide, 10-mm -deep slot which is smoothed and refined with a rasp to ensure that the bone bridge will slide smoothly into the slot (Fig. 3.2). In general, following this succinct set of steps prevents the frequent complications that can occur with tibial slot preparation.

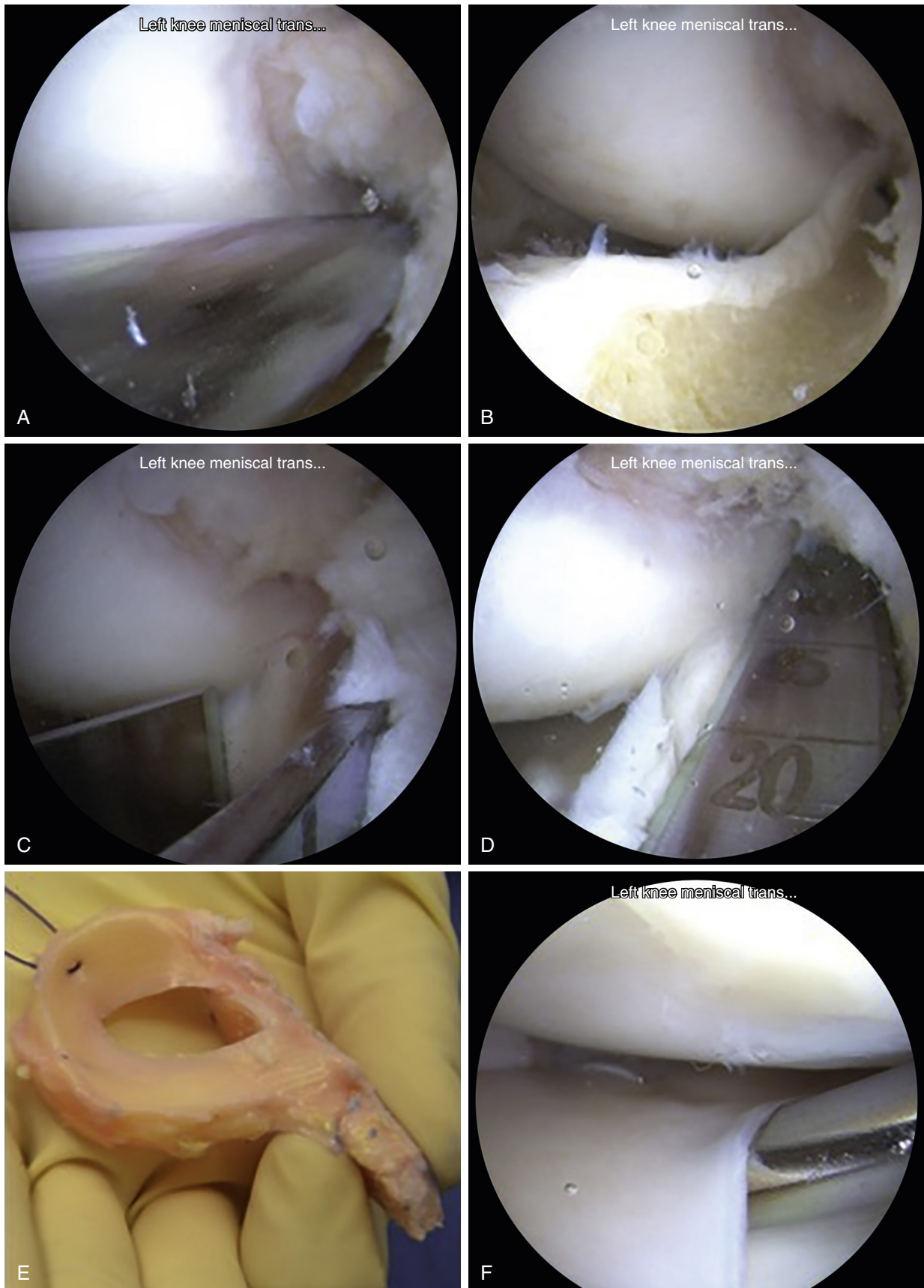
Meniscal root anatomy is also imperative to understand, not only in the setting of an isolated MAT, but also for combination procedures. For the lateral meniscus, a bone bridge technique is used for a MAT. In contrast, the medial meniscal roots are further apart from each other; thus medial MAT can be safely performed with either a bone bridge or bone plugs.¹²

There are other fixation techniques, and debate continues regarding the optimal procedure. Meniscal allografts can be secured by suture fixation or bony fixation (Fig. 3.2 E–F). Furthermore, bony fixation includes separate bone plugs on the anterior and posterior horns, or other variations such as keyhole, trough, dove-tail, and bridge-in-slot. In general, anatomic bony fixation is the gold standard for most surgeons, although several surgeons have reported excellent results with soft tissue-only MAT.

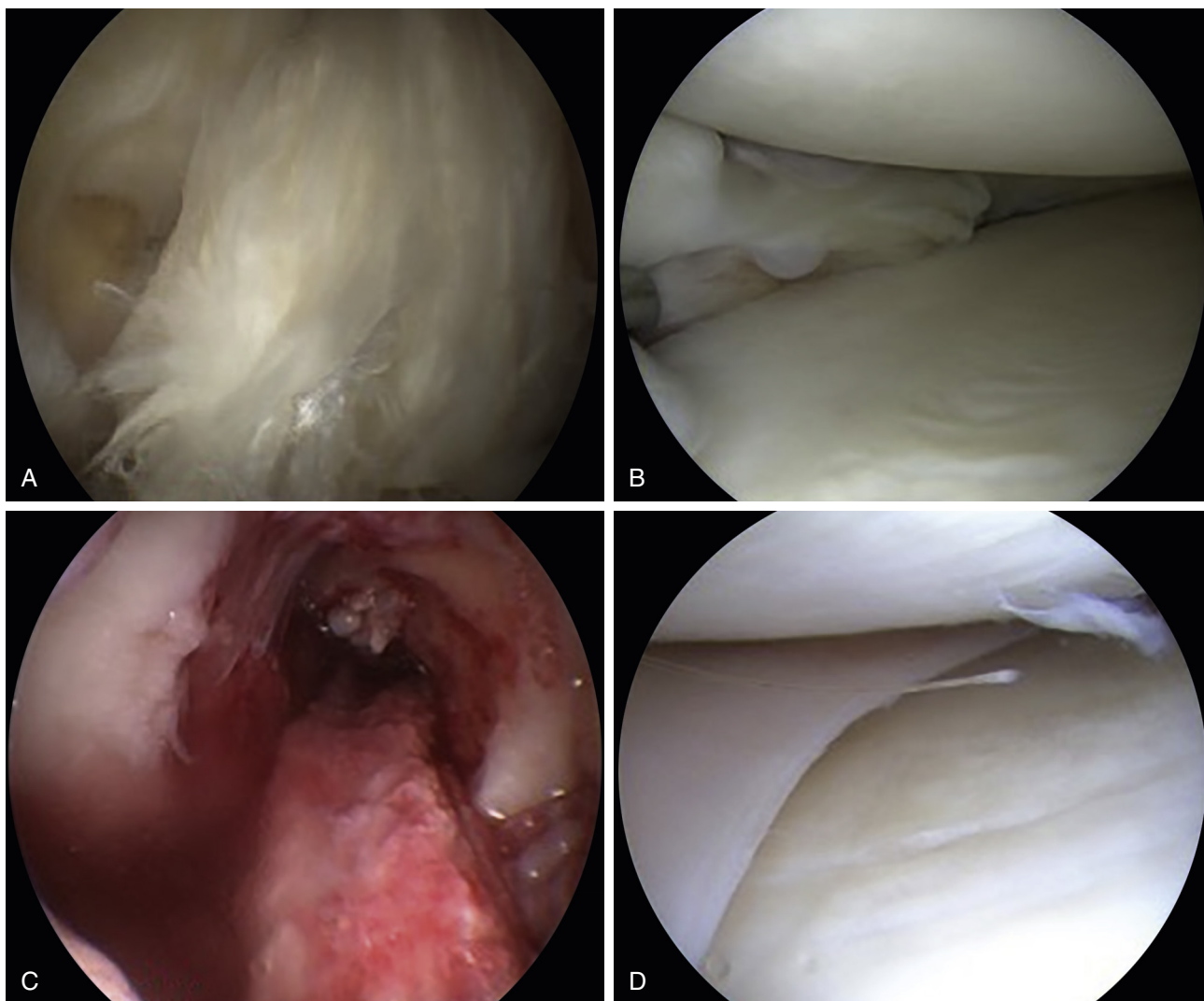
When performing a bridge-in-slot technique, bone bridge fracture is a potential complication. If this occurs, a small K-wire is used to reapproximate the bridge for insertion, or conversion to a bone plug technique is used. To prevent this from occurring, bone posterior to the posterior meniscal horn attachment is removed, but bone anterior to the anterior meniscal horn is kept intact to maintain graft integrity during graft passage.

Complications Caused by Neglecting Concomitant Procedures

As discussed earlier, a thorough preoperative evaluation of these potential patients is essential. Neglecting axial malalignment and concomitant intraarticular injuries can be detrimental to patient outcomes. Lee et al. found that axial malalignment can exert abnormal pressure on the newly placed graft, which can lead to loosening, overload, degeneration, and failure.^{22–24} Also, an osteotomy can independently reduce compartment loads, providing additional pain relief.



• **Fig. 3.2** Intraoperative images demonstrating the medial meniscus allograft transplant bridge-in-slot technique. (A) An arthroscopic burr is used to create a reference line for slot placement. (B) Once the guide pin is in place and the slot is reamed, (C) a box cutter is used to create the slot at the desired 8-mm width and 10-mm depth. (D) A rasp is then used to refine the slot to ensure the bone bridge will be easily placed. (E) The meniscus allograft is prepared on the back table with the meniscus roots attached to the bone bridge. A polydioxanone suture is placed in the posterior rim of the meniscus to aid graft insertion. (F) The meniscus is then sutured to the capsule to aid fixation.



• **Fig. 3.3** Intraoperative arthroscopic images demonstrating concomitant left knee (A) anterior cruciate ligament (ACL) rupture and (B) meniscal deficient medial compartment. Surgical treatment included a combined (C) ACL reconstruction and (D) medial meniscus allograft transplant.

The ACL-deficient patient needing MAT may benefit from concomitant ACL reconstruction (ACLR) because long-term follow-up after this procedure is good, as opposed to outcomes in patients with untreated knees.²⁵ Also, the posterior horn of the medial meniscus is an important secondary stabilizer to anterior translation and may prevent secondary stretch of the ACL-reconstructed knee.^{22,23} These are all potential complications that can be prevented if concomitant or staged procedures, as per the surgeon's comfort, are performed with a MAT.

Preventing Complications With Concomitant Procedures

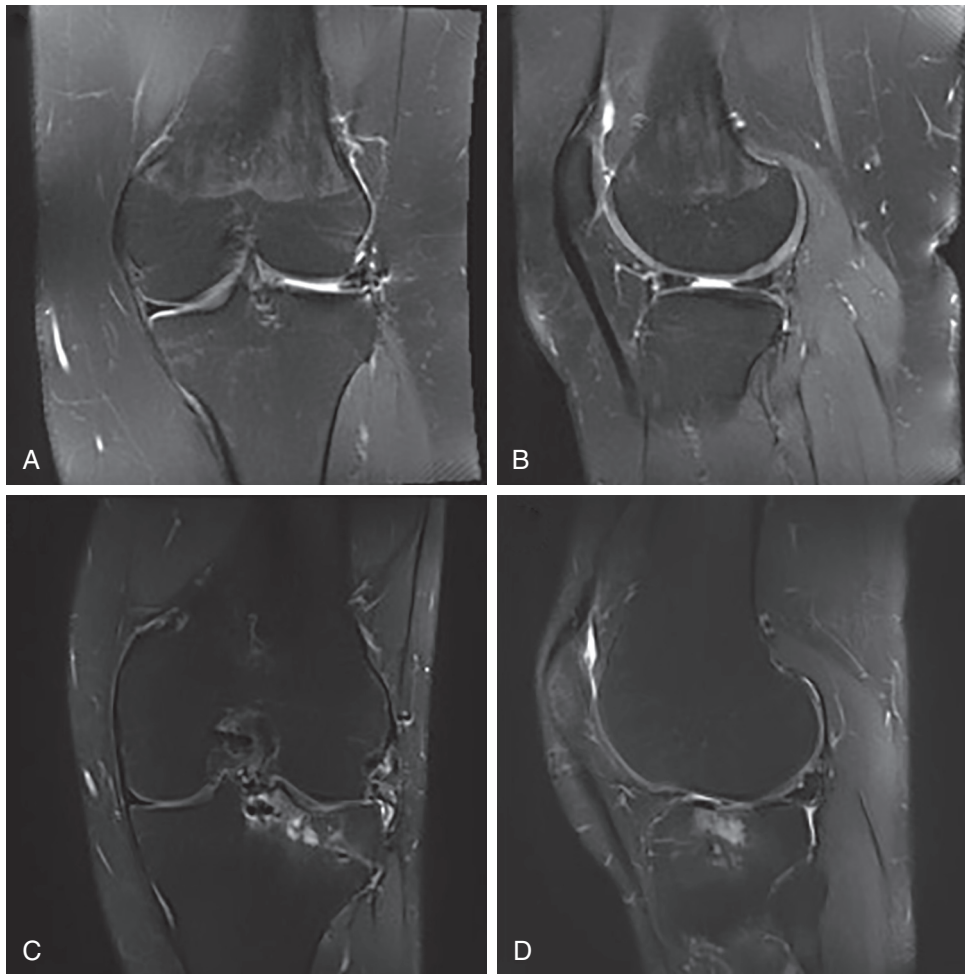
Anterior Cruciate Ligament Reconstruction and Meniscus Allograft Transplantation

When doing a combined procedure, we use a modification of the bridge-in-slot technique using two smaller bone blocks rather than one long bridge. The technique is similar to the

bone-plug technique described for medial meniscal transplantation.¹² Usually standard femoral and tibial tunnels are drilled and prepared before meniscal allograft insertion.²⁶ The use of allograft decreases associated donor-site morbidity, and tibial tunnel drilling requires special care because this tunnel often contacts the bone trough for the meniscus.²⁶ Again, you can also leave the ACL drill in when making the trough to protect from “tunnel convergence.” The key is to understand the bony anatomy and start with the ACL tibial tunnel. These have good results if done properly, with Wirth et al.²⁷ reporting excellent results in a series of 23 patients followed up with 14 years postprocedure (Fig. 3.3).

High Tibial Osteotomy and Meniscus Allograft Transplantation

The key here is to perform all aspects of meniscus transplantation first. The surgeon must perform his or her opening wedge osteotomy such that line of osteotomy passes at least 1.5 cm below the bottom of the tibial slot. Careful



• **Fig. 3.4** T2 weighted (A) coronal and (B) sagittal magnetic resonance imaging (MRI) scans demonstrating lateral meniscus allograft failure via graft tear in a 17-year-old female 4.5 years after meniscus transplant. T2 weighted (C) coronal and (D) sagittal MRI images demonstrating failure of lateral meniscus allograft transplant via graft extrusion, lateral meniscus allograft tear, and significant subchondral edema of the lateral tibial plateau in a 29-year-old male 7 months posttransplant.

wedging of the open osteotomy prevents the crack from propagating proximally into the meniscal slot, rather than laterally toward the fibular head. Verdonk et al.²⁸ found that the combination of medial MAT and high tibial osteotomy demonstrated better improvements in terms of pain, hospital for special surgery score, and knee injury and osteoarthritis outcome score (KOOS) score compared with isolated medial MAT. Also, Saltzman et al.²⁹ found that the combined high tibial osteotomy and MAT group had better Lysholm, KOOS pain, and KOOS quality of life scores.

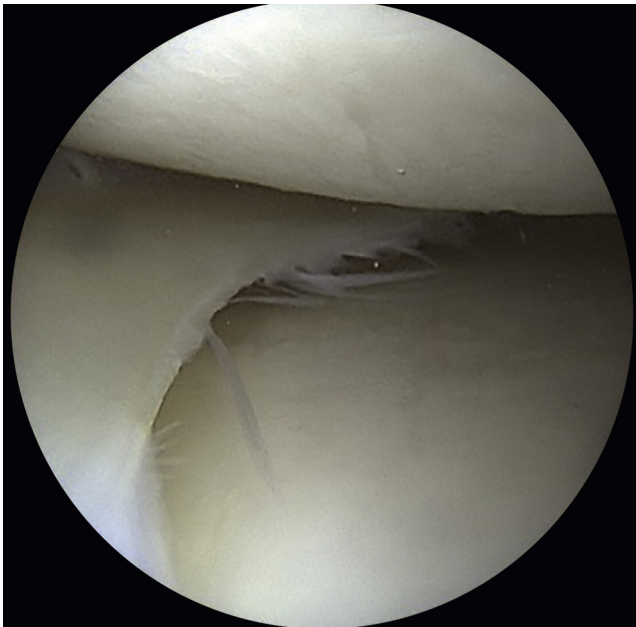
Postoperative Follow-Up and Complications

In general, meticulous preoperative evaluation, patient selection, and surgical technique are all aimed at preventing long-term complications and improving patient outcomes. Of all the problems discussed, postoperative complications are the most common.

Most complications following MAT are similar to those that can follow standard meniscus repair. These include infection, neurovascular damage, stiffness, failure of healing, hardware irritation, reoperation, and retear (Fig. 3.4AB). If the transplanted allograft is return, treatment is similar to that used for a native meniscus, and includes meniscectomy or repair, when indicated. In rare cases, revision MAT can be performed.³⁰

Of note, reoperation does not indicate failure because a majority of reoperations are for debridement, and patients experience excellent outcomes following post-MAT arthroscopic debridement (Fig. 3.5).¹² Arthrofibrosis is less common, with 4% of patients requiring manipulation under anesthesia at 12 years postoperatively.³¹ Additionally, the risk of graft complications appears greatest with irradiated or lyophilized grafts, grade III to IV osteoarthritic changes that are not transplanted, soft tissue fixation, and uncorrected malalignment or instability.¹²

One commonly discussed complication is graft shrinkage, which has been observed in many studies on



• **Fig. 3.5** Diagnostic arthroscopy 2.5 years after left medial meniscus allograft transplant in a patient experiencing mild pain and stiffness, demonstrating an intact graft well healed to the joint capsule.

second-look arthroscopy and follow-up MRI studies. Although common, it is of unknown clinical significance. Graft rupture or tear is also a significant risk in the short term. A meniscal tear of the allograft is one of the most common complications seen. They often occur at the capsular junction or the posterior horn, likely secondary to high contact stresses observed in the allograft, as well as from the suture material.²⁴ Tear rates as high as 36% at 5-year follow-up have been observed, although other studies have reported lower tear rates of 12% at 12-year follow-up.^{31,32}

Graft extrusion is a commonly discussed complication associated with MAT (Fig. 3.4 C–D). Meniscal extrusion is defined by displacement of the meniscus beyond the tibial plateau margins.³³ Although many define 3 mm as the threshold value for physiological meniscal extrusion in the native joint, it is unclear what amount is tolerated in meniscal transplant knees and for how long.³⁴ Meniscal extrusion is more commonly found after MAT than in normal knees, and has emerged as a potential complication of MAT, theoretically leading to worse clinical outcomes in the long term.³⁵ Lee and coworkers published the results of 43 meniscal transplants at a mean of 5.3 years postoperatively. All patients had an MRI 1 year postoperatively: 26 grafts were read as nonextruded, whereas 17 were extruded, although no difference in Lysholm scores was seen between the two groups.³⁶ Extrusion is seen as a potential complication of MAT; however, the correlation with various clinical, radiological, or arthroscopic outcomes is not entirely clear, and further research must aim at clarifying its significance.³⁷

Most studies view meniscal allograft extrusion as stable over time, with no clear evidence of related cartilage degeneration.^{38–41} Many studies also show that the degree of extrusion of MAT fixed with suture-only techniques or poor bone plug technique is greater than when bony fixation is used.^{42,43} Anatomic factors may also play a role in meniscal body extrusion, including joint laxity, cartilage wear, and the presence of osteophytes.⁴³

The difficulty with interpreting MAT failure in published studies is understanding the criteria the authors use to define it. Certainly, failure rates will change depending on the criteria applied, such as reoperation, revision MAT, conversion to arthroplasty, MRI evidence of graft extrusion, and/or poor outcomes scores on validated knee outcome assessment tools. Most studies define failure as conversion to total knee arthroplasty. Two systematic reviews demonstrated an overall failure rate that ranged from 0% to 35%, yet all studies assessed in these two reviews found the mean failure rate of MAT to be approximately 10% nearly 5 years after surgery.^{44,45} Longer-term outcomes reporting Kaplan–Meier survival analysis with total knee arthroplasty as an endpoint showed 83% survival at 10 years in addition to 32% and 38% survival at 20-year follow-up for medial and lateral meniscus allografts, respectively.⁴⁶

Another complication can be progression of osteoarthritic changes. Verdonk et al.²⁸ found that 52% of a cohort of patients followed for a mean of 12 years did not show any change in joint space width. Vundelinckx et al.³¹ reported on 49 patients after 15 years of follow-up and found that 58% had no increased osteoarthritic changes, whereas 24% exhibited an increase by one degree.

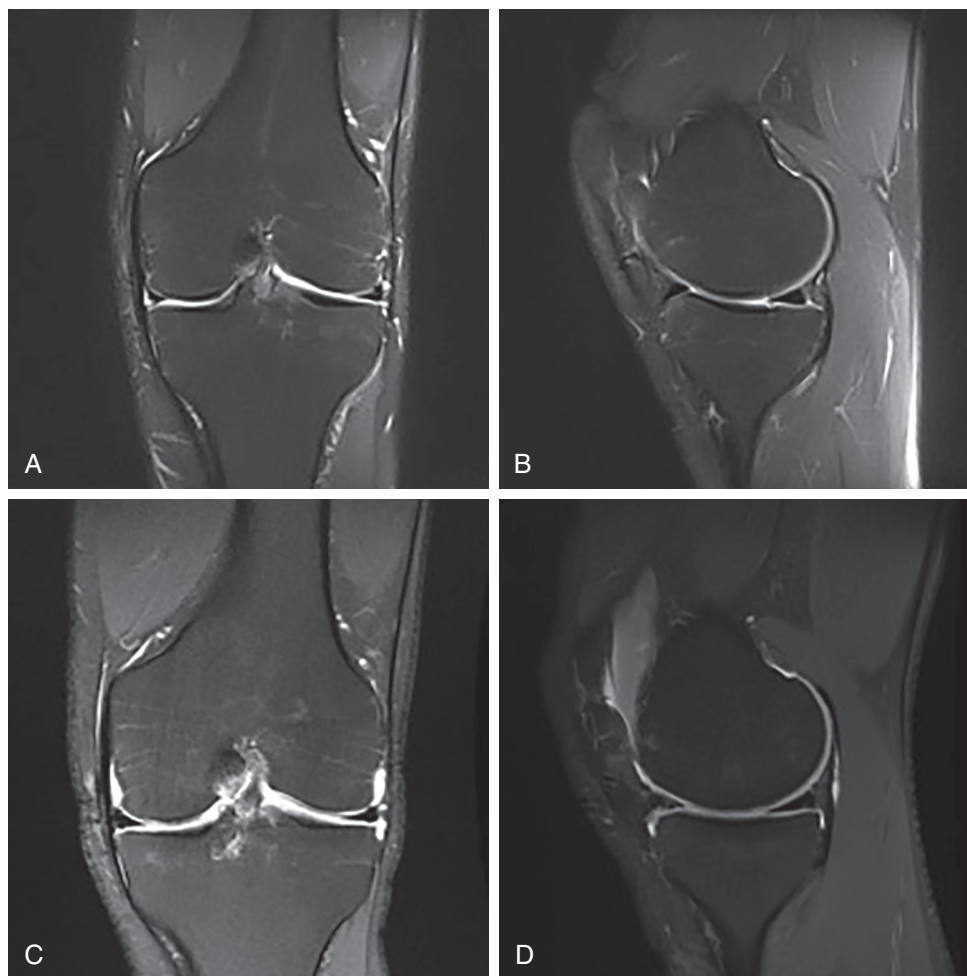
Unaddressed malalignment can lead to progressive complications and failure. Van Arkel et al.⁴⁷ reported a 13% MAT failure rate, and found that failure was primarily caused by malalignment resulting in impaired revascularization of the graft.⁴⁷ An additional study demonstrated 20 clinical successes and three failures requiring graft removal. The authors considered the failures to be secondary to uncorrected alignment.²⁶

In some patients, the source of failure is correlated with progression of osteoarthritis, missed grade III or IV changes, malalignment, suture-only fixation, or graft tears. Some of these failures may be preventable, and thorough stepwise preoperative evaluation may decrease the incidence of failure.

Outcomes

Despite the type and number of complications that can occur, MAT yields good to excellent results in nearly 85% of patients (Fig. 3.6 and 3.7).^{6,7,13,25,48}

Frank et al. reported an overall survival rate of 95% at 5 years.¹² Although 33% of patients underwent a secondary surgery, most of these procedures were for arthroscopic debridement, and the patients had excellent outcomes



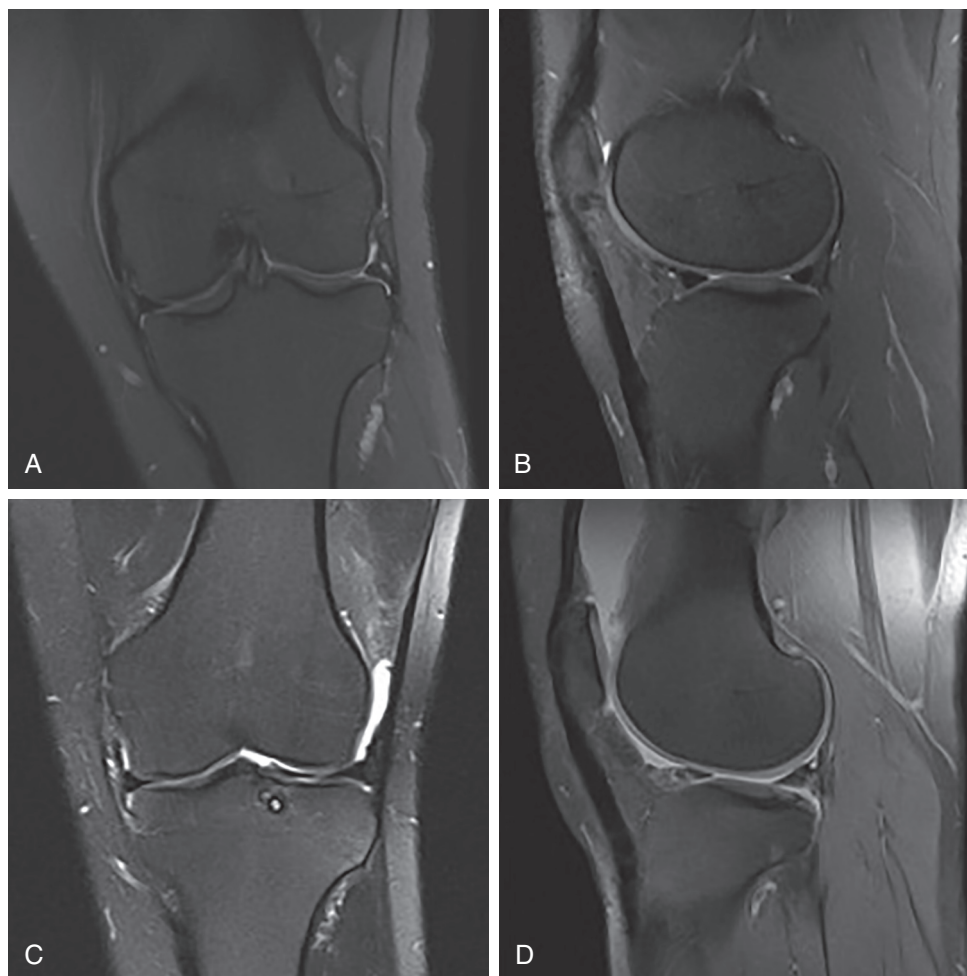
• **Fig. 3.6** T2 weighted preoperative (A) coronal and (B) sagittal magnetic resonance imaging (MRI) scans demonstrating a meniscus-deficient medial compartment of the left knee. Postoperative T2-weighted (C) coronal and (D) sagittal MRI images 2.5 years after surgery demonstrating a well-healed left medial meniscus transplant.

2 years after their index surgery. Chalmers et al.⁴⁹ reported a 77% return to play rate at an average of 17 months following surgery in high-level athletes, with significant improvements in all outcome scales at a follow-up of 3.3 years.

Verdonk et al.³⁵ reported a survival rate of 74.2% for medial allografts and 69.8% for lateral allografts at 10-year follow-up. Saltzman et al.²⁹ reported their MAT results in 22 patients with a minimum follow-up of 7 years; all patients significantly improved the quality of life, Lysholm, International Knee Documentation Committee, and KOOS scores, with excellent satisfaction scores and an overall success rate of 88%. El Attar and colleagues conducted a metaanalysis of 44 separate clinical studies of over 1000 MATs with a mean patient age of 34.8 years. The investigators concluded that “MAT can be considered as safe and reliable for the treatment of refractory postmeniscectomy symptoms in selected patients” (Table 3.1).⁴⁴

Conclusion

Complications are inherent in a procedure as complex as MAT. The types and frequency of complications vary based on preoperative evaluation, sizing, graft preservation, intraoperative technique, and postoperative follow-up. For each step in the process, we have outlined potential complications and what preventative measures can be taken to reduce their occurrence. Also, recognizing factors that improve outcomes and reduce early failure, such as appropriate concomitant procedures, is essential to mastering this procedure. This chapter not only evaluates potential complications throughout the whole process from preoperative evaluation to postoperative management, but also offers expert advice on how to prevent them. The goal of MAT is to offer a young, active patient population the potential to return to relatively normal activities pain-free and with good long-term outcomes.



• **Fig. 3.7** T2 weighted preoperative (A) coronal and (B) sagittal magnetic resonance imaging (MRI) scans demonstrating a meniscus-deficient lateral compartment of the left knee. Postoperative T2 weighted (C) coronal and (D) sagittal MRI images demonstrating a well-healed left lateral meniscus transplant 1 year after lateral meniscus allograft transplant of the left knee.

TABLE 3.1 Meniscus Allograft Transplant Clinical Results

Authors	Follow-Up Period	Clinical Outcome
Stone et al. ⁶	Range, 2–7 years	89.1% successful
Rue et al. ⁷	Mean, 3.1 years (range, 1.9–5.6)	93.5% successful
Farr ¹³	Mean, 4.5 years	87.9% successful
Sekiya ²⁵	Mean, 3.3 years (range, 2–6 years)	96% improved activity and function
Marcacci et al. ⁴⁹	Mean, 40.4 months, (range, 36–66 months)	94% successful
Verdonk ³⁸	10-year survival	74.2% medial survival, 69.8% lateral survival
Saltzman et al. ²⁹	Mean, 8.5 years	88% successful
El Attar ⁴⁴	Mean, 4.6 years (range, 8 months–20 years)	10.6% failure rate
Chalmers et al. ⁴⁹	Mean, 3.3 years (range, 1.9–5.7 years)	77% returned to high-level sporting activity

References

1. Walker PS, Erkman MJ. The role of the menisci in force transmission across the knee. *Clin Orthop Relat Res.* 1975;109:184–192.
2. Baratz ME, Fu FH, Mengato R. Meniscal tears: the effect of meniscectomy and of repair on intraarticular contact areas and stress in the human knee. A preliminary report. *Am J Sports Med.* 1986;14(4):270–275.
3. Allen PR, Denham RA, Swan AV. Late degenerative changes after meniscectomy. Factors affecting the knee after operation. *J Bone Joint Surg Br.* 1984;66(5):666–671.
4. Noyes FR, Barber-Westin SD, Rankin M. Meniscal transplantation in symptomatic patients less than fifty years old. *J Bone Jt Surg - Ser A.* 2004;86(7):1392–1404.
5. Verdonk R, Volpi P, Verdonk P, et al. Indications and limits of meniscal allografts. *Injury.* 2013;44(suppl 1):S21–S27.
6. Stone KR, Walgenbach AW, Turek TJ, Freyer A, Hill MD. Meniscus allograft survival in patients with moderate to severe unicompartmental arthritis: a 2- to 7-year follow-up. *Arthrosc J Arthrosc Relat Surg.* 2006;22(5):469–478.
7. Rue JPH, Yanke AB, Busam ML, McNickle AG, Cole BJ. Prospective evaluation of concurrent meniscus transplantation and articular cartilage repair: minimum 2-year follow-up. *Am J Sports Med.* 2008;36(9):1770–1778.
8. Cole BJ, Carter TR, Rodeo SA. Allograft meniscal transplantation: background, techniques and results. *J Bone Jt Surg - Ser A.* 2002;84:1236–1250.
9. Cole BJ, Dennis MG, Lee SJ, et al. Prospective evaluation of allograft meniscus transplantation: a minimum 2-year follow-up. *Am J Sports Med.* 2006;34(6):919–927.
10. Verdonk R, Almqvist K, Verdonk P. Meniscal allografts: indications and results. In: Doral MN, Karlsson J, eds. *Sports Injuries: Prevention, Diagnosis, Treatment and Rehabilitation.* 2nd ed. Springer: Verlag Berlin Heidelberg; 2015:1183–1190.
11. Verdonk R, Madry H, Shabshin N, et al. The role of meniscal tissue in joint protection in early osteoarthritis. *Knee Surgery, Sport Traumatol Arthrosc.* 2016;24(6):1763–1774.
12. Frank RM, Cole BJ. Meniscus transplantation. *Curr Rev Musculoskelet Med.* 2015;8(4):443–450.
13. Farr J, Rawal A, Marberry KM. Concomitant meniscal allograft transplantation and autologous chondrocyte implantation: minimum 2-year follow-up. *Am J Sports Med.* 2007;35(9):1459–1466.
14. Jiang D, Yu JK. Immediate versus delayed meniscus allograft transplantation: response. *Am J Sports Med.* 2015;43(5):NP9–NP10.
15. Dienst M, Greis PE, Ellis BJ, Bachus KN, Burks RT. Effect of lateral meniscal allograft sizing on contact mechanics of the lateral tibial plateau: an experimental study in human cadaveric knee joints. *Am J Sports Med.* 2007;35(1):34–42.
16. Huang A, Hull ML, Howell SM, Haut Donahue T. Identification of cross-sectional parameters of lateral meniscal allografts that predict tibial contact pressure in human cadaveric knees. *J Biomech Eng.* 2002;124(5):481–489.
17. Pollard ME, Kang Q, Berg EE. Radiographic sizing for meniscal transplantation. *Arthrosc J Arthrosc Relat Surg.* 1995;11(6):684–687.
18. Lubowitz JH, Verdonk PCM, Reid JB, Verdonk R. Meniscus allograft transplantation: a current concepts review. *Knee Surg Sports Traumatol Arthrosc.* 2007;15(5):476–492.
19. Sekiya JK, Ellingson CI. Meniscal allograft transplantation. *J Am Acad Orthop Surg.* 2006;14(3):164–174.
20. McDermott ID. What tissue bankers should know about the use of allograft meniscus in orthopaedics. *Cell Tissue Bank.* 2010;11(1):75–85.
21. Lewis PB, Williams JM, Hallab N, Virdi A, Yanke A, Cole BJ. Multiple freeze-thaw cycled meniscal allograft tissue: A biomechanical, biochemical, and histologic analysis. *J Orthop Res.* 2008;26(1):49–55.
22. Shelbourne KD, Gray T. Results of anterior cruciate ligament reconstruction based on meniscus and articular cartilage status at the time of surgery. Five- to fifteen- year evaluations. *Am J Sports Med.* 2000;28(4):446–452.
23. Shoemaker SC, Markolf KL. The role of the meniscus in the anterior-posterior stability of the loaded anterior cruciate-deficient knee: effects of partial versus total excision. *J Bone Jt Surg - Am.* 1986;68(1):71–79.
24. Yoon JR, Kim TS, Wang JH, Yun HH, Lim H, Yang JH. Importance of independent measurement of width and length of lateral meniscus during preoperative sizing for meniscal allograft transplantation. *Am J Sports Med.* 2011;39(7):1541–1547.
25. Sekiya JK, West RV, Groff YJ, Irrgang JJ, Fu FH, Harner CD. Clinical outcomes following isolated lateral meniscal allograft transplantation. *Arthroscopy.* 2006;22(7):771–780.
26. Sekiya JK, Giffin JR, Irrgang JJ, Fu FH, Harner CD. Clinical outcomes after combined meniscal allograft transplantation and anterior cruciate ligament reconstruction. *Am J Sports Med.* 2003;31(6):896–906.
27. Wirth CJ, Peters G, Milachowski KA, Weismeier KG, Kohn D. Long-term results of meniscal allograft transplantation. *Am J Sport Med.* 2002;30(2):174–181.
28. Verdonk PCM, Verstraete KL, Almqvist KF, et al. Meniscal allograft transplantation: long-term clinical results with radiological and magnetic resonance imaging correlations. *Knee Surgery, Sport Traumatol Arthrosc.* 2006;14(8):694–706.
29. Saltzman BM, Bajaj S, Salata M, et al. Prospective long-term evaluation of meniscal allograft transplantation procedure: a minimum of 7-year follow-up. *J Knee Surg.* 2012;25(2):165–175.
30. McCormick F, Harris JD, Abrams GD, et al. Survival and reoperation rates after meniscal allograft transplantation: analysis of failures for 172 consecutive transplants at a minimum 2-year follow-up. *Am J Sports Med.* 2014;42(4):892–897.
31. Vundelinckx B, Vanlauwe J, Bellemans J. Long-term subjective, clinical, and radiographic outcome evaluation of meniscal allograft transplantation in the knee. *Am J Sports Med.* 2014;42(7):1592–1599.
32. Rath E, Richmond JC, Yassir W, Albright JD, Gundogan F. Meniscal allograft transplantation. Two- to eight-year results. *Am J Sports Med.* 2001;29(4):410–414.
33. Wang Y, Wluka AE, Pelletier JP, et al. Meniscal extrusion predicts increases in subchondral bone marrow lesions and bone cysts and expansion of subchondral bone in osteoarthritic knees. *Rheumatology.* 2010;49(5):997–1004.
34. Costa CR, Morrison WB, Carrino JA. Medial meniscus extrusion on knee MRI: is extent associated with severity of degeneration or type of tear? *Am J Roentgenol.* 2004;183(1):17–23.
35. Verdonk PCM, Demurie A, Almqvist KF, Veys EM, Verbruggen G, Verdonk R. Transplantation of viable meniscal allograft. *JBJS Essent Surg Tech.* 2006;88(1 suppl 1):109–118.
36. Lee BS, Kim JM, Kim KA, Bin SI. Patient-related risk factors for the extrusion of lateral meniscal allograft transplants. *Arthroscopy.* 2015;31(4):699–706.

37. Spencer SJ, Saithna A, Carmont MR, Dhillon MS, Thompson P, Spalding T. Meniscal scaffolds: early experience and review of the literature. *Knee*. 2012;19(6):760–765.
38. Lee DH, Kim TH, Lee SH, Kim CW, Kim JM, Bin SI. Evaluation of meniscus allograft transplantation with serial magnetic resonance imaging during the first postoperative year: focus on graft extrusion. *Arthrosc - J Arthrosc Relat Surg*. 2008;24(10):1115–1121.
39. Jang SH, Kim JG, Ha JG, Shim JC. Reducing the size of the meniscal allograft decreases the percentage of extrusion after meniscal allograft transplantation. *Arthrosc - J Arthrosc Relat Surg*. 2011;27(7):914–922.
40. Lee DH, Kim SB, Kim TH, Cha EJ, Bin SI. Midterm outcomes after meniscal allograft transplantation: Comparison of cases with extrusion versus without extrusion. *Am J Sports Med*. 2010;38(2):247–254.
41. Lee DH, Lee CR, Jeon JH, Kim KA, Bin SI. Graft extrusion in both the coronal and sagittal planes is greater after medial compared with lateral meniscus allograft transplantation but is unrelated to early clinical outcomes. *Am J Sports Med*. 2015;43(1):213–219.
42. Abat F, Gelber PE, Erquicia JI, Pelfort X, Gonzalez-Lucena G, Monllau JC. Suture-only fixation technique leads to a higher degree of extrusion than bony fixation in meniscal allograft transplantation. *Am J Sports Med*. 2012;40(7):1591–1596.
43. Verdonk P, Depaeppe Y, Desmyter S, et al. Normal and transplanted lateral knee menisci: evaluation of extrusion using magnetic resonance imaging and ultrasound. *Knee Surgery, Sport Traumatol Arthrosc*. 2004;12(5):411–419.
44. El Attar M, Dhollander A, Verdonk R, Almqvist KF, Verdonk P. Twenty-six years of meniscal allograft transplantation: Is it still experimental? A meta-analysis of 44 trials. *Knee Surg, Sport Traumatol Arthrosc*. 2011;19(2):147–157.
45. Smith NA, MacKay N, Costa M, Spalding T. Meniscal allograft transplantation in a symptomatic meniscal deficient knee: a systematic review. *Knee Surg, Sport Traumatol Arthrosc*. 2014;23(1):270–279.
46. Verdonk P, Beaufils P, Bellemans J, et al. Successful treatment of painful irreparable partial meniscal defects with a polyurethane scaffold: two-year safety and clinical outcomes. *Am J Sports Med*. 2012;40(4):844–853.
47. van Arkel ER, Goei R, de Ploeg I, de Boer HH. Meniscal allografts: evaluation with magnetic resonance imaging and correlation with arthroscopy. *Arthroscopy*. 2000;16(5):517–521.
48. Verstraete KL, Verdonk R, Lootens T, Verstraete P, De Rooy J, Kunnen M. Current status and imaging of allograft meniscal transplantation. *Eur J Radiol*. 1997;26(1):16–22.
49. Chalmers PN, Karas V, Sherman SL, Cole BJ. Return to high-level sport after meniscal allograft transplantation. *Arthrosc - J Arthrosc Relat Surg*. 2013;29(3):539–544.