

THE JOURNAL OF BONE & JOINT SURGERY

# JB&JS

*This is an enhanced PDF from The Journal of Bone and Joint Surgery*

*The PDF of the article you requested follows this cover page.*

---

## Meniscal Transplantation in Symptomatic Patients Less Than Fifty Years Old

Frank R. Noyes, Sue D. Barber-Westin and Marc Rankin  
*J Bone Joint Surg Am.* 87:149-165, 2005. doi:10.2106/JBJS.E.00347

---

**This information is current as of September 28, 2005**

### Reprints and Permissions

Click here to [order reprints or request permission](#) to use material from this article, or locate the article citation on [jbjs.org](http://jbjs.org) and click on the [Reprints and Permissions] link.

### Publisher Information

The Journal of Bone and Joint Surgery  
20 Pickering Street, Needham, MA 02492-3157  
[www.jbjs.org](http://www.jbjs.org)

# Meniscal Transplantation in Symptomatic Patients Less Than Fifty Years Old

## Surgical Technique

BY FRANK R. NOYES, MD, SUE D. BARBER-WESTIN, BS, AND MARC RANKIN, MD

*Investigation performed at Cincinnati Sportsmedicine and Orthopaedic Center, Cincinnati, Ohio*

*The original scientific article in which the surgical technique was presented was published in JBJS Vol. 86-A, pp. 1392-1404, July 2004*

### INTRODUCTION

Meniscal transplantation remains an evolving area, as investigations of tissue-processing, secondary sterilization, and long-term function continue to be performed to evaluate the overall efficacy of the procedure. The primary candidate for the procedure is a young patient who has had a total meniscectomy and has pain in the tibiofemoral compartment because of early joint arthrosis. There are few treatment options for these patients, and the goal of meniscal transplantation in the short term is to decrease pain, increase knee function, allow pain-free activities of daily living, and delay the progression of tibiofemoral arthrosis. In this report, we describe the preparation of the meniscal transplant and the meticulous surgical technique that is required to achieve an anatomically secure attachment and position in order to provide load-bearing function in the tibiofemoral joint. There are differences between the techniques for medial and lateral meniscal transplantation as a result of the characteristics of the anatomic attachment sites.

### SURGICAL TECHNIQUE

#### *Sizing and Inspection of Meniscal Transplants*

Anteroposterior and lateral radiographs are used to measure the approximate width and length of the meniscal transplant<sup>1</sup>. The surgeon should have knowledge of the donor-selection criteria and tissue-processing procedures of the tissue bank as these may vary substantially, even among tissue banks that are certified by the American Association of Tissue Banks and that follow the guidelines of the United States Food and Drug Administration. The implications of different process-

### ABSTRACT

#### **BACKGROUND:**

The purpose of this study was to prospectively evaluate the results of meniscal transplantation in a consecutive series of younger patients treated for pain in the tibiofemoral compartment following a previous meniscectomy.

#### **METHODS:**

Forty cryopreserved menisci were implanted into thirty-eight patients. Sixteen knees also had an osteochondral autograft transfer, and nine had a knee ligament reconstruction. The clinical outcome and failure rate of all transplants were evaluated at a mean of forty months postoperatively. Meniscal allograft characteristics were determined with use of a rating system that combined subjective, clinical, and magnetic resonance imaging factors.

*continued*

**ABSTRACT** | continued**RESULTS:**

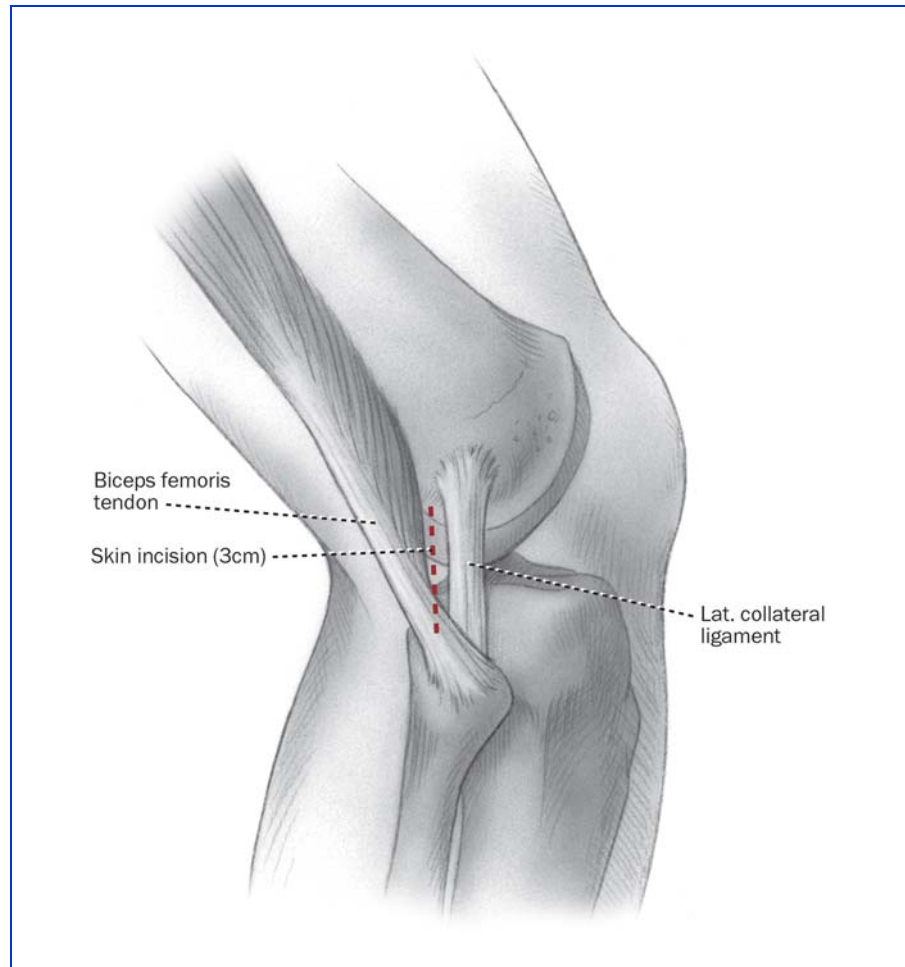
Thirty-four (89%) of the thirty-eight patients rated the knee condition as improved. Before surgery, thirty patients (79%) had pain with daily activities, but only four (11%) had such pain at the time of the latest follow-up. While noteworthy pain was present in the tibiofemoral compartment in all forty knees before surgery, twenty-seven knees (68%) had no pain and thirteen (33%) had only mild compartment pain at the time of the latest follow-up. Twenty-nine patients (76%) returned to light low-impact sports without problems. Concomitant osteochondral autograft transfer and knee ligament reconstruction procedures improved knee function and did not increase the rate of complications. Meniscal allograft characteristics were normal in seventeen knees (43%), altered in twelve (30%), and failed in eleven (28%).

**CONCLUSIONS:**

The short-term results of meniscal transplantation are encouraging in terms of reducing knee pain and increasing function; however, long-term transplant function and any chondroprotective effects remain unknown and require further investigation.

ing techniques with regard to graft sterility are important<sup>2-4</sup> but beyond the scope of this report.

We advise the surgeon to request that the tissue bank provide, well before the surgery, a photograph of the transplant

**FIG. 1-A**

Site of the posterolateral incision for a lateral meniscal transplant.

that has been selected for each patient. A metric ruler should be placed adjacent to the transplant in the photograph to ensure that the allograft is of adequate size and width. The surgeon should also be aware that certain medial menisci have a hypoplastic anterior horn that is narrow, inserting distal to the medial tibial surface (Type III<sup>5</sup>), and that these menisci are not acceptable for implantation. Also, if the middle one-third of a medial or lateral meniscus is 8 to 10 mm in width, it is suitable

only for small patients. In addition, if the lateral meniscus has reduced anteroposterior length, less than that calculated on the sagittal radiograph, it is not suitable for implantation.

The meniscus is thawed, inspected, and prepared prior to the administration of the anesthesia because it is difficult to detect implant defects through the plastic packaging. The implant is also prepared first so that the surgeon can determine the depth and width required for the tibial slot when the cen-

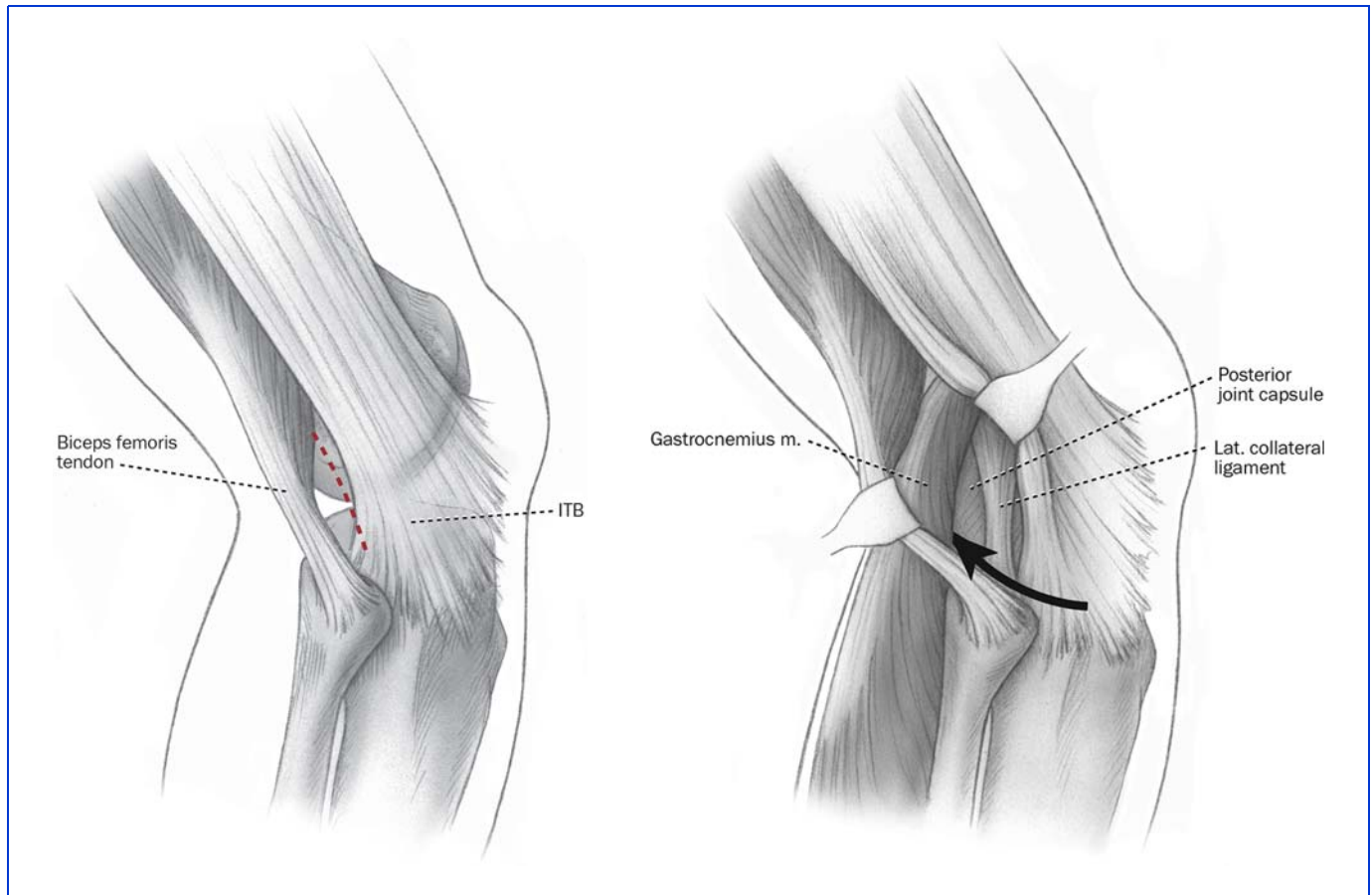


FIG. 1-B

FIG. 1-C

**Fig. 1-B** Incision site in the interval between the posterior edge of the iliotibial band (ITB) and the anterior edge of the biceps tendon.

**Fig. 1-C** The interval between the lateral head of the gastrocnemius and the posterolateral aspect of the capsule is opened bluntly, just proximal to the fibular head, without entering the joint capsule proximally.

tral bone-bridge technique is selected.

### *Technique for Lateral Meniscal Transplantation Preparation*

The lateral meniscus, with the anterior and posterior horns remaining attached centrally to bone, is a better transplant than the medial meniscus. Because the attachment sites and circumference tension relationships are not disturbed, an arthroscopically assisted tibial slot method<sup>2</sup> of attachment can be performed

with a meticulous inside-out meniscal repair<sup>6</sup>. The central bone portion of the transplant incorporates the anterior and posterior meniscal attachments and usually measures 8 to 9 mm in width, 35 mm in length, and 10 mm in depth. The posterior 8 to 10 mm of bone that protrudes beyond the posterior horn attachment is removed to later produce a buttress against the bone trough in the host knee. Commercially available sizing blocks and channel cutters (Stryker Endoscopy, Kala-

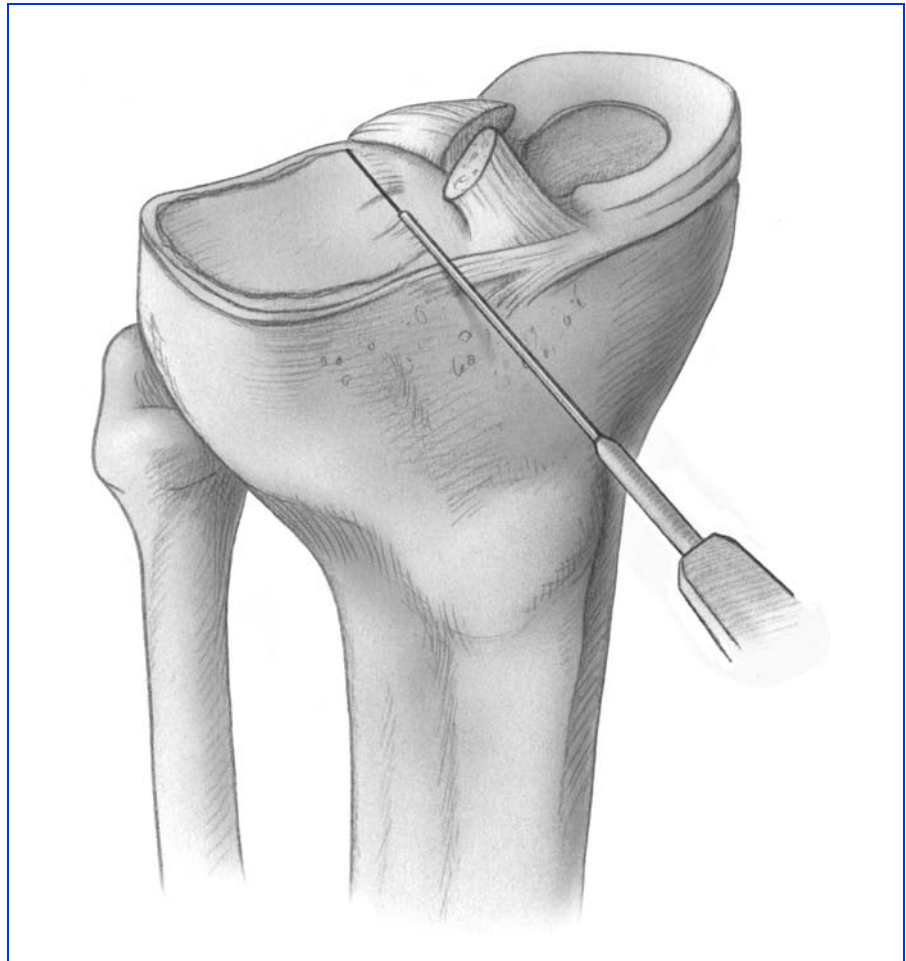
mazoo, Michigan, and CryoLife, Kennesaw, Georgia) allow appropriate sizing.

### **Surgical Technique**

The patient is placed in a supine position on the operating room table, with a tourniquet applied with a leg-holder and the table adjusted to allow 90° of knee flexion. The contralateral lower extremity is placed in a thigh-high elastic stocking and is padded to maintain mild hip flexion to decrease tension on the femoral nerve. After examination with

the patient under anesthesia, diagnostic arthroscopy is done to confirm the preoperative diagnosis and to assess changes in the articular cartilage. An arthroscopically assisted approach is used in knees that require a cruciate ligament reconstruction<sup>7</sup>. The femoral and tibial tunnels are drilled, and the ligament graft is passed through the tunnels, with femoral fixation done first, followed by the meniscal transplantation, and then by tibial fixation of the cruciate graft. Fixing the ligament graft at the tibia as the final step allows maximum separation of the tibiofemoral joint during meniscal transplantation. It also prevents failure or problems with the ligament fixation or ligament graft during the operation.

A limited 3-cm lateral arthrotomy is made just adjacent to the patellar tendon. Although there are arthroscopic techniques for preparation of the tibial slot, we believe that the limited arthrotomy provides superior visualization and makes it possible to avoid incision into the patellar tendon. A second, 3-cm posterolateral accessory incision is made, centered just behind the lateral collateral ligament (Fig. 1-A)<sup>6,8</sup>. The interval between the biceps tendon insertion and the iliotibial band is identified and incised (Fig. 1-B). The lateral head of the gastrocnemius is gently dissected with Metzenbaum scissors off of the posterior aspect of the capsule at the joint line (Fig. 1-C). Care is taken at this point because dis-

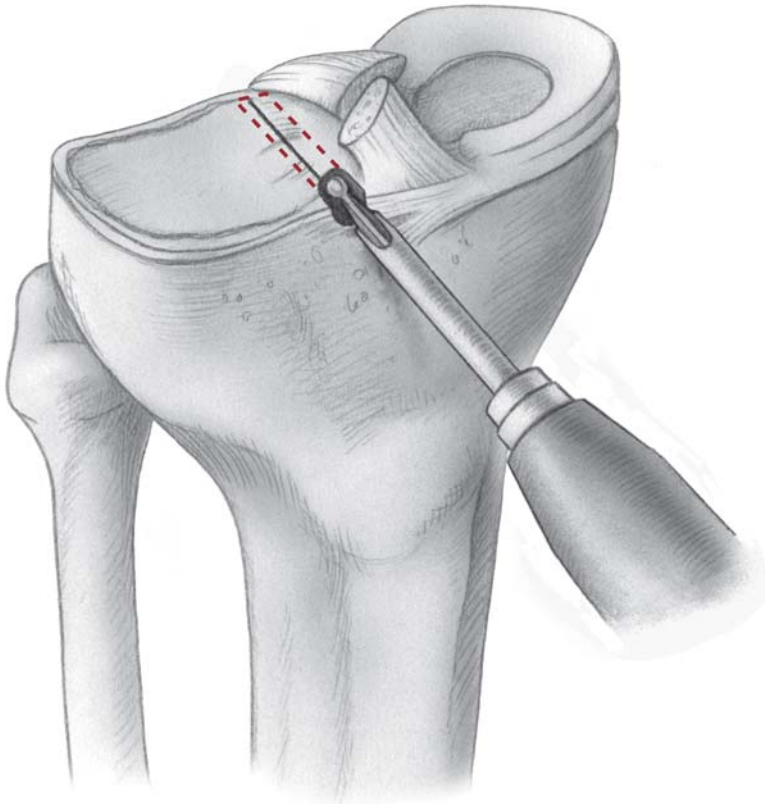


**FIG. 2-A**

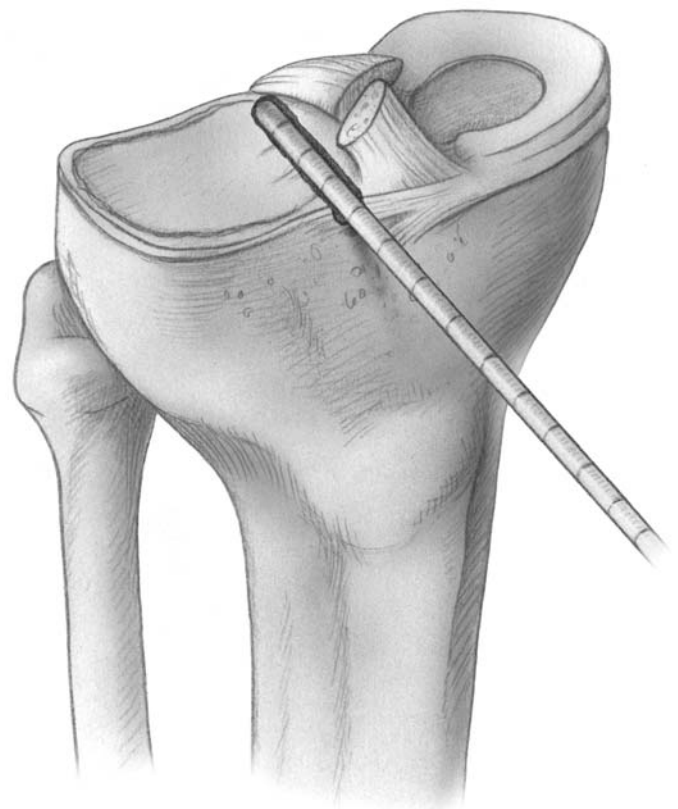
**Figs. 2-A through 2-E** Tibial slot technique for lateral and medial meniscal transplantation, which is shown here for the lateral meniscus. An arthroscopically assisted technique or a mini-lateral arthrotomy may be used, but we prefer the mini-arthrotomy as it offers superior visualization and allows us to avoid incising the patellar tendon. A detailed description of the surgical steps and operative instruments used for the tibial slot technique is available<sup>14</sup>. **Fig. 2-A** A line is established connecting the center of the anterior and posterior horn attachments with an electrocautery device. In the mini-open arthrotomy, a template of the meniscal coronal width is used to verify the medial-to-lateral width of the transplant so that the slot can be moved appropriately to prevent tibial overhang of the implant.

section that extends too far proximal to the joint line at the posterolateral aspect would enter the joint capsule. If this occurs, a capsular repair is required to maintain joint integrity during the inside-out meniscal repair. The lateral inferior genicular artery is also in

close proximity, and it is identified and preserved. The space between the posterolateral aspect of the capsule and the lateral head of the gastrocnemius is further developed bluntly. An appropriately sized popliteal retractor (Stryker) is placed directly behind the lateral meniscal

**FIG. 2-B**

A burr is used to remove the tibial spine and create a 4-mm straight anterior-to-posterior reference slot along the plane of the tibial slope. This calibrated guide pin sits flush with the articular cartilage.



**CRITICAL CONCEPTS****INDICATIONS:**

The indications for a meniscal allograft procedure are prior meniscectomy, an age of fifty years or less, pain in the tibiofemoral compartment, no radiographic evidence of advanced arthrosis, and  $\geq 2$  mm of tibiofemoral joint space as seen on 45° weight-bearing posteroanterior radiographs<sup>10</sup>.

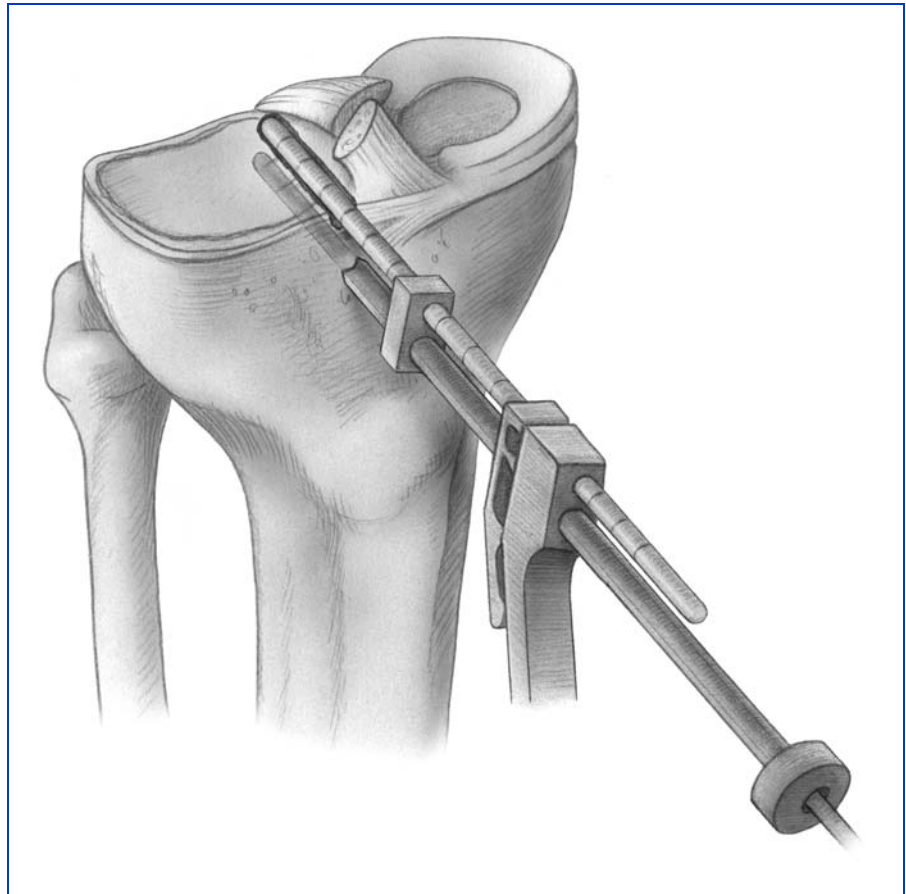
**CONTRAINDICATIONS:**

Contraindications include advanced arthrosis of the knee joint with flattening of the femoral condyle, concavity of the tibial plateau, and osteophytes that prevent anatomic seating of the meniscal allograft<sup>11</sup>; axial varus malalignment in which a weight-bearing line of <40% of the medial-lateral transverse width of the tibial plateau<sup>12</sup> is seen on radiographs or valgus malalignment in which a weight-bearing line of >60% is seen on radiographs; instability of the knee joint or the patient's refusal to undergo concomitant knee ligament reconstruction; knee arthrofibrosis; muscular atrophy; and previous joint infection.

*continued*

bed. The tourniquet is inflated only for these two approaches; otherwise, it is not used.

The width of the transplant is determined, and an aluminum foil template of the same width and length as the transplant is cut and is inserted into the lateral compartment to determine the lateralmost margin of the bone trough. This sizing step is important to make sure that there is no lateral overhang of

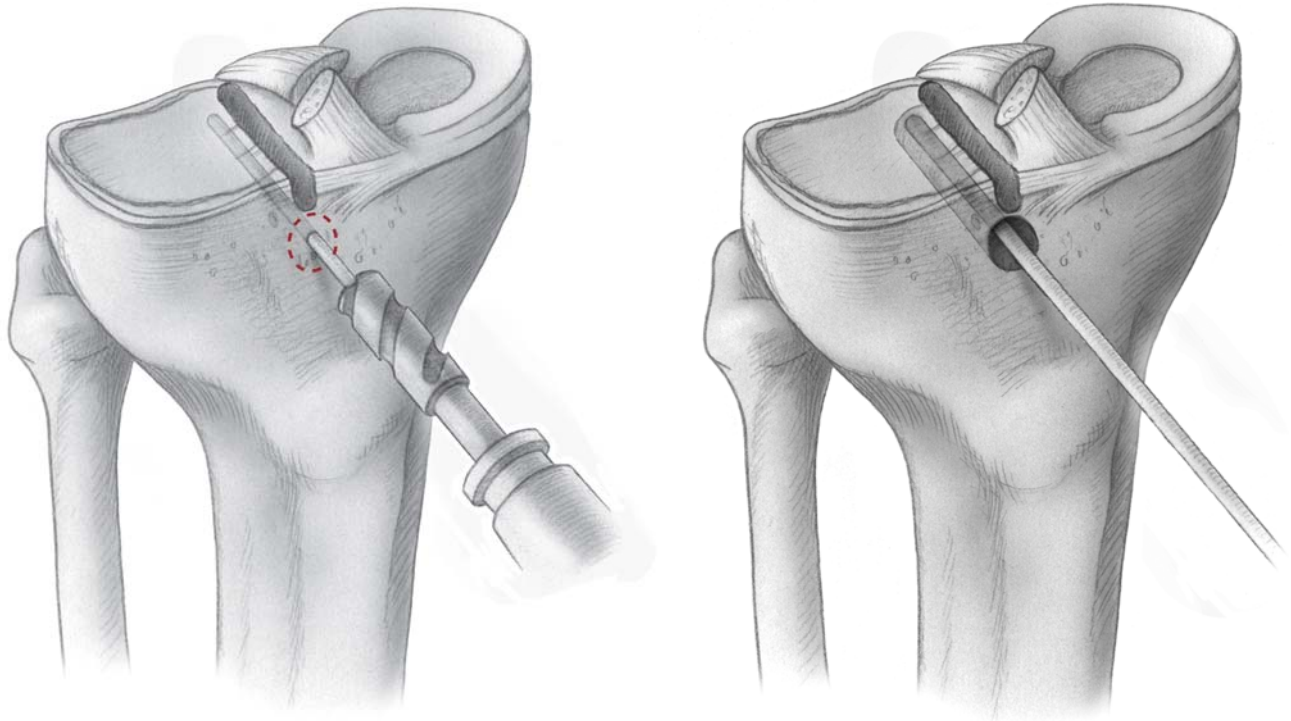


**FIG. 2-C**

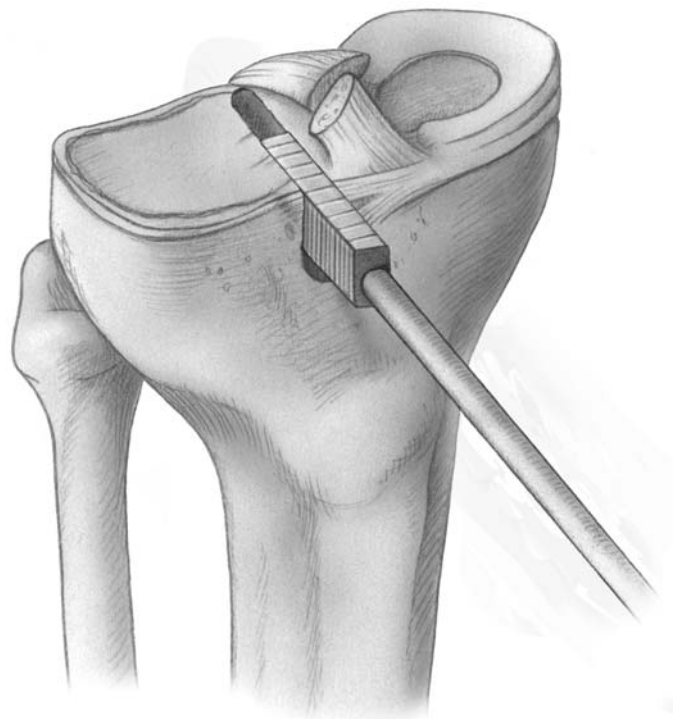
The drill guide is used with a guide pin that has been marked with a laser to set the depth of a second guide pin. This allows a drill to ream 5 mm less to retain the posterior portion of the tibial slot.

the meniscal body produced by placing the bone trough too far laterally. A rectangular bone trough is prepared at the anterior and posterior tibial attachment sites of the lateral meniscus to match the dimensions of the prepared lateral meniscal transplant. The sequence of steps to prepare the lateral tibial slot is illustrated in Figures 2-A through 2-D. The tibial bone slot is 1 to 2 mm wider than the transplant, to facilitate implantation. The anterior and posterior horns of the implant are placed into their normal attachment locations,

adjacent to the anterior cruciate ligament. The allograft is inserted into the trough (Fig. 2-E), and the bone portion of the graft is seated against the posterior bone buttress to achieve correct anterior-to-posterior placement of the attachment sites. A vertical suture in the posterior part of the meniscal body is passed posteriorly to provide tension and facilitate implant placement. The knee is flexed, extended, and rotated to confirm correct allograft placement. The posterior suture is tied, and sutures are placed in a vertical fashion into

**FIG. 2-D**

An 8-mm drill bit with a collar at the defined depth is used, followed by use of a box cutter to create a rectangular slot of the desired depth and width.





the anterior one-third of the meniscus, attaching it to the prepared meniscal rim under direct visualization.

An alternative technique is to use a starter chisel and finishing chisels to fashion the tibial trough to its final depth and width (Fig. 3-A). A tibial trough sizing guide is employed to check the length and depth (Fig. 3-B). The allograft sizing block (Fig. 3-C) confirms that the allograft bone bridge is of the correct width and depth.

Two methods are available for fixation of the central bone attachment. Two 2-0 nonabsorbable sutures (Ticron [Davis and Geck, Wayne, New Jersey] or Ethibond [Ethicon, Somerville, New Jersey]) may be placed in the central region, brought through a drill hole, and tied. Our preferred method involves placement of an interference screw (7 × 25 mm),

made of an absorbable composite material, medial and adjacent to the central bone attachment<sup>9</sup>. The arthrotomy is closed, and the inside-out meniscal repair is performed with multiple vertical divergent sutures, which are placed first superiorly to reduce the meniscus (Fig. 4) and then inferiorly in the outer one-third of the implant. Sutures are not placed in the middle and inner thirds of the meniscus to avoid weakening the implant, which has a limited healing capability in these regions (Fig. 5).

#### *Technique for Medial Meniscal Transplantation Preparation*

The medial meniscal transplant is inspected to confirm that the size is appropriate and no degenerative changes are present. The implant is not prepared until it is decided whether the central

bone-bridge technique (which is preferred) or the two-tunnel technique (involving separate anterior and posterior bone attachments and tunnels) is required.

The patient is placed in a supine position on the operating room table, with a tourniquet applied with a leg-holder and the table adjusted to allow 90° of knee flexion. The contralateral lower extremity is placed in a thigh-high elastic stocking and is padded to maintain mild hip flexion to decrease tension on the femoral nerve. After examination with the patient under anesthesia, diagnostic arthroscopy is done to confirm the preoperative diagnosis and assess changes in the articular cartilage.

A 4-cm skin incision is made on the anterior aspect of the tibia adjacent to the tibial tubercle and the patellar tendon. A second,

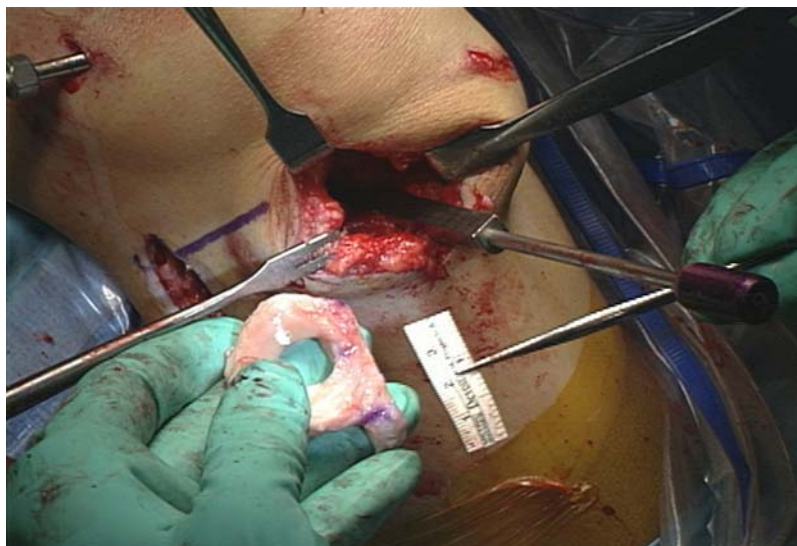

FIG. 2-E

The lateral meniscal implant with the central bone bridge is ready to be placed into the tibial slot.

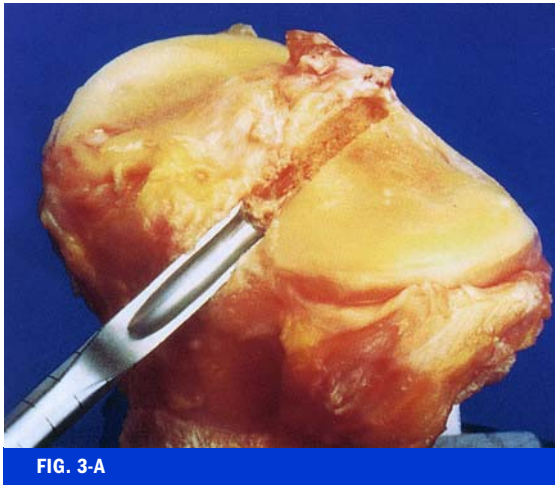


FIG. 3-A

**Figs. 3-A, 3-B, and 3-C** An alternative to the tibial slot technique. A detailed description of the surgical steps and operative instruments is available<sup>15</sup>. **Fig. 3-A** A starter chisel and finishing chisels are used to fashion the tibial trough to its final depth and width.

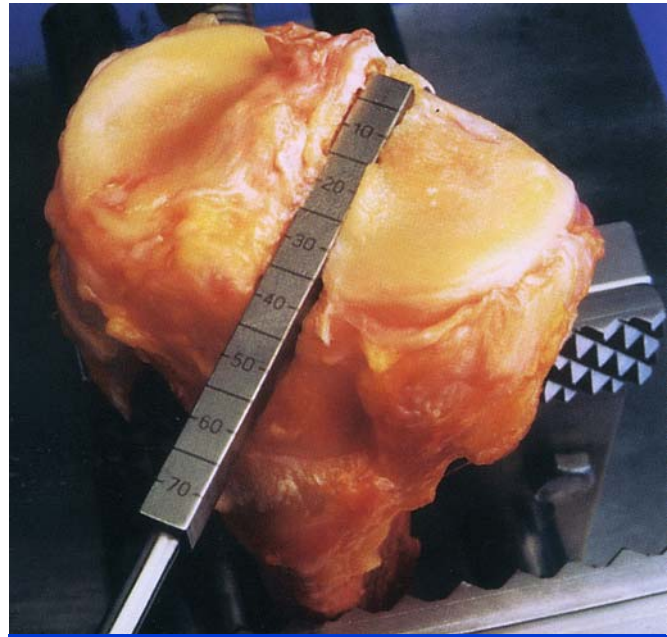


FIG. 3-B

A tibial trough sizing guide is used to check the length and depth.

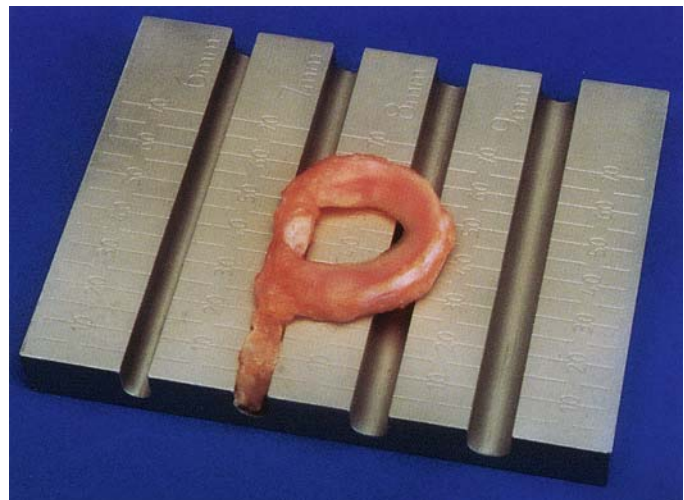


FIG. 3-C

The allograft sizing block confirms that the allograft bone bridge is of the desired width and depth.

3-cm vertical posteromedial incision, similar to that described for inside-out meniscal repairs<sup>8</sup>, is made just posterior to the superficial medial collateral ligament

(Fig. 6-A). The fascia is incised anterior to the sartorius (Fig. 6-B), and the pes anserinus muscle group is retracted posteriorly. The interval between the semi-

membranous tendon and the capsule is sharply dissected. The layer between the medial aspect of the gastrocnemius tendon and the posteromedial aspect of the

**CRITICAL CONCEPTS** | continued**PITFALLS:**

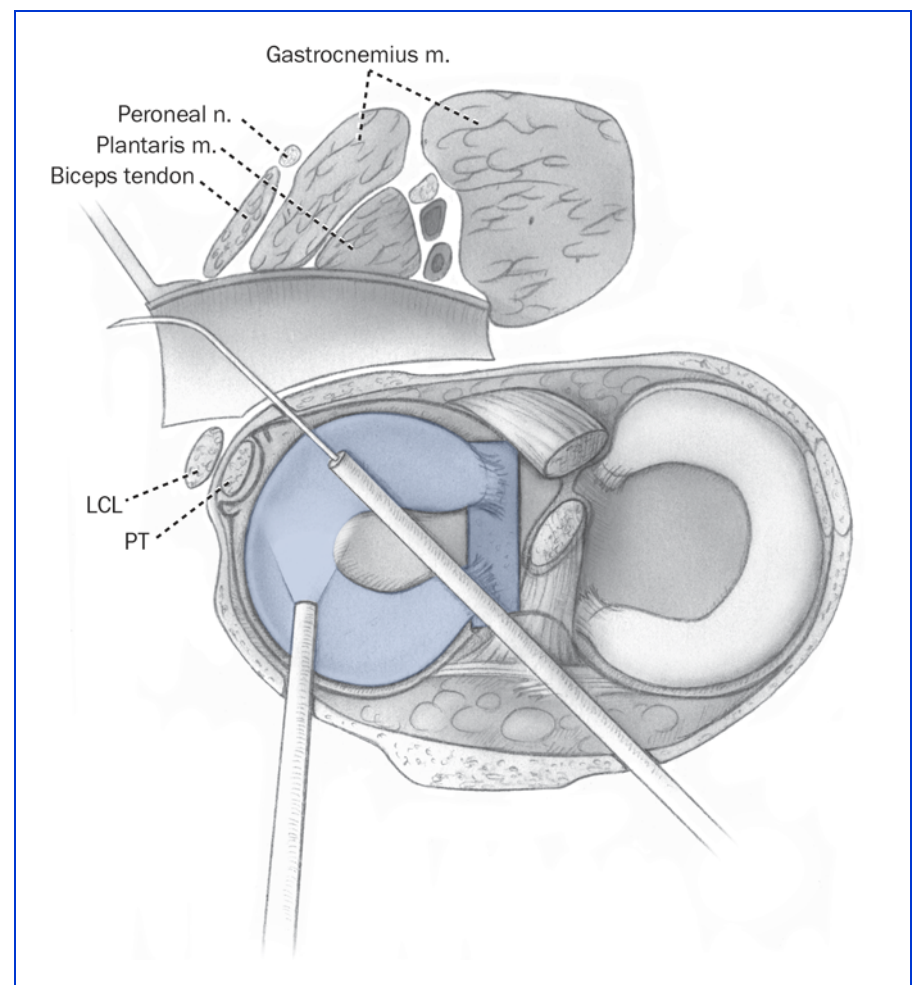
- The patient is informed that the transplant is inspected just before the surgical procedure in the operating room and that the decision to proceed with the procedure will be made at this time if the graft is deemed suitable. Also, there is the remote possibility that, during the operative procedure, either the final preparation or the implantation of the meniscal allograft may not be possible as a result of problems with its size or the ability to obtain correct positioning in the joint.
- The preparation of the meniscal template is critical for successful placement of the final tibial slot and correct positioning of the transplant. The aluminum foil template is made to represent the size of the implant and is inserted through the limited anterior arthrotomy incision.
- The slot placement for the lateral or medial meniscal transplant must be exact. Otherwise, the meniscus may be displaced at its midportion outside the joint, or it may be positioned too far inside the joint and subsequently incur excessive compression and tearing. It is possible to realign the bone trough a few millimeters medially or laterally in the coronal plane, and an absorbable interference screw can be used for fixation in the final coronal adjustment of the implant.
- During medial meniscal transplantation, the template may indicate that the transplant is excessively wide in the medial-to-lateral direction. If it does, the middle one-third of the

*continued*

capsule is separated with blunt dissection (Fig. 6-C). Great care is taken to identify and avoid injury to the infrapatellar branches of the saphenous nerve. The two approaches are performed with the tourniquet inflated to 275 mm Hg and usually require fifteen minutes; otherwise, the tourniquet is not used.

A medial meniscal transplant, with anatomically placed anterior and posterior bone at-

tachments, must be appropriately secured to maintain the desired position in the knee joint postoperatively and to provide the circumferential tension required for transplant function. A template of the medial meniscal transplant, made of aluminum foil and measured according to its anterior-posterior and medial-lateral dimensions, is inserted through the limited anterior arthrotomy incision and is

**FIG. 4**

Cross section showing a popliteal retractor between the lateral head of the gastrocnemius and the posterior aspect of the capsule. A single cannula is introduced from the adjacent portal to facilitate placement of the vertical sutures into the periphery of the meniscal implant. LCL = lateral collateral ligament, and PT = popliteus tendon.

sized to the medial tibial plateau. This allows the surgeon to mark the position of the central bone trough and to determine whether the meniscal implant will be properly positioned just adjacent to the tibial attachment of the anterior cruciate ligament, without excessive medial tibial overhang. Next, it is verified that the anterior and posterior attachments are located at the anatomically correct sites. With the central bone-bridge technique, 4 to 6 mm of the medial tibial eminence is removed. If the implant is suitable and there is no medial tibial overhang, then the central bone-bridge technique may be used. If the implant needs to be adjusted to fit to the me-

dial tibial plateau by moving the anterior horn farther laterally, then the two-tunnel technique is selected. Once the technique has been chosen, the meniscal allograft is prepared.

#### Central Bone-Bridge Technique

The central bone-bridge technique for medial meniscal transplantation is the same as that described for lateral meniscal transplantation. A reference slot is first created on the tibial plateau in the anteroposterior direction. A guide pin is positioned in the slot, inferiorly on the tibia, and a cannulated drill bit is placed over the pin to drill a tunnel. The final tibial slot is 8 to 9 mm in width and 10 mm in depth. A

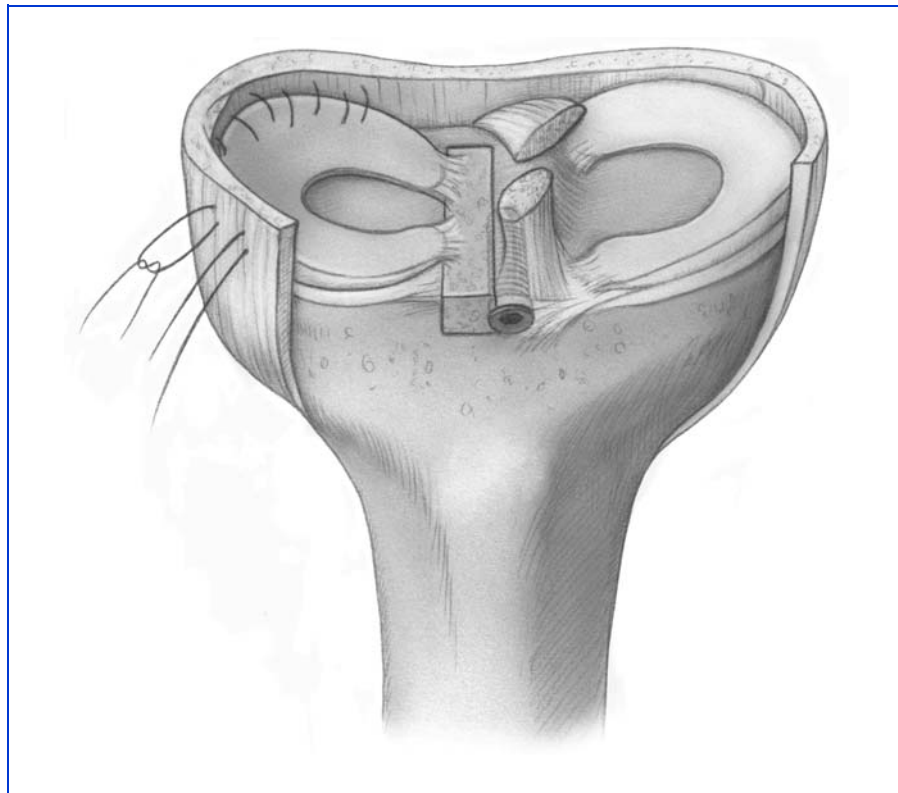


FIG. 5

Lateral meniscal graft in place and sutured.

#### CRITICAL CONCEPTS | continued

transplant would rest outside of the medial tibial plateau in order to avoid compromising the attachment of the anterior cruciate ligament. The two-tunnel technique is selected to obtain correct anatomic positioning and the desired subsequent circumferential hoop stress.

- The use of multiple vertical divergent sutures is required to position the transplant in the anatomically correct manner. There are usually wavy areas in the implant, with loss of circumferential tension, that are successfully removed by correct placement of these sutures.
- We prefer the inside-out meniscal repair technique, which is considered to be the most precise suturing method.
- We avoid meniscal fixators, with which it is not possible to provide the same secure fit and exact placement of the implant.
- The sutures should not be placed in the middle and inner thirds of the meniscus, as this could weaken the implant.
- The suturing of the implant is meticulous, as twelve to fifteen sutures are required both superiorly and inferiorly, all placed in a vertical direction. Horizontal sutures have poor holding ability and are therefore not used during meniscal transplantation.
- Care is taken not to damage the articular cartilage. The technique requires two surgical assistants, one dedicated to holding the lower limb to open the medial or lateral tibiofemoral compartment for visualization of the implant and the other seated to retrieve and tie the sutures at the posterior aspect of the joint.

*continued*

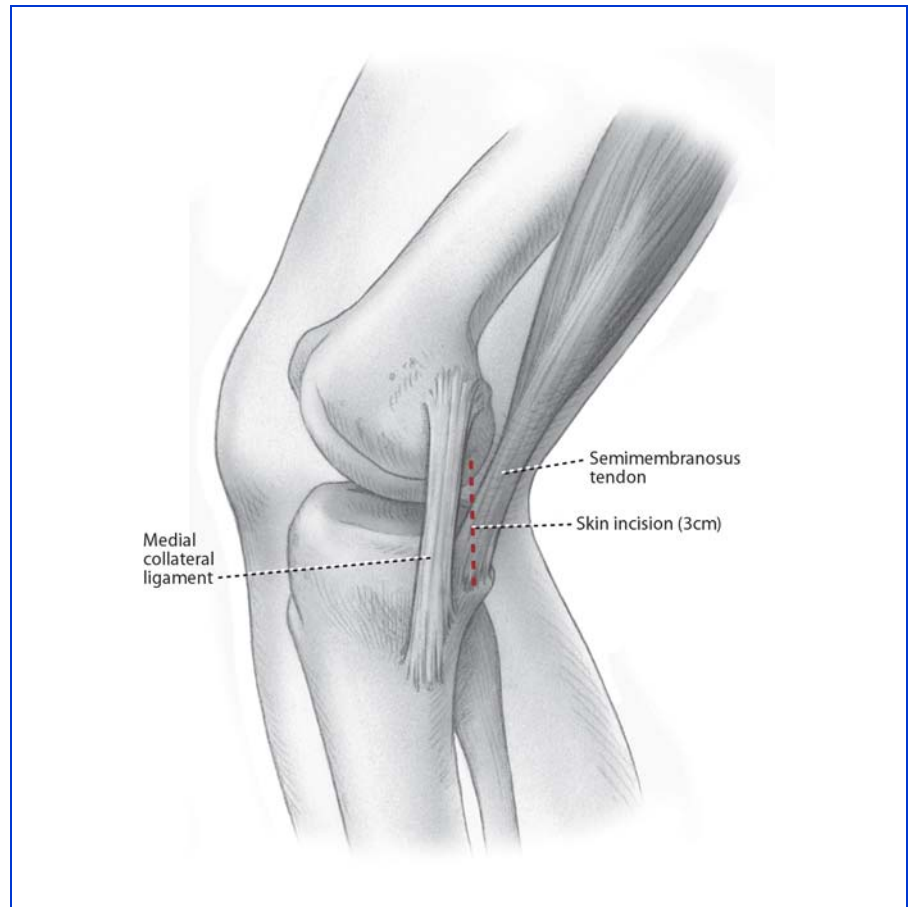
**CRITICAL CONCEPTS** | continued

- The suturing of the medial or lateral posterior horn adjacent to the posterior attachment requires angulation of the suture needle away from the neurovascular structures.
- In order for the meniscal transplant to function, it must be placed at the normal anatomic insertion sites. If the posterior horn attachment of the medial or lateral meniscus is placed too far posteriorly, it will not provide proper load-sharing<sup>13</sup>. Alternatively, a too anterior position of a medial meniscal transplant will produce excessive compressive forces and damage the meniscus.
- We disagree with those who have advocated techniques of medial meniscal transplantation in which the posterior bone portion of a medial meniscal implant is not retained and the fibrocartilaginous posterior horn is placed in a posterior tibial attachment tunnel. Although such transplants are far easier to prepare and implant surgically, there are inadequate scientific data to support the belief that the soft-tissue ends of the meniscal implant (without the bone attachment) will heal and provide the circumferential tension in the meniscus that is required for function.

continued

rasp is used to smooth the slot to allow insertion of the central bone bridge of the allograft.

The central bone bridge of the allograft is sized to a width of 7 mm (1 mm less than the dimension at the tibial site) and a depth of 10 mm<sup>9</sup>. This allows the

**FIG. 6-A**

**Figs. 6-A, 6-B, and 6-C** The accessory posteromedial approach for a medial meniscal allograft procedure. **Fig. 6-A** Site of the posteromedial skin incision.

position of the central bone bridge to be adjusted in the anterior-posterior direction while the meniscus is positioned to fit in the anatomically correct position relative to the femoral condyle.

A vertical suture is placed through the junction of the posterior and middle thirds of the meniscus. A single-barrel cannula is used to advance the suture through the capsule at the corresponding attachment site of the meniscus, and the suture exits through an accessory incision (Fig. 7). The meniscus

is passed through the arthrotomy incision into the knee, with tension placed on the sutures to facilitate proper positioning in the knee joint. Care is taken to align the bone bridge with the recipient tibial slot. The knee is taken through flexion and extension and tibial rotation to align the implant. Once the appropriate anterior-posterior position of the central bone bridge is achieved, a guide wire is inserted between the bone bridge and the lateral side of the slot. A tap is inserted over the guide wire to create a

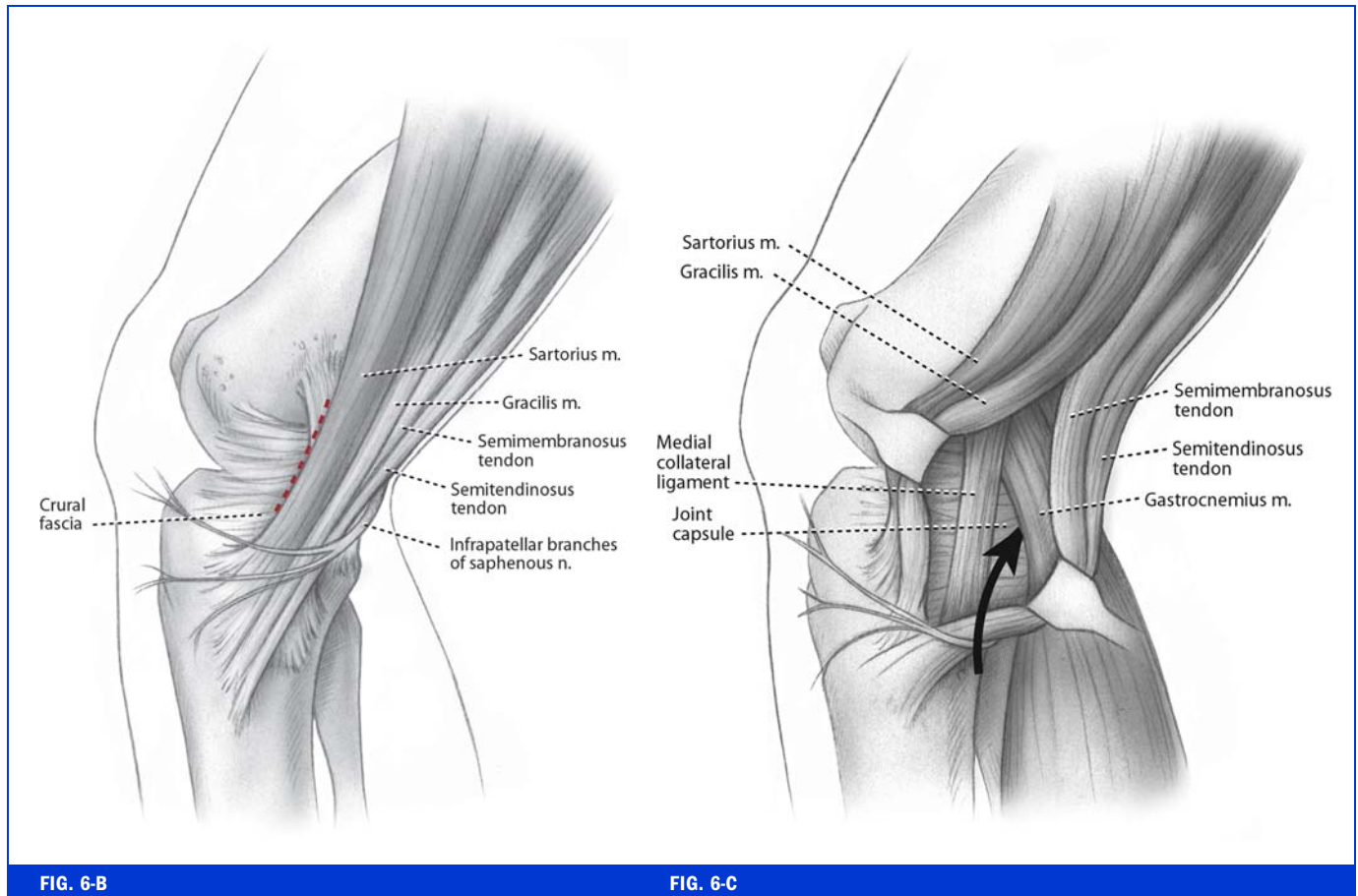


FIG. 6-B

FIG. 6-C

**Fig. 6-B** The incision is shown through the anterior portion of the sartorius fascia. **Fig. 6-C** The interval is opened between the posteromedial aspect of the capsule and the gastrocnemius tendon, just proximal to the semimembranosus tendon (arrow). The fascia over the tendon is excised to its tibial attachment to facilitate retrieval of the meniscal sutures.

path for an interference screw with the bone bridge held in place manually. An absorbable bone interference screw is inserted adjacent to the bone bridge.

The joint is again taken through a full range of motion, and the position of the implant is verified. Occasionally, there is an osteophyte on the anterior aspect of the medial tibial plateau, and this must be resected to avoid compression of the meniscal implant. The central bone bridge of the implant is fixed with an interference screw

(7 × 25 mm). The meniscus is sutured with vertical divergent sutures (2-0 Ethibond) under direct visualization. The anterior arthrotomy is closed, and the inside-out vertical divergent sutures are placed, as described, to sew the meniscus to the meniscal bed, with removal of any implant undulations and restoration of circumferential meniscal tension. The central bone bridge of the implant provides fixation of the anterior and posterior portions of the implant and healing into the host tibia (Fig. 8).

#### Two-Tunnel Technique

If it is determined that the central bone-bridge technique is not acceptable, the surgeon must prepare separate anterior and posterior bone portions of the meniscal transplant. Both are secured to anatomic attachment sites to provide a functional meniscal implant (Fig. 9). The transplant is prepared with a posterior bone plug, 8 mm in diameter and 12 mm in length, and an anterior bone plug, 12 mm in diameter and 12 mm in length. Two 2-0 nonabsorbable Ethibond sutures are passed ret-

**CRITICAL CONCEPTS** | continued**AUTHOR UPDATE:**

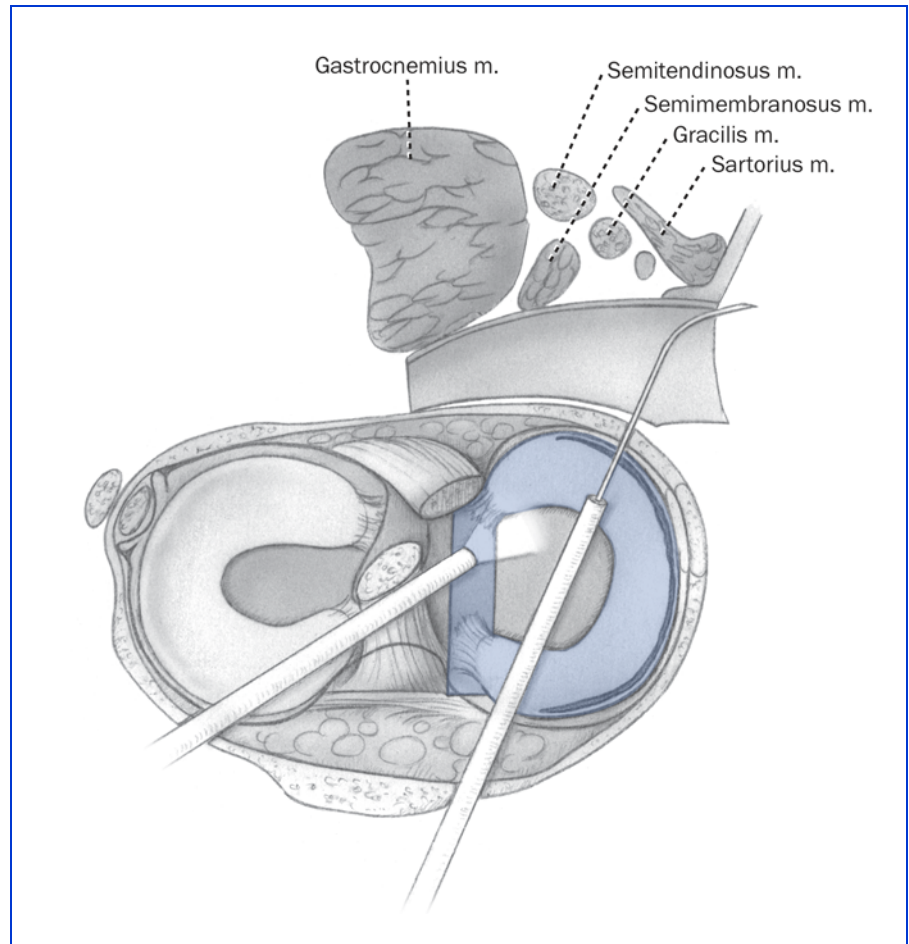
In our original study, we used the central bone-bridge technique, which maintains a central bone bridge between the anterior and posterior meniscal attachments, primarily for lateral meniscal transplantation. This is also now our preferred technique for medial meniscal transplantation, as described in this article.

Currently, we use a template of the meniscal implant to determine the location of the bone slot. The lateralmost placement of the central bone slot for the medial meniscal implant is limited by the tibial attachment of the anterior cruciate ligament. The anterior horn of the medial meniscus must not be of a Type-III configuration<sup>5</sup>—i.e., it must not insert too far distally on the anterior tibial margin. If assessment of the medial meniscal transplant reveals a medial-to-lateral size mismatch, then separate anterior and posterior bone attachments and tunnels are required. The posterior part of the bone-meniscus transplant is placed at the normal attachment, and the anterior horn is placed in a medial-to-lateral direction to restore correct tensioning and position in the joint.

*continued*

rograde through each bone plug, with two additional locking sutures placed in the meniscus adjacent to the bone attachment for subsequent secure fixation of the bone plugs within the tibial tunnel.

A guide pin is placed adjacent to the tibial tubercle and is directed to the anatomic posterior



**FIG. 7**

Cross section showing the arthroscope, needle cannula, and popliteal retractor in place. The meniscus is passed through the arthrotomy incision into the knee with tension placed on the sutures to facilitate proper positioning in the knee joint. With use of a single-barrel cannula, the suture is advanced through the capsule at the corresponding attachment site of the meniscus and exits through an accessory incision.

meniscal attachment. A tibial tunnel is drilled over the guide wire to a diameter of 8 mm. The bone-tunnel edges are chamfered. A limited notchplasty of the medial femoral condyle is usually required. At least 8 mm of opening adjacent to the posterior cruciate ligament in the femoral notch is needed to pass the posterior osseous portion of the graft. On occasion, a subperiosteal release of the long fibers of the tibial attach-

ment of the medial collateral ligament (with later suture-anchor repair) is required to open the medial part of the tibiofemoral joint sufficiently. The meniscal bed is prepared by removing any remaining meniscal tissue while preserving a 3-mm rim when possible. The meniscal bed is rasped for revascularization of the graft.

A 3-cm anteromedial arthrotomy is used to pass the pos-

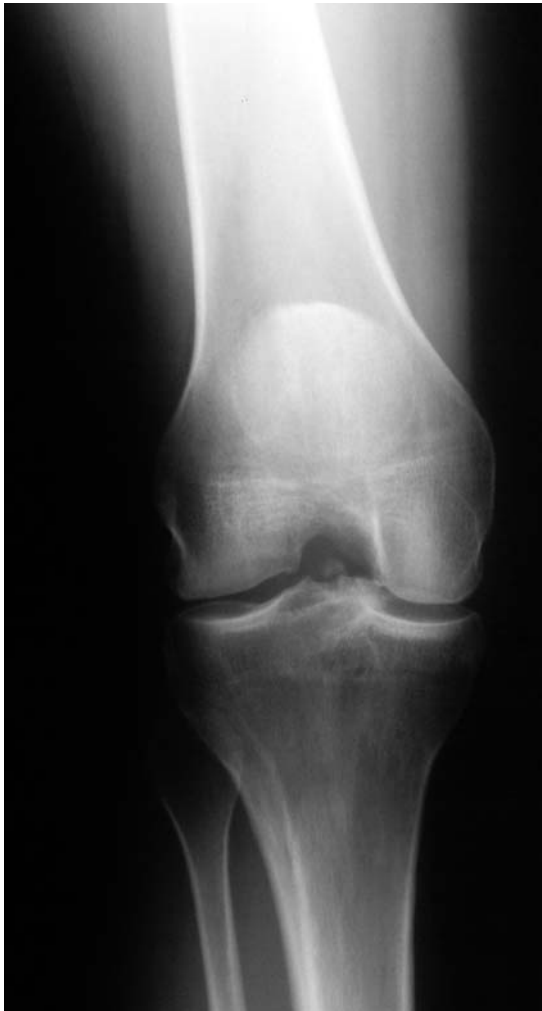

FIG. 8

Weight-bearing posteroanterior radiograph of a thirty-six-year-old woman, made six years after medial meniscal transplantation with a central bone-bridge technique, showing incorporation of the bone bridge into the host with preservation of the medial joint space.

terior bone portion of the graft, with a secondary meniscal body suture passed out through the incision for the posteromedial approach. The surgeon is seated with a headlight in place, and the patient's knee is flexed to 90°. On occasion, there are anterior osteophytes on the medial tibial plateau that require resection. The posterior attachment guide wire is retrieved, and the sutures

attached to the posterior bone are passed. A second suture is placed into the midportion of the meniscus and is passed inside-out through the incision for the posteromedial approach to guide the meniscus.

The knee is flexed to 20° under a maximum valgus load to pass the posterior bone portions of the graft, with the secondary meniscal body suture held by an

### CRITICAL CONCEPTS | continued

For tight knees with only a few millimeters of medial joint opening, the central bone-bridge technique enables the surgeon to avoid performing a partial detachment of the distal part of the medial collateral ligament, which would otherwise be required to gain access to the joint for suturing and to avoid damage to the articular cartilage.

There are now newer techniques for tissue-processing and advanced donor-screening tests that provide highly safe meniscal transplants with an exceedingly low risk of disease transmission. Advances in tissue-processing and Food and Drug Administration guidelines for tissue banks are important to ensure the safety of allografts.

assistant. A nerve hook is used to gently assist the passage of the graft. With use of a headlight and retractors, it is possible to confirm appropriate passage of the meniscal graft into the medial tibiofemoral compartment. Care is taken to not advance the posterior part of the meniscal body into the tibial tunnel but to only seat the bone portion of the graft in order to avoid shortening of the meniscal graft. The posterior meniscal bone attachment and the midbody sutures are tied over the tibial post to provide tension in the posterior bone attachment and the posterior one-third of the meniscus. The knee is flexed and extended to assess meniscal fit and displacement. The optimal location for the an-



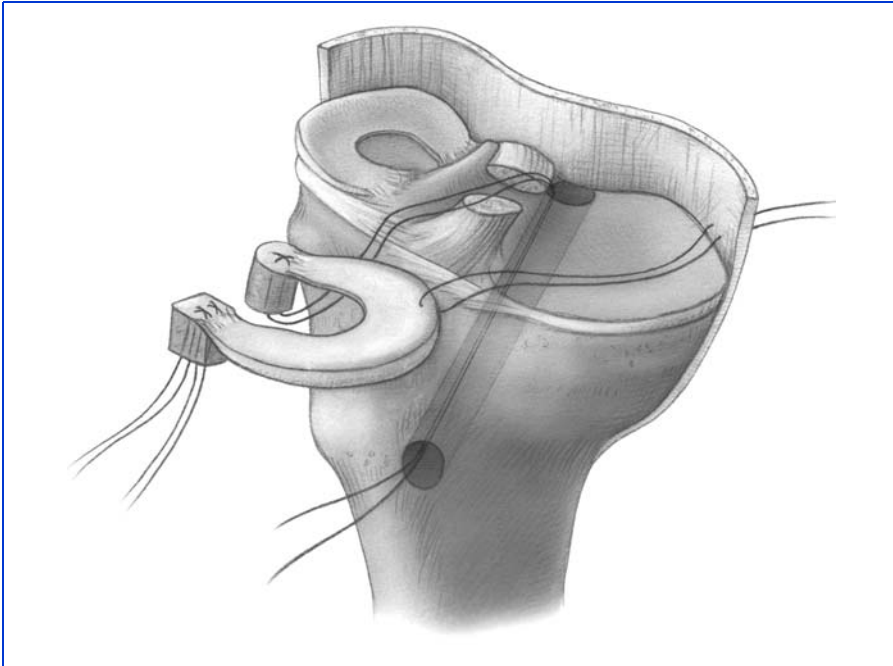


FIG. 9

Two-tunnel technique for medial meniscal allograft transplantation. The illustration shows insertion of the transplant, including posteromedial suture placed to facilitate meniscal reduction. The anterior and posterior bone attachments of the medial meniscal transplant are fixed into separate tibial tunnels.

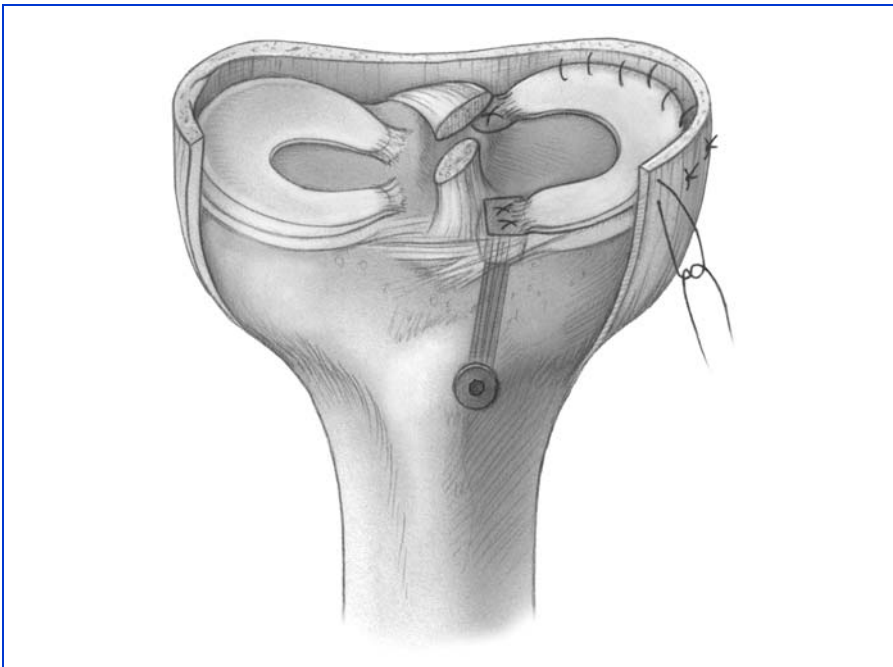


FIG. 10

Appearance of the final fixation of the medial meniscal transplant in the anterior and posterior tunnels and vertical divergent sutures.

terior meniscal bone attachment at the anteromedial junction of the tibial plateau is identified, with the medial-to-lateral placement in the coronal plane determined with the knee in full extension. A 12-mm rectangular bone attachment is fashioned to correspond to the anterior bone portion of the meniscal graft. A 4-mm bone tunnel is placed at the base of this bone trough, and it exits at the anterior aspect of the tibia just proximal to the posterior bone tunnel. The sutures are passed through the bone tunnel, and the anterior horn is seated. Full knee flexion and extension are again performed to determine proper graft placement and fit. Tension is applied to the anterior bone sutures, which are not tied at this point but are used to maintain tension in the graft during the inside-out suture repair. This meticulous seating of the meniscal transplant under circumferential tension with bone attachment of both the anterior and the posterior horn is believed to be crucial for future meniscal weight-bearing position and function.

The anterior arthrotomy is closed, and the arthroscope is inserted into the anterolateral portal for the posterior meniscal repair and into the anteromedial portal for the repairs of the middle and anterior one-thirds, with the single needle cannula inserted in the other anterior portal. The meniscal repair is performed in an inside-out fashion, starting with the posterior horn, with use of multiple verti-

cal divergent sutures of 2-0 non-absorbable Ethibond both superiorly and inferiorly, with constant tensioning of the meniscus from posterior to anterior to establish circumferential tension. The assistant, seated with a headlight, retrieves the suture needles through the posteromedial approach. Each suture is placed and tied, bringing the meniscus directly to the meniscal bed with observation that meniscal placement, fixation, and tension are correct. The anterior arthrotomy incision is again opened, and the final tensioning and tying of the anterior horn bone sutures are performed with use of the anterior tibial post. Occasionally, additional sutures are required to secure the most anterior one-third of the meniscus to the capsular attachments, which is done under direct vision (Fig. 10). After final inspection of the graft with knee flexion and extension and tibial rotation, the operative wounds are closed in a routine fashion.

Frank R. Noyes, MD  
Sue D. Barber-Westin, BS  
Marc Rankin, MD  
Deaconess Hospital, 311 Straight Street, Cincin-

nati, OH 45219. E-mail address for S.D. Barber-Westin: sbwestin@csmref.org

The authors did not receive grants or outside funding in support of their research or preparation of this manuscript. They did not receive payments or other benefits or a commitment or agreement to provide such benefits from a commercial entity. No commercial entity paid or directed, or agreed to pay or direct, any benefits to any research fund, foundation, educational institution, or other charitable or nonprofit organization with which the authors are affiliated or associated.

The line drawings in this article are the work of Joanne Haderer Müller of Haderer & Müller (biomedart@haderermuller.com).

doi:10.2106/JBJS.E.00347

## REFERENCES

- Pollard ME, Kang Q, Berg EE. Radiographic sizing for meniscal transplantation. *Arthroscopy*. 1995;11:684-7.
- Cole BJ, Carter TR, Rodeo SA. Allograft menisca transplantation: background, techniques, and results. *J Bone Joint Surg Am*. 2002;84:1236-50.
- Barbour SA, King W. The safe and effective use of allograft tissue—an update. *Am J Sports Med*. 2003;31:791-7.
- Vangsness CT Jr, Garcia IA, Mills CR, Kainer MA, Roberts MR, Moore TM. Allograft transplantation in the knee: tissue regulation, procurement, processing, and sterilization. *Am J Sports Med*. 2003;31:474-81.
- Berlet GC, Fowler PJ. The anterior horn of the medial meniscus. An anatomic study of its insertion. *Am J Sports Med*. 1998;26:540-3.
- Rubman MH, Noyes FR, Barber-Westin SD. Technical considerations in the management of complex meniscus tears. *Clin Sports Med*. 1996;15:511-30.
- Noyes FR, Barber-Westin SD. A comparison of results in acute and chronic anterior cruciate ligament ruptures of arthroscopically assisted autogenous patellar tendon reconstruction. *Am J Sports Med*. 1997;25:460-71.
- McLaughlin JR, Noyes FR. Arthroscopic meniscus repair: recommended surgical techniques for complex meniscal tears. *Tech Orthop*. 1993;8:129-36.
- Farr J, Meneghini RM, Cole BJ. Allograft interference screw fixation in meniscus transplantation. *Arthroscopy*. 2004;20:322-7.
- Rosenberg TD, Paulos LE, Parker RD, Coward DB, Scott SM. The forty-five-degree posteroanterior flexion weight-bearing radiograph of the knee. *J Bone Joint Surg Am*. 1988;70:1479-83.
- Noyes FR, Barber-Westin SD, Butler DL, Wilkins RM. The role of allografts in repair and reconstruction of knee joint ligaments and menisci. *Instr Course Lect*. 1998;47:379-96.
- Dugdale TW, Noyes FR, Styer D. Preoperative planning for high tibial osteotomy. The effect of lateral tibiofemoral separation and tibiofemoral length. *Clin Orthop Relat Res*. 1992;274:248-64.
- Alhalki MM, Hull ML, Howell SM. Contact mechanics of the medial tibial plateau after implantation of a medial meniscal allograft. A human cadaveric study. *Am J Sports Med*. 2000;28:370-6.
- Farr J, Cole B. Slot instruments for meniscal transplantation: surgical technique. San Jose, CA: Stryker Endoscopy; 2004.
- Halbrecht JL. Meniscal reconstruction trough surgical technique. Kennesaw, GA: CryoLife; 2000.