



# Osteochondritis dissecans of the knee in children and adolescents

Cecilia Pascual-Garrido<sup>a</sup>, Cathal J. Moran<sup>a</sup>, Daniel W. Green<sup>b</sup>, and Brian J. Cole<sup>c</sup>

## Purpose of review

Osteochondritis dissecans (OCD) of the knee is a well-described condition that can cause significant morbidity in children and adolescents; timely diagnosis is key to preventing compromise to the articular cartilage and maximizing opportunity to perform a restorative procedure. Juvenile OCD has a better prognosis than does adult OCD, with higher rates of spontaneous healing with conservative treatment. Still, there are certain indications for surgical restoration procedures. Controversies arise over when to decide surgical procedure and what is the best surgical treatment option in this young population.

## Recent findings

Some authors believe nonoperative management should be the first-line treatment for stable OCD lesions in children. The only consensus in regard to this modality is that, if a patient is truly asymptomatic or experiencing low-level symptoms, then the duration of nonoperative treatment should be at least 3–6 months before opting for operative treatment. In the case of failed nonsurgical management or in the setting of an unstable fragment, surgical intervention should be implemented. Recent published data suggest no difference in clinical or radiographic outcome when comparing different surgical techniques.

## Summary

OCD of the knee requires a timely diagnosis to maximize opportunity to perform a reparative procedure. Indications for surgical treatment are based on lesion stability, skeletal maturity, and clinical symptoms. Reestablishing the joint surface, improving the blood supply of the fragment, rigid fixation, and early motion are primary goals for osteochondral fragment preservation. When the fragment is not suitable for preservation, careful consideration of defect location and the patient's clinical presentation will determine when cartilage restoration procedures should be utilized.

## Keywords

cartilage, juvenile osteochondritis dissecans, knee

## INTRODUCTION

Osteochondritis dissecans (OCD) is a pathological condition that results in destruction of subchondral bone with secondary damage to overlying articular cartilage. OCD is classically divided into juvenile and adult forms on the basis of the patient's skeletal maturity [1]. Juvenile OCD (JOCD) occurs in children and adolescents with open growth plates. JOCD has a much better prognosis than does adult OCD (AOCD), with higher rates of spontaneous healing with nonoperative treatment [2–5]. However, despite the differences in prognosis based on age, many authors believe that JOCD and AOCD reflect the same pathologic processes and are merely discovered at different points of skeletal maturity [6]. The highest incidence of JOCD is amongst patients between 10 and 15 years old, resulting in

its being one of the most common causes of knee pain and dysfunction in young adults [3]. JOCD may also present as an incidental radiographic finding on investigation of another unrelated injury or it may represent a primary presentation with clinically

<sup>a</sup>Sports Medicine and Shoulder Service, Hospital for Special Surgery, <sup>b</sup>Pediatric Orthopedic Surgery Service, Hospital for Special Surgery, New York, New York and <sup>c</sup>Division of Sports Medicine, Director, Section of Cartilage Restoration at Rush, Cartilage Restoration Center, Rush University Medical Center, Chicago, Illinois, USA

Correspondence to Cecilia Pascual-Garrido, J F Segui 4751 1 E, Capital Federal, Buenos Aires, (1425), Argentina. Tel: +530 318 4244; e-mail: Cecilia.pascualgarrido@gmail.com

**Curr Opin Pediatr** 2013, 25:46–51

DOI:10.1097/MOP.0b013e32835adbf5

## KEY POINTS

- OCD of the knee is a well-described condition that can cause significant morbidity in children and adolescents; timely diagnosis is key to preventing compromise to the articular cartilage.
- In those symptomatic patients with an unstable OCD fragment or loose body, surgical treatment should be attempted as a first-line treatment option. Whenever possible, preservation of the OCD fragment should be attempted.
- No consensus has been established for which cartilage restoration technique leads to the best outcomes. Our experience suggests that loose body removal may be considered as a first-line treatment option with good pain relief in most patients.

nonspecific activity-related knee pain with or without a notable history of trauma [6,7<sup>\*\*\*</sup>].

## IMAGING

Plain radiographs (anterior–posterior, lateral, tunnel, and skyline views) are recommended in patients suspected to have JOCD. Characteristic findings include a well-circumscribed area of subchondral bone separated by a crescent-shaped sclerotic radiolucent outline of the fragment. Given the difficulty of establishing the stability of an OCD lesion or integrity of articular cartilage on plain radiograph, however, MRI has become the gold standard for imaging these lesions. Furthermore, the role of MRI in imaging the knee following surgical intervention, in addition to detailing the primary lesion, is likely to grow. Novel cartilage image techniques discussed in the literature include dGEMRIC (delayed gadolinium-enhanced MRI of cartilage), sodium 23 imaging, T2\*, T1rho, and T2 mapping. In broad terms, dGEMRIC, sodium, and T1rho are considered to be sensitive to proteoglycan content, whereas measurement of T2 or T2\* relaxation times is sensitive to collagen architecture, specifically collagen orientation. T1rho has been shown to be effective in detecting early cartilage degeneration at clinical field strengths as well as in determining progress in cartilage repair following intervention. T2 mapping has been shown to demonstrate alterations in zonal stratification, and areas of early degenerative change even before changes can be detected on traditional MRI sequences or radiographs. As these options are used in cases of OCD, it is possible that we will be able to better identify those patients who warrant early intervention.

## MANAGEMENT

Surgical and nonsurgical options play a role in the management of JOCD, with nonsurgical management chosen as an option when the OCD lesion is regarded as stable and the patient is asymptomatic. Although immobilization and weight-bearing limitations have been applied in the past, published studies have shown that prolonged immobilization can be detrimental to the health of the knee joint [8]. Current nonsurgical management should instead focus on a hiatus from sporting and high-impact activities for a course of 6–8 weeks with allowance for normal weight-bearing in a compliant patient. The likelihood that the lesion will heal with this management is approximately 50% at 10–18 months and is inversely related to the patient's age [9]. A large multicenter review of the European Pediatric Orthopedic Society study (509 knees, 318 juvenile and 191 adult, in 452 patients) suggests an improved prognosis with conservative treatment in young patients with no signs of dissection, effusion, a small lesion (less than 2 cm<sup>2</sup>), and classical location (lateral aspect of the medial femoral condyle). In cases of an unstable lesion (chondral separation), surgical results are better than those with nonsurgical treatments [10]. Surgical intervention includes fragment removal, drilling (antegrade or retrograde), internal fixation, marrow stimulation, autologous chondrocyte implantation (ACI), or osteochondral autograft/allograft transplantation to repair the lesion or supplement the area of cartilage loss. The American Academy of Orthopaedic Surgeons recently published clinical practice guidelines for OCD in skeletally immature patients with salvageable unstable or displaced OCD lesions [9]. However, there was no consensus in terms of being able to recommend for or against specific cartilage repair techniques. The major concern with OCD remains whether the primary lesion or lesion following resection of a loose component will progress to early osteoarthritis if no further intervention is performed. Unique to OCD is the fact that many patients can be asymptomatic and unaware of the disorder until the fragment becomes destabilized based on the endogenous natural history of that lesion or through acute or repetitive trauma. Linden performed a long-term retrospective follow-up study of patients with JOCD of the femoral condyles with an average follow-up of 33 years after initial diagnosis and found that patients with JOCD diagnosed have no increased risk of osteoarthritis later in life when compared with the normal population [11]. In contrast, Twyman *et al.* [12] completed a prospective follow-up of 22 knees with juvenile OCD into middle age and found 50% had some

radiographic signs of osteoarthritis. Furthermore, although many patients may initially feel asymptomatic following excision of an unstable fragment, Lim *et al.* [13\*] recently published a 14-year follow-up of such patients and demonstrated a high incidence of radiological evidence of degenerative change. There is an urgent need for randomized controlled trials (RCTs) to evaluate nonsurgical versus well-defined surgical intervention in JOCD. Furthermore, investigations related to how secondary cartilage restoration procedures may otherwise change the natural history of OCD will need to be considered. In the next section, we outline some of the cartilage repair procedures, which may facilitate improved outcomes.

## SURGICAL OPTIONS

Surgical options could be reparative or restorative procedures.

### Reparative treatments

The goal of reparative procedures is to restore the integrity of the native subchondral interface and preserve the overlying articular cartilage. At the present time, methodologies such as drilling or internal fixation are indicated for the symptomatic juvenile patient who has failed a course (generally 6 months) of nonoperative management. These procedures provide clinical relief in a majority of patients and leave many viable options for revision in the case of inadequate symptomatic relief. We believe that preserving the fragment should always be attempted when possible.

### Drilling

Treatment to enhance fragment healing is based on the creation of vascular channels to the devitalized region. Drilling is generally limited to low-grade lesions – intact or minimal signs of separation (Guhl grade I and II, respectively) in young patients with open physes. Flap detachment or loose bodies must be addressed through fixation or replacement, although drilling may be an adjuvant to improve the blood supply to the repair. Both anterograde and retrograde approaches to the region of separation have been described.

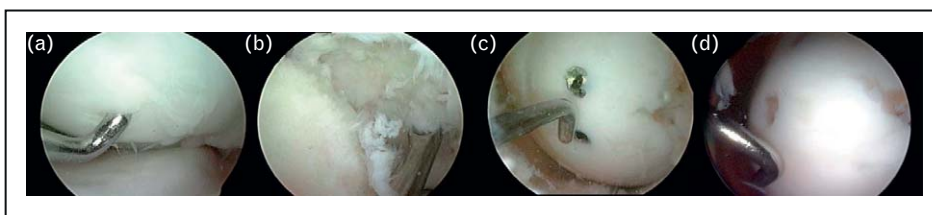
Outcomes of OCD drilling are generally favorable, with patient age being the most prognostic factor. Individuals with OCD diagnosed and treated with drilling as an adult have decreased radiologic healing and less favorable symptomatic outcomes. Boughanem *et al.* [14] recently published a retrospective study of JOCD treated with retrograde

drilling. At time of surgery, all lesions were stable. At 4 years' follow-up, significant improvement in clinical outcomes was observed. Ninety-four percent of the patients reported they would repeat the surgery if having the option again. Edmonds and Polousky reported the outcomes in 59 patients who were treated with retrograde drilling for JOCD of the knee. All patients presented with grade I–II OCD lesion, which did not improve after 4–6 months of nonoperative treatment. Mean follow-up was 36 months. The mean percentage of healing at final follow-up for all OCD lesions was 98.2%. There was a significant difference in the rate of healing ( $P=0.038$ ) between small and large lesions. Small lesions healed in an average of 3.6 months ( $\pm 3.4$  months) versus large lesions that healed at an average 15.3 months ( $\pm 9.9$  months) [15]. It is our opinion that the ideal patient with symptomatic JOCD for treatment with drilling is a relatively young patient with a defect with classic OCD that is grossly stable to palpation despite MRI evidence of fluid behind the fragment (an indicator of early biologic and mechanical instability).

### Internal fixation

High-grade OCD lesions with articular cartilage flaps or loose bodies (Guhl grades III and IV, respectively) are generally not amenable to conservative treatment. Reattachment of partially detached lesions or loose bodies is appropriate for large fragments containing sufficient subchondral bone to provide union and support of the fixation system. With all types of fixation, the bed of the defect should be prepared to optimize healing. In the setting of a flap, the fragment can be hinged open and the bed can be cleared of fibrocartilaginous scar using a curette with microfracture of the bed to restore vascular channels. All devices should be recessed beneath the cartilage surface, with metal screws being removed postoperatively when evidence of union is seen typically 6–8 weeks later (Fig. 1). Return to sports following hardware removal is often delayed an additional 8–12 weeks, depending upon the fragment size and weight-bearing location.

Favorable outcomes after internal fixation of OCD fragments have been reported for both metallic and bioabsorbable devices [16,17] (Figs 2 and 3). Interestingly, it has been shown that these fragments remain viable once they are detached, suggesting ORIF should be performed whenever possible [17,18], resulting in stable union in 92% of the cases. Long-term follow-up demonstrated that patients were able to function at a nearly normal level in activities of daily living without significant pain or knee symptoms [19]. Tabaddor *et al.* [20]



**FIGURE 1.** Intraoperative, arthroscopic view of a loose body secondary to OCD disease (a). All the calcified layer was removed completely (b). The microfracture holes normally began at the periphery of the lesion adjacent to the stable cartilage rim and continued to the center (c). Second-look arthroscopy at 6 months postoperative for screw removal (d).

recently evaluated the outcomes of ORIF of JOCD lesions with Poly 96L/4D lactide copolymer. At a mean follow-up of 22 months, MRI showed interval healing in 16 of 17 knees. Good to excellent results were evident in 91% of the cases. Two patients presented synovitis that resolved spontaneously.

### Restorative

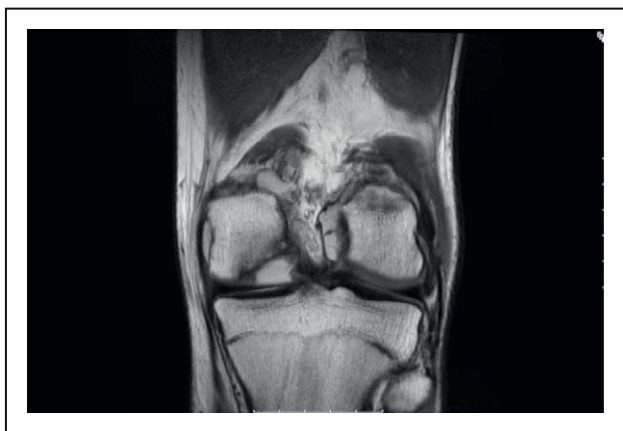In the event that the fragment cannot be stabilized and requires excision, or fails to heal after initial fixation, a different approach is required. This may be viewed as restoration, rather than repair, and is a form of intervention that may be undertaken earlier and in more cases as both RCT evidence and MRI information become more clear.

### Microfracture

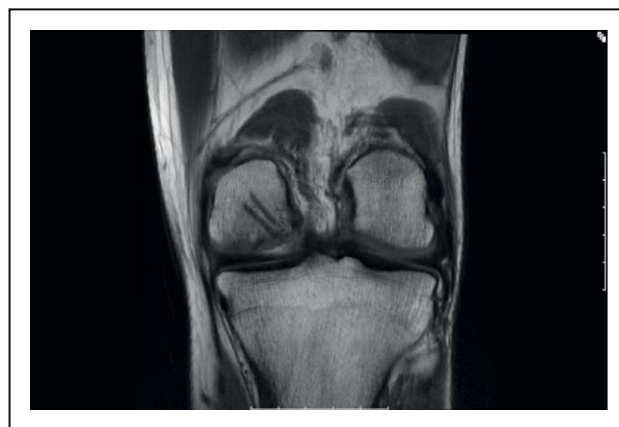Where restorative intervention is indicated, we believe that microfracture offers a valid option. Knutsen *et al.* [21] randomized femoral condyle (28% with OCD lesions) cartilage defects to treatment with microfracture or ACI. Both groups

demonstrated satisfactory results in 77% of the patients at 5 years, with younger patients reporting better outcomes. Overall, microfracture should be considered as a first-line treatment, especially in the setting of fragment removal in small, shallow defects. Gudas *et al.* [22] recently published a randomized clinical study comparing osteoarticular transfer system (OATS) versus microfracture for OCD lesions in children. At 4 years' follow-up, 83% of patients treated with OATS showed good to excellent results. In contrast, those patients treated with microfracture showed good results at 1 year but deteriorated with time. Duration of the symptoms prior to surgery and lesion more than 2 cm<sup>2</sup> were associated with worst outcomes in the microfracture group. It is important to interpret the literature in the context of when restorative first-line treatment is provided. For example, treating the defect bed at the time of fragment removal is confounded by the fact that many patients are initially responding favorably to fragment removal rather than to the biologic treatment of the defect bed.

Several concepts must be considered during the decision-making process before recommending a microfracture procedure. Our decision to



**FIGURE 2.** 18-year-old man with osteochondritis dissecans of the knee. Typical osteochondritis dissecans location on the lateral aspect of the medial femoral condyle. Note the high signal at the interface with cartilage and bone suggesting loosening.



**FIGURE 3.** A 1-year follow-up after ORIF with bioabsorbable tacks. Osteochondritis dissecans lesion completely healed.

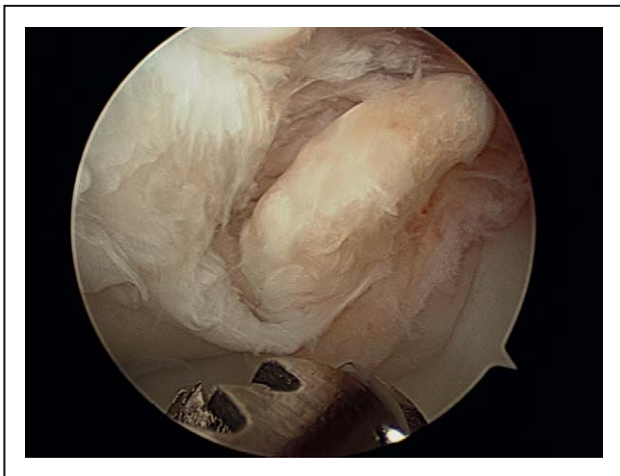

microfracture the patient undergoing fragment removal is highly individualized, with considerations of defect location, defect containment, the condition of the bone, and the size and depth of the lesion. Given the rehabilitation required following microfracture, the decision is not taken lightly. Even beyond the initial period of protected weight bearing and continuous passive motion, if one truly follows the existing recommendations about return to sport for these patients, they would not be allowed to return to high-level activities for at least 6–8 months. Thus, it can be challenging to hold an active patient back when all that might have been required was fragment removal to render them symptom free.

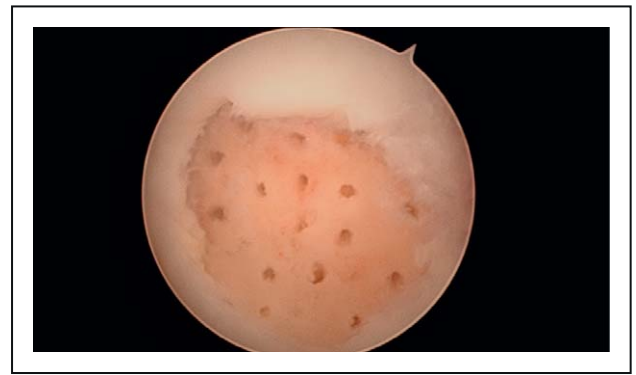We only microfracture the bed (of a recently removed fragment) if it includes the ideal defect characteristics, assuming the patient understands and consents to the postoperative program (Figs 4 and 5). Although this decision-making is somewhat intuitive, it is not supported by any literature that demonstrates that, with this exact clinical scenario, the symptoms will be reduced further than fragment removal alone, that symptom onset will be prevented or delayed, or that the natural history of the defect will be altered in any way.

### Osteoarticular transfer system

This technique is ideal in those case scenarios wherein the underlying subchondral bone integrity has been significantly compromised. It could be considered as a second-line treatment after a failed microfracture or as a first-line treatment of high-demand patients with small chondral lesions. A novel technique of using an osteochondral autograft plug as a biologic splint has been reported by



**FIGURE 4.** Typical osteochondritis dissecans lesion located on the medial femoral condyle with loose body.



**FIGURE 5.** After fragment removal, microfracture was performed. Note the lesion is ideal for microfracture, with chondral defect with good cartilage shoulders.

Miniaci and Tytherleigh-Strong [23] and remains a consideration for a defect that has an intact, relatively stable fragment within the defect bed. Gudas *et al.* [22] reported a prospective, randomized study comparing microfracture with osteochondral autologous transplantation in OCD and found that both groups demonstrated substantial improvement initially in clinical symptoms and in their International Cartilage Repair Society scores, but the microfracture group deteriorated over time, with 41% failing (based on pain and joint swelling necessitating a second-look surgery) at 4 years compared with none in the transplant group.

### Autologous chondrocyte implantation

Autologous chondrocyte transplantation may be a good choice for large defects. Bentley *et al.* [24] reported good to excellent outcomes in 88% of the cohort from a large patient population undergoing ACI for OCD lesions [24]. Kon *et al.* [25] recently published second-generation ACI, together with a bone graft in patients with OCD. Interestingly, female sex and older age were related to the worst prognosis.

### Osteochondral allograft

Osteochondral allograft transplantation should be considered as a salvage procedure and should rarely be used as first-line treatment. Garrett [26] reported successful outcomes at a mean follow-up of 3 years in 94% of the patients. McCulloch *et al.* [27] studied the clinical outcomes in 25 patients who underwent prolonged fresh osteochondral allograft (these grafts are harvested and are typically maintained refrigerated at 4°C for up to 28 days). Six of these patients were diagnosed with OCD. They reported 84% patient satisfaction and 88% radiographic incorporation of prolonged fresh allografts to the

femoral condyle. Recently, a study published by Kon *et al.* [25<sup>■</sup>] suggests osteochondral allograft to be a good surgical option in patients with larger and deeper OCD lesions.

## CONCLUSION

OCD of the knee is a well-described condition that can cause significant morbidity in children and adolescents; timely diagnosis is key to preventing compromise to the articular cartilage. Symptomatic OCD lesions should be initially treated non-surgically with hiatus from sporting and high-impact activities for a course of 6–8 weeks. In those symptomatic patients with an unstable OCD fragment or loose body, surgical treatment should be attempted as a first-line treatment option. Whenever possible, preservation of the OCD fragment should be attempted. No consensus has been established for which cartilage restoration technique leads to the best outcomes. Our experience suggests that loose body removal may be considered as a first-line treatment option with good pain relief in most patients. Performing a restorative procedure immediately after fragment removal may be warranted, however, and close collaboration between physicians, surgeons, and radiologists with a special interest in cartilage repair and restoration may be of benefit.

## Acknowledgements

None.

## Conflicts of interest

There are no conflicts of interest.

## REFERENCES AND RECOMMENDED READING

Papers of particular interest, published within the annual period of review, have been highlighted as:

- of special interest
- ■ of outstanding interest

Additional references related to this topic can also be found in the Current World Literature section in this issue (pp. 150–151).

1. Pascual-Garrido C, Friel NA, Kirk SS, *et al.* Midterm results of surgical treatment for adult osteochondritis dissecans of the knee. *Am J Sports Med* 2009; 37 (Suppl 1):125S–130S.
2. Bradley J, Dandy DJ. Osteochondritis dissecans and other lesions of the femoral condyles. *J Bone Joint Surg Br* 1989; 71:518–522.
3. Cahill BR. Osteochondritis dissecans of the knee: treatment of juvenile and adult forms. *J Am Acad Orthop Surg* 1995; 3:237–247.
4. Crawford DC, Safran MR. Osteochondritis dissecans of the knee. *J Am Acad Orthop Surg* 2006; 14:90–100.
5. Kocher MS, Tucker R, Ganley TJ, Flynn JM. Management of osteochondritis dissecans of the knee: current concepts review. *Am J Sports Med* 2006; 34:1181–1191.
6. Robertson W, Kelly BT, Green DW. Osteochondritis dissecans of the knee in children. *Curr Opin Pediatr* 2003; 15:38–44.
7. Edmonds EW, Polousky J. A review of knowledge in osteochondritis dissecans: 123 years of minimal evolution from Konig to the ROCK Study Group. *Clin Orthop Relat Res* 2012. [Epub ahead of print]
- An interesting review from the ROCK study on cause, diagnosis, and treatment of OCD. Little advancement in understanding OCD in the last years is discussed.
8. Harada Y, Tomita N, Nakajima M, *et al.* Effect of low loading and joint immobilization for spontaneous repair of osteochondral defect in the knees of weightless (tail suspension) rats. *J Orthop Sci* 2005; 10:508–514.
9. Cahill BR. Current concepts review. Osteochondritis dissecans. *J Bone Joint Surg Am* 1997; 79:471–472.
10. Hefti F, Beguiristain J, Krauspe R, *et al.* Osteochondritis dissecans: a multi-center study of the European Pediatric Orthopedic Society. *J Pediatr Orthop B* 1999; 8:231–245.
11. Linden BJ. Osteochondritis dissecans of the femoral condyles: a long-term follow-up study. *J Bone Joint Surg Am* 1997; 59:769–776.
12. Twyman RS, Desai K, Aichroth PM. Osteochondritis dissecans of the knee. A long-term study. *J Bone Joint Surg Br* 1991; 73:461–464.
13. Lim HC, Bae JH, Park YE, *et al.* Long-term results of arthroscopic excision of unstable osteochondral lesions of the lateral femoral condyle. *J Bone Joint Surg Br* 2012; 94:185–189.
- Interesting long-term functional and radiological outcomes of arthroscopic removal of unstable osteochondral lesions with subchondral drilling.
14. Boughanem J, Riaz R, Patel RM, Sarwark JF. Functional and radiographic outcomes of juvenile osteochondritis dissecans of the knee treated with extra-articular retrograde drilling. *Am J Sports Med* 2011; 39:2212–2217.
15. Edmonds EW, Albright J, Bastrom T, Chambers HG. Outcomes of extra-articular, intra-epiphyseal drilling for osteochondritis dissecans of the knee. *J Pediatr Orthop* 2010; 30:870–878.
16. Makino A, Muscolo DL, Puigdevall M, *et al.* Arthroscopic fixation of osteochondritis dissecans of the knee: clinical, magnetic resonance imaging, and arthroscopic follow-up. *Am J Sports Med* 2005; 33:1499–1504.
17. Gomoll AH, Flik KR, Hayden JK, *et al.* Internal fixation of unstable Cahill Type-2C osteochondritis dissecans lesions of the knee in adolescent patients. *Orthopedics* 2007; 30:487–490.
18. Pascual-Garrido C, Tanoira I, Muscolo DL, *et al.* Viability of loose body fragments in osteochondritis dissecans of the knee. A series of cases. *Int Orthop* 2010; 34:827–831.
19. Magnussen RA, Carey JL, Spindler KP. Does operative fixation of an osteochondritis dissecans loose body result in healing and long-term maintenance of knee function? *Am J Sports Med* 2009; 37:754–759.
20. Tabaddor RR, Banffy MB, Andersen JS, *et al.* Fixation of juvenile osteochondritis dissecans lesions of the knee using poly 96L/4D-lactide copolymer bioabsorbable implants. *J Pediatr Orthop* 2010; 30:14–20.
21. Knutsen G, Drogset JO, Engebretsen L, *et al.* A randomized trial comparing autologous chondrocyte implantation with microfracture. Findings at five years. *J Bone Joint Surg Am* 2007; 89:2105–2112.
22. Gudas R, Simonaityte R, Cekanauskas E, Tamosiunas R. A prospective, randomized clinical study of osteochondral autologous transplantation versus microfracture for the treatment of osteochondritis dissecans in the knee joint in children. *J Pediatr Orthop* 2009; 29:741–748.
23. Miniaci A, Tytherleigh-Strong G. Fixation of unstable osteochondritis dissecans lesions of the knee using arthroscopic autogenous osteochondral grafting (mosaicplasty). *Arthroscopy* 2007; 23:845–851.
24. Bentley G, Biant LC, Vijayan S, *et al.* Minimum ten-year results of a prospective randomised study of autologous chondrocyte implantation versus mosaicplasty for symptomatic articular cartilage lesions of the knee. *J Bone Joint Surg Br* 2012; 94:504–509.
25. Kon E, Vannini F, Buda R, *et al.* How to treat osteochondritis dissecans of the knee: surgical techniques and new trends: AAOS exhibit selection. *J Bone Joint Surg Am* 2012; 94:e11–e18.
- Nice and brief summary of surgical treatment of OCD of the knee. Pictures and illustrations are worth a look.
26. Garrett JC. Fresh osteochondral allografts for treatment of articular defects in osteochondritis dissecans of the lateral femoral condyle in adults. *Clin Orthop Relat Res* 1994:33–37.
27. McCulloch PC, Kang RW, Sobhy MH, *et al.* Prospective evaluation of prolonged fresh osteochondral allograft transplantation of the femoral condyle: minimum 2-year follow-up. *Am J Sports Med* 2007; 35:411–420.