

## Chapter 40

# Elbow Injuries and the Throwing Athlete

James Hammond, DO, ATC    Brian J. Cole, MD, MBA

### Introduction

Overhead throwing imparts substantial stress to the elbow and can cause unique injuries. Biomechanical and clinical studies have elucidated the causative factors in these injuries and have allowed prevention and treatment strategies to evolve. The diagnosis of an elbow condition is facilitated by specific examination maneuvers, and radiography is useful for confirming the diagnosis. Prevention strategies, such as the monitoring of pitch counts, have been developed to decrease the risk of injury in young athletes. Evolving surgical strategies have contributed to changes in techniques for treating certain conditions in the throwing athlete.

### Throwing-Related Elbow Anatomy and Biomechanics

The medial or ulnar collateral ligament (UCL) is the most clinically relevant anatomic structure in the elbow of the throwing athlete. The UCL is a complex composed of the anterior oblique, posterior oblique, and transverse ligaments. The anterior oblique ligament is the strongest ligament of the complex and the most important stabilizer to valgus stress in the throwing athlete. The anterior oblique ligament originates in the medial epicondyle. A recent evaluation of the ulnar insertion of the anterior oblique ligament found that it extends distal to the sublime tubercle along a previously unnamed ridge and was present on all skeletal specimens.<sup>1</sup> Within the anterior oblique ligament, the anterior band and the posterior band alternately have

primary responsibility for valgus stress throughout the ranges of flexion and extension; the anterior band is tight during extension, and the posterior band is tight during flexion.

The UCL receives dynamic support from the surrounding musculature. The flexor carpi ulnaris is the primary dynamic contributor to valgus stabilization of the elbow, and the flexor digitorum superficialis is a secondary stabilizer.<sup>2</sup> These two muscles help disseminate the substantial forces across the elbow during the throwing motion and thereby protect the UCL. Their relationship has implications for preventing and managing UCL injuries.

The throwing motion creates substantial energy and subsequent forces that are mediated by structures about the elbow. Angular velocities as high as 3,000° per second have been observed at the elbow during the acceleration phase of the throwing motion. This velocity translates into 64 N/m of valgus torque. Because the tensile strength of the UCL is only 34 N/m, the other stabilizers of the elbow also are important for avoiding or minimizing injury.<sup>3</sup> The valgus load creates stress about the other aspects of the elbow: tensile forces occur on the medial aspect, shear and compressive stresses occur in the olecranon fossa as the elbow reaches extension, and compression forces occur laterally, primarily at the radiocapitellar joint. A recent cadaver study found that lateral contact pressures increased 67% after the UCL was transected.<sup>4</sup> Understanding these forces increases the ability to understand the relationships among the conditions that occur about the elbow.

### Clinical Evaluation

#### History

A specific, detailed patient history is vital to understanding elbow pathology in a throwing athlete. Arm dominance and the duration, intensity, and location of symptoms should be noted as well as the type of activity that elicits symptoms (for example, does the pain occur at rest, with activities of daily living, or only with throwing?). Information should be elicited as to

---

*Dr. Cole or an immediate family member has received royalties from Arthrex and DJ Orthopaedics; is a member of a speakers' bureau or has made paid presentations on behalf of Genzyme; serves as a paid consultant to or is an employee of Zimmer, Arthrex, Carticept, Biomimetic, Allosource, and DePuy; and has received research or institutional support from Regentis, Arthrex, Smith & Nephew, and DJ Orthopaedics. Neither Dr. Hammond nor any immediate family member has received anything of value from or has stock or stock options held in a commercial company or institution related directly or indirectly to the subject of this chapter.*

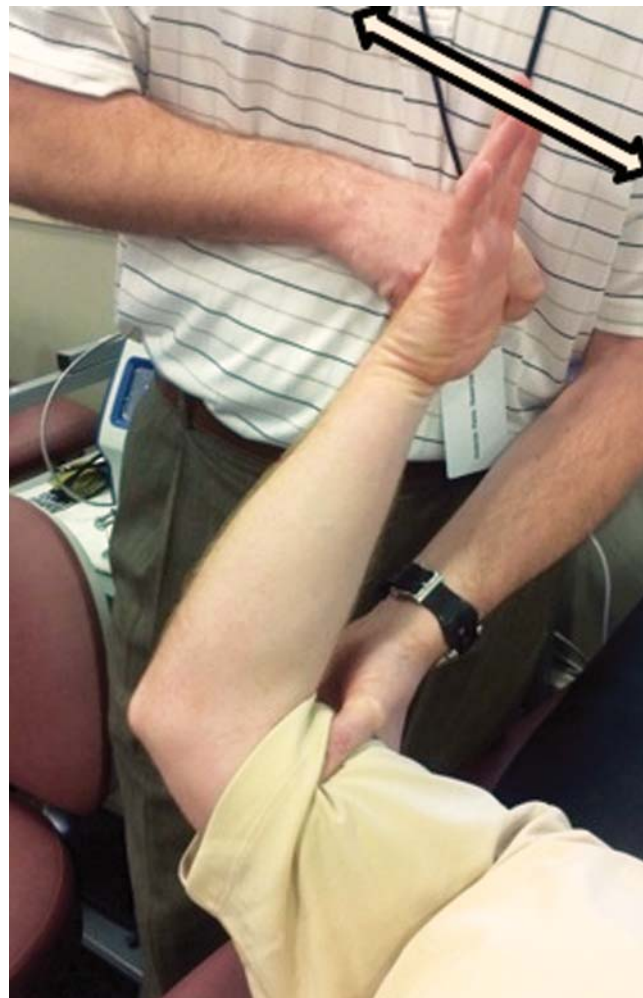
associated mechanical symptoms, paresthesias, or pain in other joints, especially the shoulder. It is important to determine the point in the throwing motion during which symptoms occur (windup, early cocking, late cocking, acceleration, deceleration, or follow through). The types of pitches, the number of pitches thrown per outing, and the throwing schedule should be determined. The curveball generates the greatest valgus stress at the elbow, the fastball and slider generate the greatest force, and the changeup generates less stress on the elbow and is considered a relatively safe pitch for athletes of all ages. However, skilled players are more likely to throw the fastball or the curveball, play on more teams, and pitch more frequently than other players.<sup>5</sup>

### Physical Examination

General observations are easy to overlook during an evaluation of the elbow, but they can provide insight into stresses about the elbow. The patient's carrying angle should be observed to identify any side-to-side difference. The exact location and the medial, lateral, or posterior character of the pain should be determined. The range of motion should be evaluated; a lack of full extension is common in throwers.

Typically, the focus of the examination in a throwing athlete is on the medial elbow. An acute avulsion injury of the UCL usually occurs proximally at the medial epicondyle, and tenderness there or along the length of the anterior oblique ligament should be determined. Resisted strength testing of the flexor-pronator mass is done. Valgus stress at 0° and 30° of flexion also is typically assessed, but the instability is often more subtle in a throwing athlete. This test lacks the sensitivity needed to reliably identify a chronic injury. The milking maneuver and the moving valgus stress test also are used to assess valgus instability and UCL injury. The milking maneuver is performed by pulling on the patient's thumb with the forearm supinated and the elbow flexed beyond 90°. The moving valgus stress test begins in the same position, and the patient's thumb is pulled until the limit of external rotation is reached at the shoulder. The elbow is taken through a range of motion while the torque created by pulling on the thumb remains constant. Pain typically is most intense when the elbow is between 70° and 120° (Figure 1). The sensitivity of the moving valgus stress test is reported to be 100%, with 75% specificity.<sup>6</sup>

A patient with suspected UCL injury should be assessed for ulnar nerve pathology. Evidence of nerve subluxation, a positive Tinel sign, or symptoms with elbow hyperflexion testing should be noted. Pain associated with a flexor-pronator injury, as indicated by pain with resistance testing, should be differentiated from pain associated with medial epicondylitis, as indicated by tenderness over only the epicondyle with normal moving valgus stress.

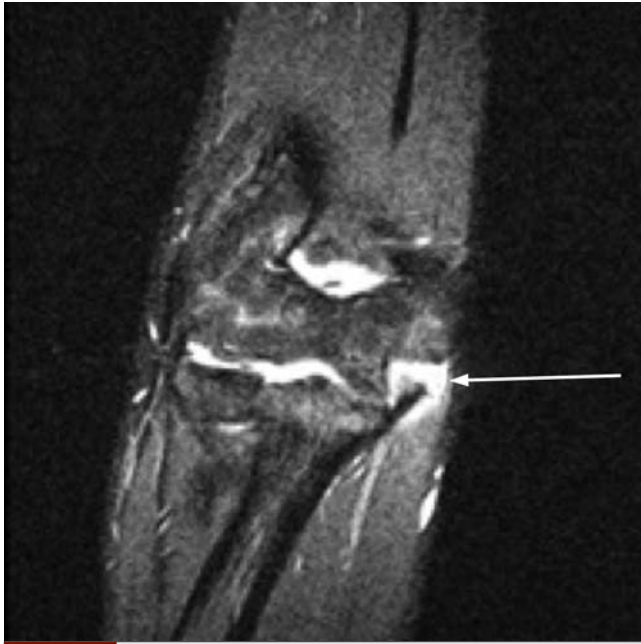

**Figure 1** Photograph showing the moving valgus stress test. Double-headed arrow = directions of motion.

### Imaging

The initial imaging studies are plain radiographs in the AP, lateral, radiocapitellar, and axillary views. Valgus stress radiographs can be used to identify a medial joint line opening; an opening of more than 3 mm has been considered diagnostic.<sup>7</sup> The radiographs can be assessed for evidence of osteophytes, loss of joint space, loose bodies, or osteochondral defects. MRI can be used to confirm several diagnoses about the elbow, including osteochondritis dissecans, a UCL injury, avulsion of the flexor-pronator mass, and chronic thickening of the UCL. A recent study found that signal intensity on MRI can be used to predict rehabilitation outcomes; patients with a complete or high-grade UCL tear were most likely to require surgery<sup>8</sup> (Figure 2).

Ultrasonography and dynamic ultrasonographic examination have been described for defining UCL injury, but most available studies are small case studies or case reports. Several studies have found differences in UCL laxity among overhead throwing athletes as well as



**Figure 2** MRI showing a complete avulsion of the UCL from the humeral epicondyle (arrow).

side-to-side differences between the athletes' throwing and nonthrowing arms.<sup>9,10</sup>

Arthroscopy has been used as a diagnostic tool primarily for closely evaluating a joint line opening with stress; 1 to 2 mm of joint line opening indicate a partial-thickness tear, and 4 to 10 mm of opening indicate a full-thickness tear. The ulnohumeral joint is viewed from the anterolateral portal, and the joint is stressed at 65° to 70° of elbow flexion with the forearm pronated.<sup>11</sup>

### Conditions Causing Medial Elbow Pain

#### Medial Epicondylitis

Medial epicondylitis is less common than lateral epicondylitis and usually occurs as a result of repetitive wrist flexion and forceful pronation during golf, a racquet sport, or overhead throwing. Pain typically is elicited over the medial elbow and exacerbated by resisted forearm flexion and pronation. The diagnosis is primarily clinical, but ultrasonography and MRI are reported to be useful.<sup>12</sup> On MRI, increased signal is seen in the flexor muscular origin about the medial epicondyle.<sup>13</sup> Nonsurgical treatments have high success rates. The components of a typical nonsurgical treatment program include NSAIDs, flexibility exercises, ice, and guided physical therapy. Steroid injections have also been used. The use of iontophoresis was found to improve pain relief in a comparative study.<sup>14</sup> Ultrasound-guided autologous blood injection led to improved scores on the visual analog and modified Nirschl Pain Phase scales.<sup>15</sup> Surgical intervention typically involves

resection of a portion of the diseased tendon by open, miniopen, or arthroscopic means. If the surgical goal has been accomplished, pain relief can be expected, but a strength deficit may remain.

#### UCL Injury

The initial management of a UCL injury in an overhead throwing athlete should be nonsurgical. The regimen includes a 6-week period of rest from throwing as well as strengthening of the flexor-pronator musculature.<sup>2</sup> The athlete should be asymptomatic and have a normal examination before throwing activities are resumed. At that time, the athlete should optimize throwing mechanics and offset stress from the medial elbow. Late trunk rotation, reduced shoulder external rotation, and increased elbow flexion have been shown to increase valgus stress at the elbow.<sup>16</sup> A 42% return-to-sport rate was reported for overhead throwing athletes at a mean 24.5-week follow-up.<sup>17</sup>

In the original Jobe technique for reconstructing the UCL, a figure-of-8 tendon graft was woven through bone tunnels and sutured back onto itself. This technique required takedown of the flexor-pronator mass and exposure of the posterior humeral cortex for one of the tunnels. An ulnar nerve transposition always was performed. The substantial morbidity of the exposure led to modification of this technique and development of new techniques. The modified Jobe technique consists of a muscle-splitting approach to decrease morbidity to the flexor-pronator musculature, a change in humeral tunnel direction, and ulnar nerve transposition only if the patient has preoperative symptoms. The humeral tunnel is directed somewhat anteriorly to avoid ulnar nerve injury with graft passage and decrease the dissection necessary for exposure. The outcomes and the biomechanical strength resulting from using the modified Jobe technique have become the standard for comparison with any other technique. A 93% return-to-sport rate was reported for overhead throwing athletes.<sup>7</sup> Another study reported an 83% return to the previous level of throwing at a minimum 2-year follow-up after a modified Jobe technique was used.<sup>18</sup>

The commonly described docking technique also uses a muscle-splitting approach and two converging tunnels in the ulna. Only one primary tunnel is drilled in the humerus, and two smaller holes are drilled in the humerus to facilitate suture passage. One limb of the tendon graft is passed into the tunnel in the humerus. The second limb of the tendon graft is assessed for length and tension, sectioned to the appropriate length, and docked in the humeral socket. The sutures from each limb of the tendon graft are tied over a bone bridge after final tensioning. The use of the docking technique led to a good or excellent outcome in 19 of 21 athletes (90%).<sup>19</sup> An excellent result was defined as a return to previous level of play for at least 1 year, and a good result was defined as a return to throwing at a lower level for at least 1 year or the ability to throw at daily batting practice. A 92% rate of return to the pre-

injury level of throwing was reported at an 11.5-month follow-up after a quadrupled palmaris graft was used with the docking technique.<sup>20</sup>

Several techniques can be categorized as hybrid. A relatively new technique uses a single drill hole at the sublime tubercle and a single drill hole in the medial epicondyle. An interference screw is used at the sublime tubercle, with a docking technique on the humeral attachment. At 3-year follow-up after this technique was used, 19 of 22 patients (86%) had an excellent result.<sup>21</sup> Another technique uses the same single drill holes on the sublime tubercle and the medial epicondyle, with interference screws on each end of the construct. In a biomechanical study, this technique led to stability similar to that of intact UCL specimens.<sup>3</sup>

### Ulnar Neuritis

Approximately 40% of patients with UCL insufficiency have ulnar neuritis. A substantial valgus stress can create traction, friction, and compression on the nerve and induce neuritis. The presence of adhesions and/or osteophytes, nerve subluxation, a thickened medial triceps, or UCL injury also can increase stress on the nerve. Night pain and paresthesias into the ulnar nerve distribution can occur. Ulnar nerve symptoms can occur with throwing. On physical examination, a positive Tinel sign at the cubital tunnel, a positive elbow hyperflexion test, and/or evidence of ulnar nerve subluxation can be observed. Nonsurgical measures, including the use of night splinting, ice, NSAIDs, and activity modification, can be successful. Surgical treatment typically involves transposing the ulnar nerve into a subcutaneous position. This procedure has had great success with appropriate rehabilitation and a graduated return to throwing activities. The time to return to play with isolated ulnar nerve transposition is approximately 12 weeks.<sup>22</sup> If the patient has ulnar nerve symptoms associated with a UCL injury requiring reconstruction, ulnar nerve transposition should be done at the time of reconstruction.

### Conditions Causing Posterior Elbow Pain

#### Posteromedial Impingement or Valgus Extension Overload

Valgus extension overload is a relatively common condition in overhead throwing athletes in which posterior and, commonly, medial osteophytes impinge within the olecranon fossa as the elbow reaches extension. A review of 72 professional baseball players who underwent elbow surgery found that 65% had posterior olecranon osteophytes.<sup>23</sup> Athletes typically report posterior pain at the elbow during ball release and as the elbow reaches extension; this is the point at which osteophytes from the olecranon impinge within the fossa. The patient also commonly has some loss of terminal extension on examination. When valgus stress on the

elbow is applied at 20° to 30° of flexion and the elbow is quickly taken to extension, a positive test re-creates the pain in the posteromedial elbow. Care must be taken to determine whether there is a concomitant UCL injury because there is a significant relationship between these diagnoses. Plain radiographs can reveal the posterior osteophyte.

Nonsurgical treatment begins with rest and 10 to 14 days of throwing restrictions followed by an interval throwing program to allow a gradual return to throwing. Pitching mechanics must be corrected during the interval throwing program to minimize stress at the elbow. A longer period of rest is recommended if symptoms persist or the patient cannot return to throwing at the earlier level. Intra-articular injection is not particularly helpful in patients with posteromedial impingement and should not be repeated.

Surgical treatment should be carefully considered. The medial elbow endures substantial valgus forces in the throwing athlete, and engagement of the olecranon in its fossa provides secondary stabilization to the elbow, particularly during extension. Any subtle laxity in the UCL may transfer stress to the posteromedial olecranon and cause it to impinge on the fossa as the elbow reaches extension. This stress induces osteophyte formation, which then increases impingement by shear mass effect. Overresection of the posteromedial olecranon can unmask or exacerbate symptoms of UCL injury. Twenty-five percent of professional baseball players who underwent osteophyte excision later had valgus instability requiring UCL reconstruction.<sup>23</sup> Studies conflict as to the amount of olecranon that can be excised before increased strain is seen at the UCL, and there is debate as to whether any excision of normal olecranon should be done. The procedure can be done in an arthroscopic or open fashion. In an open procedure, an osteotome is used to resect a portion of the olecranon tip, and a portion of the medial olecranon is removed. The arthroscopic procedure can be accomplished using a posterolateral portal for viewing and a central posterior portal for working. Care must be taken to remove osteophytes and minimize resection of normal olecranon. In addition, care must be taken to avoid ulnar nerve injury when resecting the medial aspect of the osteophyte as the ulnar nerve enters the cubital tunnel. A recent study reported an excellent outcome in seven of nine patients who underwent arthroscopic treatment of valgus extension overload.<sup>24</sup>

#### Olecranon Stress Fracture

Stress fractures of the olecranon have been described in javelin throwers and other throwing athletes.<sup>25,26</sup> These fractures are primarily described as transverse or oblique, with a mechanism of injury similar to that of a valgus extension overload injury. The olecranon is subject to increased stress as the elbow undergoes a valgus load and approaches extension. The substantial triceps forces at extension also have been implicated in this condition.

On physical examination, the athlete may have tenderness over the physis (if it is open), the posterior olecranon, or the posteromedial olecranon. Symptoms may be elicited by forceful extension of the elbow or resisted triceps muscle testing. Typically, the patient has less extension than in the contralateral elbow. Plain radiographs may show a sclerotic line of remodeling fracture if the condition is chronic. If the physis is open, it may be beneficial to obtain radiographs of the contralateral side to detect any physeal widening. A bone scan will reveal increased uptake in the area. MRI will show edema within the bone and allow characterization of the fracture line. MRI also is beneficial if an associated UCL injury is suspected.

The treatment of an olecranon stress fracture is somewhat controversial. Nonsurgical measures require rest from throwing and possibly temporary splinting. The return to an interval throwing program is delayed until symptoms have subsided and there is radiographic evidence of fracture healing. As a result, throwing can be restricted for as long as 6 months. Stress fractures may respond to bone stimulators, but this treatment has not been well defined.

Some experts recommend early surgical treatment to reduce the time to resumption of throwing.<sup>27</sup> Surgical treatment also is recommended if nonsurgical management is unsuccessful. Tension-band wiring, tension-band wiring with a compression screw, and the use of a compression screw alone have been described. A 6.5- or 7.3-mm cannulated compression screw typically is used. A recent case report described a persistent fracture after fixation in a college pitcher, in which bone grafting ultimately was required for healing.<sup>28</sup>

### Persistent Olecranon Physis

The persistent olecranon physis is similar to an olecranon stress fracture and may be responsible for an athlete's posterior elbow pain. The olecranon physis has two ossification centers: the posterior center is oriented transverse to the longitudinal axis of the ulna and contributes to longitudinal growth; a second center is more anterior at the olecranon tip, contributing to the joint surface but not to longitudinal growth. These two centers fuse and create a single physis that persists until approximately age 14 years in girls and age 16 years in boys. This physis can become sclerotic during the process of closing and can be as wide as 5 mm.

Posterior elbow pain typically develops during the years from adolescence through the late teens. The pain occurs at terminal extension in the follow-through phase of throwing, and it can be relieved with rest. The physical examination may be benign; motion is normal, the elbow is stable, and there is no tenderness to palpation. Plain radiographs reveal a persistent physis in the olecranon that may be wider on the involved side than on the contralateral side. There may be evidence of sclerosis about the physis that is unexpected for the patient's age. T2-weighted MRI may show edema about the physis, but this finding is not diagnostic.

Treatment starts with nonsurgical measures, including a period of relative rest and cessation of throwing activities. NSAIDs and ice may be used as needed. Nonsurgical measures appear to be successful in most patients but may require as long as 4 months. The options for surgical treatment include open reduction and internal fixation, bone grafting, and open reduction and internal fixation with bone grafting. The fixation techniques include tension-band wiring, compression screws, and a combination of screws and tension-band wiring. The available studies are largely limited to case reports and small case studies.<sup>29,30</sup> It appears that the highest rates of successful union were in patients who underwent bone grafting with or without fixation. Those undergoing fixation alone had an approximately 66% failure rate. A recent study found that those with a persistent olecranon physis and evidence of sclerosis had a 100% failure rate with nonsurgical measures.<sup>31</sup>

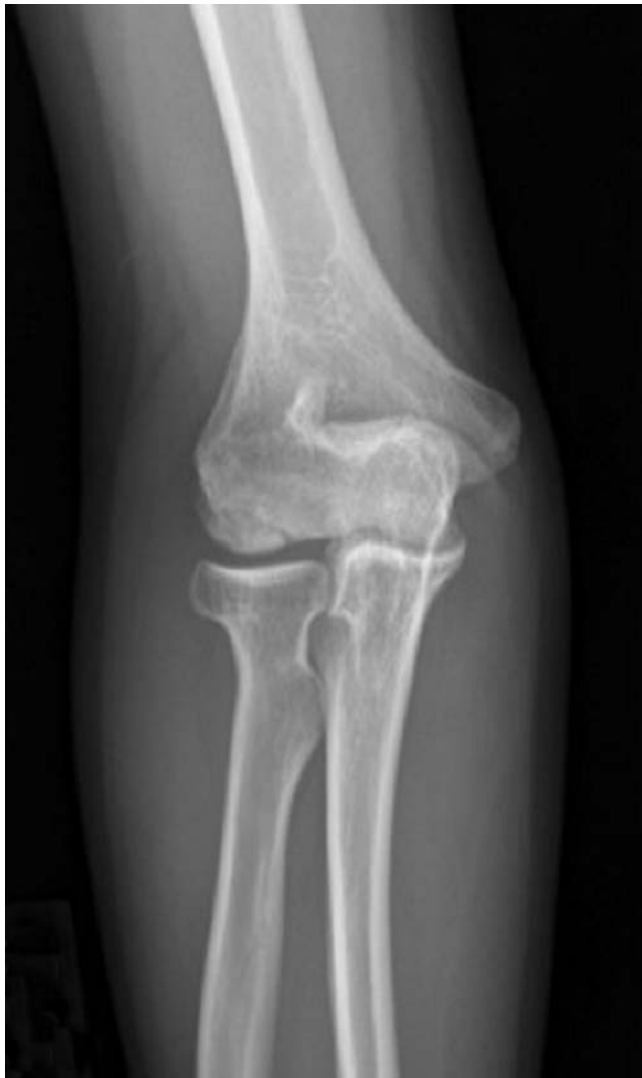### Conditions Causing Lateral Elbow Pain

#### Capitellar Osteochondritis Dissecans

Osteochondritis dissecans (OCD) is a local disorder of the subchondral bone that results in separation and fragmentation of articular cartilage and its underlying bone. It is important to differentiate this condition from Panner disease, which occurs in younger patients, is idiopathic, usually is self-limiting, and improves without surgical intervention. OCD typically occurs at the elbow in adolescents who are high-demand, repetitive overhead throwing athletes. The pathogenesis is not completely understood. Genetic factors, blood supply, repetitive trauma, and a vulnerable epiphysis have been implicated. The underlying bone undergoes degradation and can destabilize the overlying cartilage. Probably a combination of factors contributes to the process by which the lesion is created.

Typically, the athlete has elbow pain during activity. The pain is insidious in onset, is relieved by rest, and progresses if the activity is continued. The pain is difficult to localize and often is accompanied by loss of motion. Occasionally, the symptoms are mechanical, with catching or locking of the elbow joint. The most common finding on examination is tenderness over the radiocapitellar joint. Crepitus can be elicited in the lateral joint with pronation and supination, and there is loss of motion of 15° to 30°. In the active radiocapitellar compression test, the elbow is fully extended while the patient actively pronates and supinates the forearm and contracts the muscles about the elbow. A positive test reproduces the athlete's symptoms.

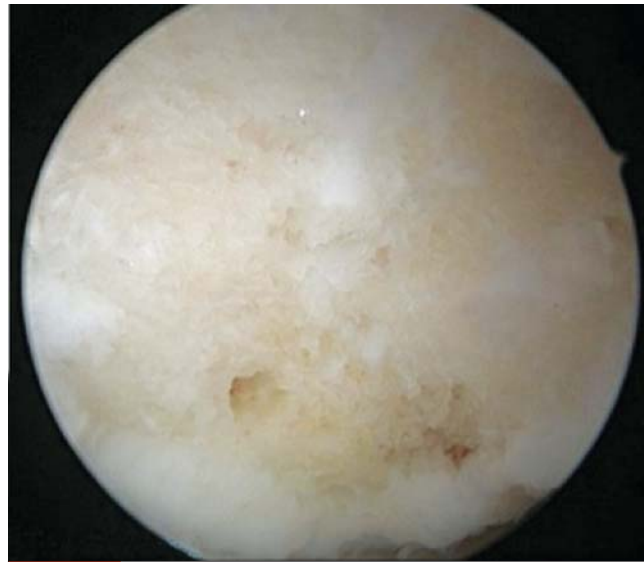The initial imaging is with plain radiographs. The standard AP view in full extension and lateral views in 90° of flexion show typical capitellar radiolucency and flattening of the joint surface (**Figure 3**). The lesion commonly occurs in the anterolateral aspect of the capitellum. In the Minami classification system, a grade I lesion is a translucent cystic shadow in the mid-



**Figure 3** AP radiograph showing OCD of the capitellum in which there is a complete fragment with subtle displacement. Such a lesion often has a relatively normal arthroscopic appearance because the articular cartilage is intact.

dle or lateral capitellum, a grade II lesion has a split line or clear zone between the lesion and its subchondral bone, and loose bodies are present in a grade III lesion.<sup>32</sup>

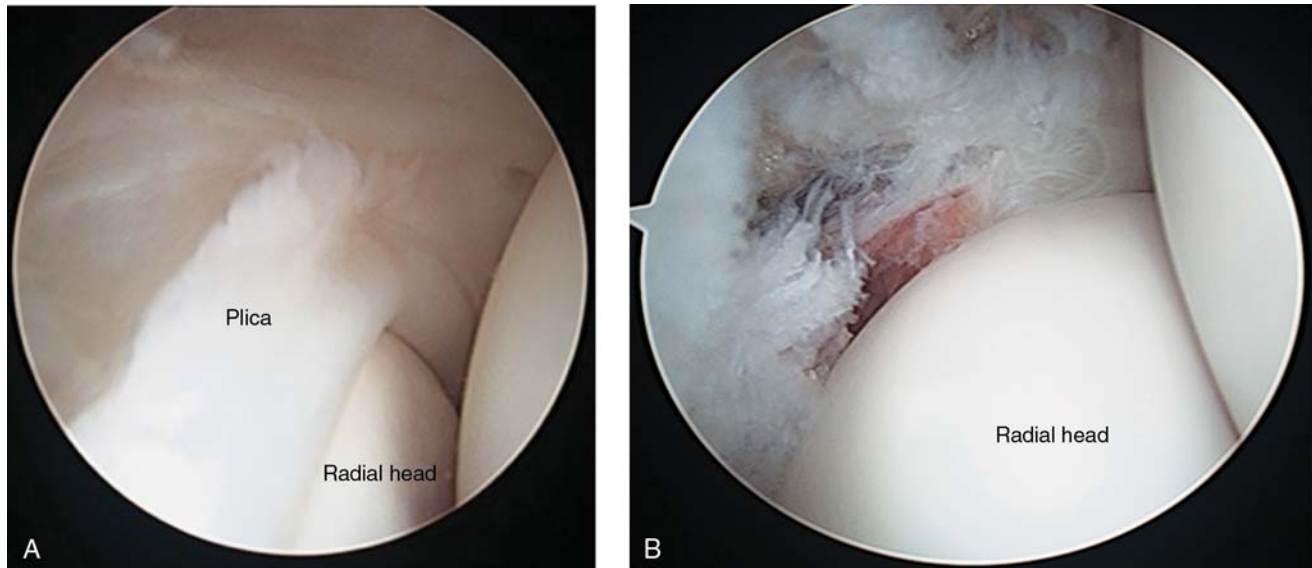
MRI has become the modality of choice for evaluating these lesions. Early changes not found on plain radiographs can be detected on MRI, and the size, location, and stability of the lesion can be assessed. The key to making a treatment decision is to determine whether the articular surface is intact and the lesion is stable as seen on MRI. A peripheral ring of fluid or fluid under the articular surface suggests an unstable lesion; these findings are similar to those of an OCD lesion in another area of the body. The diagnosis sometimes is facilitated by the addition of arthrographically or intravenously administered gadolinium.



**Figure 4** Arthroscopic image showing an OCD lesion after microfracture.

OCD lesions are amenable to healing, and nonsurgical regimens are an option. The treatment begins with 6 months of elbow rest without throwing activity. Anti-inflammatory medications are used, and physical therapy is implemented to optimize motion and strength. Radiographs are assessed at 6-week intervals to ensure that the lesion is healing or is not progressing. MRI is repeated as needed at an approximately 3-month interval and compared with the initial studies. An interval throwing program is initiated at 6 months if the athlete has good motion, is asymptomatic, and has evidence of healing. Pitch counts initially should be monitored.<sup>33</sup> Patients with capitellar lucency or flattening have healing rates of 88% to 91%.<sup>34,35</sup> Those with open capitellar physes have a higher rate of healing. Advanced lesions have less capacity for nonsurgical healing. A stable lesion is characterized by an open capitellar growth plate, localized flattening or radiolucency of the subchondral bone, and good elbow motion. In an unstable lesion, the physis is closed, with radiographic fragmentation and loss of elbow motion of more than 20°.<sup>36</sup>

Surgical management is indicated if the patient has an unstable lesion or loose bodies or if nonsurgical treatment has been unsuccessful. Several surgical procedures have been described. Simple débridement can be effective for a contained lesion involving less than 50% of the capitellar surface. Microfracture or trephination of the subchondral base with a Kirschner wire also can be used after fragment excision and bed preparation (**Figure 4**). Fixation of a relatively large, unfragmented lesion can be achieved through different methods. Pull-out wires, bone grafting, and Herbert screws have been successfully used. Several options exist for cartilage replacement, mirroring the options used in the knee and other joints. Mosaicplasty, osteochondral allograft, and



**Figure 5** Arthroscopic images showing an anterolateral plica covering the radial head (A) and the radiocapitellar joint after resection of the plica (B).

autograft transplantation have been used to treat a relatively large OCD lesion or an uncontained lesion (in which there is loss of lateral column support).

### Radiocapitellar Plica

Radiocapitellar plica, first described as a cause of a snapping elbow, essentially is a hypertrophic synovial plica that snaps over the edge of the radial head as the elbow moves from flexion to extension. The differential diagnosis includes intra-articular loose bodies, instability, lateral epicondylitis, and subluxation of the medial triceps over the medial epicondyle. Some of these conditions can be ruled out on the basis of location. The elbow examination typically is otherwise benign, with stability, full motion, and normal strength. The patient may have tenderness posterior to the lateral epicondyle and centered over the joint. Plain radiographs usually are not informative, and the plica frequently is missed on MRI.

Nonsurgical measures should be initially considered, including relative rest, NSAIDs, and gentle motion. Intra-articular steroid injections have been used in an attempt to relieve inflammation and decrease pain. Surgical treatment with an arthroscopic procedure has yielded good results. The snapping of the plica typically can be replicated on arthroscopic examination and allows the surgeon to locate the area to be released (Figure 5). The goal is to adequately release the synovial plica so that it no longer snaps over the radial head. The examination is repeated to ensure the release is complete. Postoperative management allows early range of motion and advancement of strength. An interval throwing program typically is started at 8 weeks and can advance as long as the patient remains asymptomatic.

### Summary

The elbow of a throwing athlete endures substantial stress during the phases of the throwing motion. The key to the correct diagnosis is to analyze the condition by elbow region, obtain a detailed history, apply specific examination maneuvers, and obtain appropriate imaging studies. Nonsurgical measures can be successful during specific phases of the disease process, and advances in surgical techniques have improved patient outcomes. Arthroscopic procedures have an increasing role in treating many conditions, with acceptable outcomes and return-to-play rates. Postoperative management is stepwise and specific to restore optimal mechanics, flexibility, and strength to the affected muscle groups.

### Annotated References

1. Farrow LD, Mahoney AJ, Stefancin JJ, Taljanovic MS, Sheppard JE, Schickendantz MS: Quantitative analysis of the medial ulnar collateral ligament ulnar footprint and its relationship to the ulnar sublime tubercle. *Am J Sports Med* 2011;39(9):1936-1941.  
The anterior band of the UCL was evaluated in 10 fresh-frozen cadaver specimens. The mean length was 53.0 mm, and the mean length of the footprint on the ulna was 29.2 mm. The ridge was present in all specimens and had a mean measurement of 24.5 mm.
2. Park MC, Ahmad CS: Dynamic contributions of the flexor-pronator mass to elbow valgus stability. *J Bone Joint Surg Am* 2004;86-A(10):2268-2274.
3. Ahmad CS, Lee TQ, ElAttrache NS: Biomechanical evaluation of a new ulnar collateral ligament recon-

- struction technique with interference screw fixation. *Am J Sports Med* 2003;31(3):332-337.
4. Duggan JP Jr, Osadebe UC, Alexander JW, Noble PC, Lintner DM: The impact of ulnar collateral ligament tear and reconstruction on contact pressures in the lateral compartment of the elbow. *J Shoulder Elbow Surg* 2011;20(2):226-233.  
Six cadaver specimens were tested under a valgus load of 1.75 N/m and 5.25 N/m torque to simulate late cocking and the release phase. The average valgus laxity was doubled after UCL transection and restored after reconstruction.
  5. Fleisig GS, Kingsley DS, Loftice JW, et al: Kinetic comparison among the fastball, curveball, change-up, and slider in collegiate baseball pitchers. *Am J Sports Med* 2006;34(3):423-430.
  6. O'Driscoll SW, Lawton RL, Smith AM: The "moving valgus stress test" for medial collateral ligament tears of the elbow. *Am J Sports Med* 2005;33(2):231-239.
  7. Thompson WH, Jobe FW, Yocum LA, Pink MM: Ulnar collateral ligament reconstruction in athletes: Muscle-splitting approach without transposition of the ulnar nerve. *J Shoulder Elbow Surg* 2001;10(2):152-157.
  8. Kim NR, Moon SG, Ko SM, Moon WJ, Choi JW, Park JY: MR imaging of ulnar collateral ligament injury in baseball players: Value for predicting rehabilitation outcome. *Eur J Radiol* 2011;80(3):e422-e426.  
Thirty-nine baseball players with clinical evidence of UCL injury were evaluated with MRI. After nonsurgical treatment, 27 required surgery. The patients who responded to nonsurgical treatment had a less severe injury on MRI, and those with a higher-grade injury required surgery.
  9. Nazarian LN, McShane JM, Ciccotti MG, O'Kane PL, Harwood MI: Dynamic US of the anterior band of the ulnar collateral ligament of the elbow in asymptomatic major league baseball pitchers. *Radiology* 2003;227(1):149-154.
  10. Sasaki J, Takahara M, Ogino T, Kashiwa H, Ishigaki D, Kanauchi Y: Ultrasonographic assessment of the ulnar collateral ligament and medial elbow laxity in college baseball players. *J Bone Joint Surg Am* 2002;84-A(4):525-531.
  11. Field LD, Altchek DW: Evaluation of the arthroscopic valgus instability test of the elbow. *Am J Sports Med* 1996;24(2):177-181.
  12. Park GY, Lee SM, Lee MY: Diagnostic value of ultrasonography for clinical medial epicondylitis. *Arch Phys Med Rehabil* 2008;89(4):738-742.  
An ultrasonographic assessment of 21 elbows with a clinical diagnosis of medial epicondylitis had sensitivity, specificity, accuracy, positive predictive value, and negative predictive value > 90%. This study reinforced the value of the physical examination and moved toward validating ultrasonography for diagnosing medial epicondylitis.
  13. Kijowski R, De Smet AA: Magnetic resonance imaging findings in patients with medial epicondylitis. *Skeletal Radiol* 2005;34(4):196-202.
  14. Nirschl RP, Rodin DM, Ochiai DH, Maartmann-Moe C; DEX-AHE-01-99 Study Group: Iontophoretic administration of dexamethasone sodium phosphate for acute epicondylitis: A randomized, double-blinded, placebo-controlled study. *Am J Sports Med* 2003;31(2):189-195.
  15. Suresh SP, Ali KE, Jones H, Connell DA: Medial epicondylitis: Is ultrasound guided autologous blood injection an effective treatment? *Br J Sports Med* 2006;40(11):935-939, discussion 939.
  16. Aguinardo AL, Chambers H: Correlation of throwing mechanics with elbow valgus load in adult baseball pitchers. *Am J Sports Med* 2009;37(10):2043-2048.  
Three-dimensional motion analysis was used to evaluate 69 adult baseball pitchers at an indoor mound. The variables most associated with elbow valgus included late trunk rotation, reduced shoulder external rotation, and increased elbow flexion. Sidearm pitchers were less susceptible to elbow valgus than those with a higher arm slot.
  17. Rettig AC, Sherrill C, Snead DS, Mendler JC, Mieling P: Nonoperative treatment of ulnar collateral ligament injuries in throwing athletes. *Am J Sports Med* 2001;29(1):15-17.
  18. Cain EL Jr, Andrews JR, Dugas JR, et al: Outcome of ulnar collateral ligament reconstruction of the elbow in 1281 athletes: Results in 743 athletes with minimum 2-year follow-up. *Am J Sports Med* 2010;38(12):2426-2434.  
Prospective data were collected for a 2-year minimum on 942 patients, most of whom underwent UCL reconstruction with a palmaris longus or gracilis graft using the modified Jobe technique. All patients underwent subcutaneous nerve transposition. The rate of return to previous level of function was 83%. The average time to return to throwing was 4.4 months, and the average return to competition was 11.6 months.
  19. Bowers AL, Dines JS, Dines DM, Altchek DW: Elbow medial ulnar collateral ligament reconstruction: Clinical relevance and the docking technique. *J Shoulder Elbow Surg* 2010;19(2, suppl):110-117.  
Of 21 overhead athletes who underwent UCL reconstruction with a modified docking technique using a three-strand graft, 90% had a good or excellent result. This technique is acceptable for UCL reconstruction.
  20. Paletta GA Jr, Wright RW: The modified docking procedure for elbow ulnar collateral ligament reconstruction: 2-year follow-up in elite throwers. *Am J Sports Med* 2006;34(10):1594-1598.



21. Dines JS, ElAttrache NS, Conway JE, Smith W, Ahmad CS: Clinical outcomes of the DANE TJ technique to treat ulnar collateral ligament insufficiency of the elbow. *Am J Sports Med* 2007;35(12):2039-2044.  
Twenty-two athletes underwent UCL reconstruction with a hybrid variation of the docking technique in which an interference screw is used in a single tunnel on the ulna to avoid the fracture risk of the two-tunnel technique. Nineteen patients had an excellent result, as did patients requiring revision for sublime tubercle avulsions.
22. Rettig AC, Ebben JR: Anterior subcutaneous transfer of the ulnar nerve in the athlete. *Am J Sports Med* 1993;21(6):836-839, discussion 839-840.
23. Andrews JR, Timmerman LA: Outcome of elbow surgery in professional baseball players. *Am J Sports Med* 1995;23(4):407-413.
24. Cohen SB, Valko C, Zoga A, Dodson CC, Ciccotti MG: Posteromedial elbow impingement: Magnetic resonance imaging findings in overhead throwing athletes and results of arthroscopic treatment. *Arthroscopy* 2011;27(10):1364-1370.  
After unsuccessful nonsurgical treatment, nine patients with posteromedial impingement underwent arthroscopy followed by rehabilitation and an interval throwing program. The results were excellent at a mean 68-month follow-up.
25. Hulkko A, Orava S, Nikula P: Stress fractures of the olecranon in javelin throwers. *Int J Sports Med* 1986;7(4):210-213.
26. Nuber GW, Diment MT: Olecranon stress fractures in throwers: A report of two cases and a review of the literature. *Clin Orthop Relat Res* 1992;278:58-61.
27. Suzuki K, Minami A, Suenaga N, Kondoh M: Oblique stress fracture of the olecranon in baseball pitchers. *J Shoulder Elbow Surg* 1997;6(5):491-494.
28. Stephenson DR, Love S, Garcia GG, Mair SD: Recurrence of an olecranon stress fracture in an elite pitcher after percutaneous internal fixation: A case report. *Am J Sports Med* 2012;40(1):218-221.  
A collegiate pitcher with an olecranon stress fracture was successfully treated nonsurgically but had a recurrence on return to full activity. Seven months after surgical treatment with a single cannulated screw, he had posterior elbow pain with bullpen throwing. Revision fixation was with repeat screw fixation and a second smaller screw. After an interval throwing program, the patient returned to pitching without symptoms at 17-month follow-up.
29. Charlton WP, Chandler RW: Persistence of the olecranon physis in baseball players: Results following operative management. *J Shoulder Elbow Surg* 2003;12(1):59-62.
30. Skak SV: Fracture of the olecranon through a persistent physis in an adult: A case report. *J Bone Joint Surg Am* 1993;75(2):272-275.
31. Matsuura T, Kashiwaguchi S, Iwase T, Enishi T, Yasui N: The value of using radiographic criteria for the treatment of persistent symptomatic olecranon physis in adolescent throwing athletes. *Am J Sports Med* 2010;38(1):141-145.  
In a retrospective analysis of persistent olecranon physis in 16 male baseball players, the lesions were classified as stage I (a widened physis compared with the contralateral elbow) or stage II (radiographic lesion). Nonsurgical treatment was successful in 92% of those with a stage I lesion but none with a stage II lesion.
32. Minami M, Nakashita K, Ishii S, et al: Twenty-five cases of osteochondritis dissecans of the elbow. *Rinsho Seikei Geka* 1979;14(8):805-810.
33. Baker CL III, Romeo AA, Baker CL Jr: Osteochondritis dissecans of the capitellum. *Am J Sports Med* 2010;38(9):1917-1928.  
OCD of the capitellum was reviewed, including pathoanatomy, clinical presentation, diagnostic studies, nonsurgical and surgical treatments, and a rehabilitation program.
34. Mihara K, Tsutsui H, Nishinaka N, Yamaguchi K: Nonoperative treatment for osteochondritis dissecans of the capitellum. *Am J Sports Med* 2009;37(2):298-304.  
Retrospective review of 39 patients with OCD of the capitellum who were treated nonsurgically led to the recommendation that patients with an advanced lesion undergo surgical intervention because of poor healing rates and evidence of progression with nonsurgical management.
35. Matsuura T, Kashiwaguchi S, Iwase T, Takeda Y, Yasui N: Conservative treatment for osteochondrosis of the humeral capitellum. *Am J Sports Med* 2008;36(5):868-872.  
Retrospective review of 176 patients with OCD of the humeral capitellum found that 90.5% of stage I and 53% of stage II lesions healed with nonsurgical measures. Mean time to healing was 14.9 months and 12.3 months for stage I and II lesions, respectively, and return-to-throwing rates were 78.6% and 52.9%, respectively.
36. Takahara M, Mura N, Sasaki J, Harada M, Ogino T: Classification, treatment, and outcome of osteochondritis dissecans of the humeral capitellum. *J Bone Joint Surg Am* 2007;89(6):1205-1214.  
In a retrospective review of 106 patients with OCD of the humeral capitellum, treatment was nonsurgical or surgical fragment removal, fragment fixation with bone grafting, or mosaicplasty with plugs from the lateral femoral condyle. Lesions were classified as stable or unstable at 7.2-year follow-up. Stable lesions responded well to nonsurgical measures, and unstable lesions responded to surgical intervention.

