

Technical Note

Osteochondral Allografts: Pearls to Maximize Biologic Healing and Clinical Success

Sachin Allahabadi, M.D., Erik C. Haneberg, B.S., Tristan J. Elias, B.A.,
Katie J. McMorro, B.S., Adam B. Yanke, M.D., Ph.D., and Brian J. Cole, M.D., M.B.A.

Abstract: We present an evidence-based approach to optimize the biologic incorporation of osteochondral allografts: (1) The donor graft is gradually rewarmed to room temperature to reverse the metabolic suppression from cold storage. (2) The graft is harvested while submerged in saline to limit thermal necrosis. (3) Subchondral bone depth is preferred at 4 to 6 mm depth (total plug depth ~5-8 mm including articular cartilage) to reduce graft immunogenicity and to promote incorporation. (4) The bone is prepared with grooves/beveling to decrease impaction forces, increase access to subchondral deep zones during preparation, and promote graft-host interface healing. (5) High-pressure pulsed lavage is used to reduce antigenicity by removing marrow elements. (6) Pressurized carbon dioxide following pulsed lavage further reduces marrow elements and improves graft porosity for orthobiologic incorporation. (7) Orthobiologic substances (e.g., concentrated bone marrow aspirate) may enhance incorporation on imaging and result in greater osteogenic potential. (8) A suture is placed behind the graft to facilitate removal and repositioning; atraumatic graft insertion without high impaction forces maintains chondrocyte viability. These evidence-based pearls for osteochondral allograft handling optimize metabolic activity, reduce thermal necrosis, reduce antigenicity with removal of marrow elements, enhance biologic potential, and maintain chondrocyte viability to optimize biologic healing and clinical success.

Osteochondral allograft transplantation is a versatile solution for the treatment of symptomatic chondral or osteochondral defects of the knee. This cartilage-restoration treatment is particularly useful for deep and larger osteochondral lesions with extensive subchondral edema and obviates the concern for donor-site morbidity. However, successful allograft plug osseointegration is critical for success. The purpose of this Technical Note is to highlight the authors' experience and data to provide pearls to maximize biologic healing and clinical success for osteochondral allograft transplantation.

Surgical Technique (With Video Illustration)

The key pearls are demonstrated in [Video 1](#) and summarized in [Table 1](#).

Step 1: Gradual Graft Rewarming

A fresh, cold-preserved osteochondral allograft is used. It is important to note that cold preservation of the graft suppresses metabolic activity of chondrocytes. Gradual rewarming of the allograft results in increased proteoglycan synthesis and decreases nitrate/nitrite production relative to abrupt re-warming.¹ Therefore,

From Midwest Orthopaedics at Rush University, Chicago, Illinois, U.S.A.

The authors report the following potential conflicts of interest or sources of funding: A.B.Y. reports grants from Arthrex and Organogenesis, outside the submitted work, and consulting fees from Joint Restoration Foundation, Stryker, and AlloSource; payments for education events from Stryker; stock or stock options from Patient IQ and Icarus, and participation from advisory board for Sparta, Stryker. B.J.C. reports other from Aesculap/B. Braun; personal fees, nonfinancial support, and other from Arthrex; personal fees from Bandgrip and Elsevier Publishing; other from JRF Ortho and National Institutes of Health (National Institute of Arthritis and Musculoskeletal and Skin Diseases and Eunice Kennedy Shriver National Institute of Child Health and Human Development); personal fees and other from Operative Techniques in Sports Medicine; personal fees from Osslo; and other from Smith & Nephew, outside the submitted work. All other authors declare that they have no known competing financial interests or personal relationships

that could have appeared to influence the work reported in this paper. Full ICMJE author disclosure forms are available for this article online, as supplementary material.

This presentation was selected as the Best Orthoregeneration Pearl & Technique in the category of Cartilage Repair and Restoration at the Arthroscopy Association of North America (AANA) 2023 conference in conjunction with the Orthoregeneration Network (ON) Foundation.

Received June 10, 2023; accepted July 30, 2023.

© 2023 THE AUTHORS. Published by Elsevier Inc. on behalf of the Arthroscopy Association of North America. This is an open access article under the CC BY-NC-ND license (<http://creativecommons.org/licenses/by-nc-nd/4.0/>).

2212-6287/23827

<https://doi.org/10.1016/j.eats.2023.07.056>

Table 1. Summary of the Authors' Key Pearls for Osteochondral Allograft Transplantation

Pearl/Step	Technique	Purpose/Benefit
1) Gradual graft rewarming	Warm the fresh cold-preserved allograft in room temperature saline.	- Reverse metabolic suppression and improve metabolic activity
2) Submerged graft harvest	Ream the graft while submerged in saline.	- Decrease nitric oxide formation
3) Optimize subchondral bone depth	Aim for a total plug depth of 5-8 mm including the articular cartilage surface (or 4-6 mm of subchondral bone depth).	- Reduce thermal necrosis
4) Bone preparation	Chamfer bony edges and create grooves within subchondral bone with small oscillating saw.	- Maintain chondrocyte viability
5) Pulsed lavage	Apply high-pressure pulsed lavage of normal saline to the subchondral bone of the graft for up to two minutes.	- Reduce antigenicity
6) CO ₂ preparation	Apply pressurized CO ₂ to the subchondral bone of the graft.	- Improve graft porosity
7) Orthobiologic application	Apply an orthobiologic substance such as concentrated bone marrow aspirate to the subchondral bone.	- Reduce antigenicity
8) Rescue suture and minimizing impaction loads	Place a rescue suture behind the graft during insertion. Insert the donor graft plug into the recipient socket with manual pressure, limiting the use of a mallet if possible.	- Improve graft porosity
		- Enhance incorporation
		- Reduce large cysts on imaging
		- Decrease subsequent surgeries
		- Atraumatic graft removal
		- Easier graft manipulation
		- Maintain chondrocyte viability

CO₂, carbon dioxide.

the authors suggest warming the allograft in room-temperature saline (Fig 1).

Step 2: Submerged Graft Harvest

Thermal energy is harmful to the chondrocytes. Traditionally, bulb irrigation has been used to limit thermal necrosis during graft preparation with power tools such as the reamer or saw. The authors now

harvest their allograft plug while the whole allograft is submerged in saline (Fig 2). Our unpublished cellular analysis demonstrates that submerging the graft improves cartilage cell viability relative to traditional bulb irrigation (72% whole plug chondrocyte viability submerged harvest vs 61% whole plug chondrocyte viability bulb irrigation harvest, $P = .003$; unpublished data).

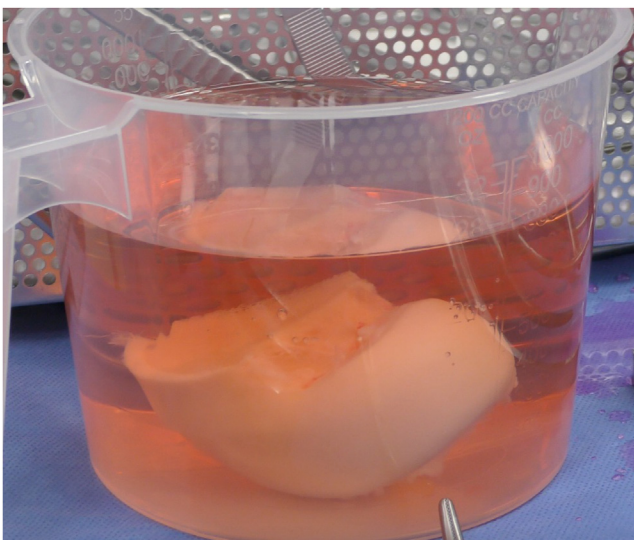


Fig 1. The fresh, cold-preserved osteochondral allograft is gradually rewarmed in room temperature saline to optimize metabolic activity.

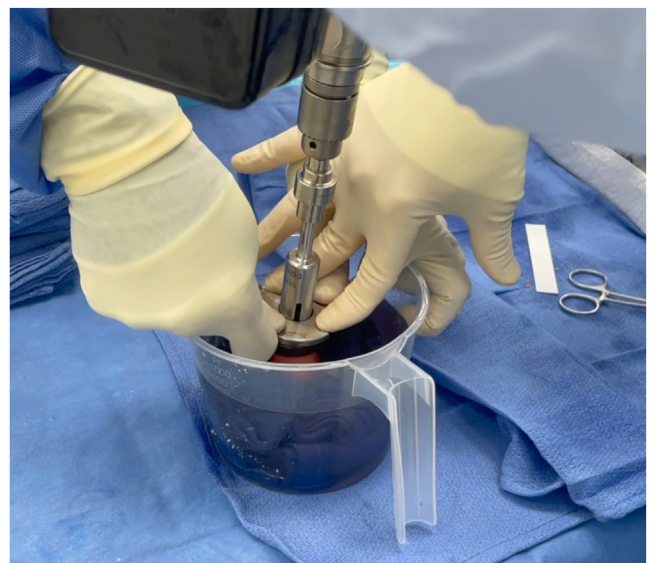
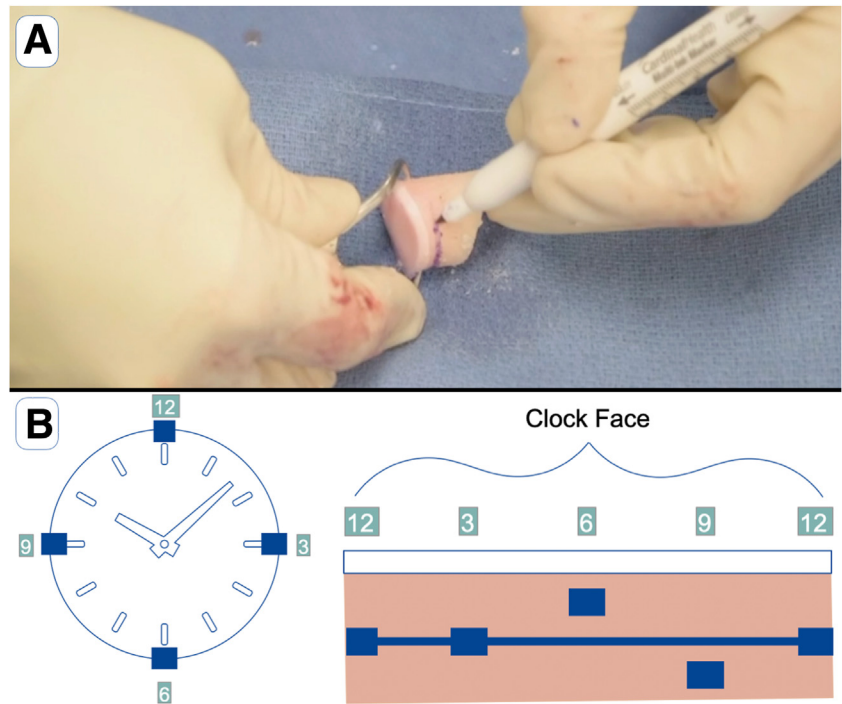


Fig 2. The plug is harvested with the reamer from the allograft while the whole allograft is submerged in saline to preserve chondrocyte viability.

Fig 3. The authors aim for a total plug depth of 5-8 mm including the articular surface. (A) The plug is oriented and the desired depth is marked. (B) Care is taken to understand how the depth of the plug may vary in each of the 12-, 3-, 6-, and 9-o'clock positions for proper orthogonal graft placement.



Step 3: Optimize Subchondral Bone Depth

The depth of the plug is important to optimize. The subchondral bone is known to be the most immunogenic portion of the graft and does not necessarily heal with full creeping substitution.² Having a plug that is deep will increase the immunogenicity. Deeper bone plugs on the graft side also make it more challenging to later access the deep zones of the graft during graft preparation techniques.^{3,4} However, grafts that are too shallow (i.e., less than 4-5mm of depth) may also be associated with increased cyst formation.⁵

Taking these data into consideration, the authors aim for a total plug depth of 5-8 mm, including the articular cartilage surface (Fig 3). We aim for this depth throughout the graft at each of the 12-, 3-, 6-, and 9-o'clock positions. We mark the 12-o'clock position on the graft to maintain graft orientation. Graft depth in each position may be more uniform on the femoral condyles; however, on the trochlear and patellar surfaces, the depth may vary greater throughout the graft boundaries (Fig 3). Maintaining graft orientation is critical to place it orthogonally to allow for a flush articular surface.

Step 4: Bone Preparation

The authors prepare the bone using a small oscillating saw. The bone edges may be chamfered along the perimeter. Small grooves are also created within the subchondral bone (Fig 4). The goal of the bony preparation is to facilitate graft insertion via decreased impaction forces, improve access to the deep zones

during subsequent graft preparation to remove marrow elements, and facilitate graft removal if necessary.

Step 5: Pulsed Lavage

High-pressure pulsed lavage of normal saline is used to cleanse the osteochondral allograft plug (Fig 5). Data

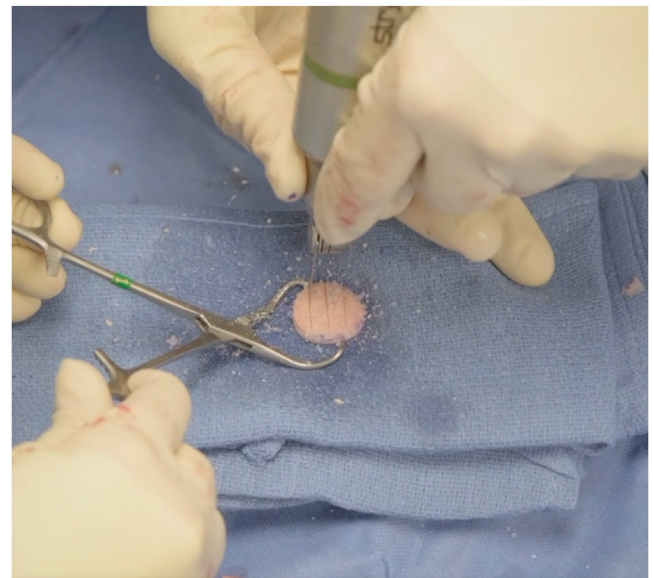

Fig 4. The bone is prepared with a small oscillating saw. The edges of the bone may be chamfered to ease graft insertion. The authors place several small grooves within the bone to facilitate graft insertion and increase access to deep subchondral bone zones of the graft during subsequent graft preparation steps.

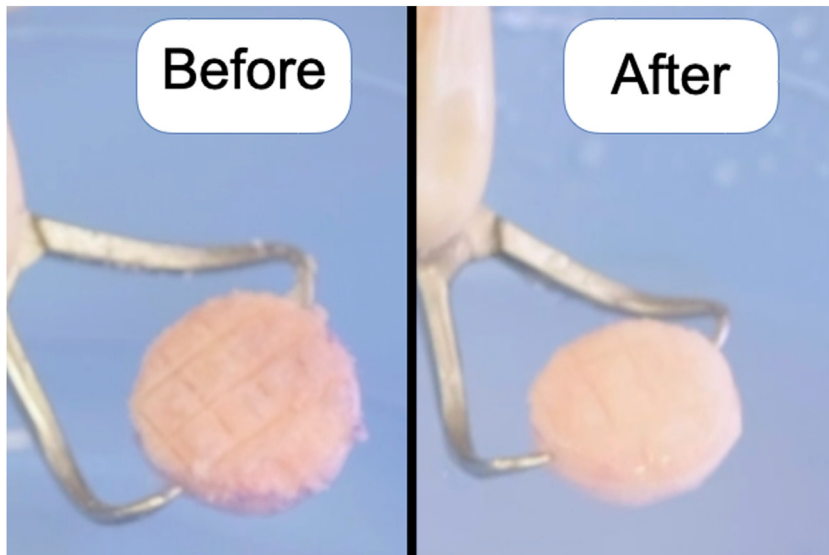


Fig 5. The graft is cleansed with high-pressure pulse lavage of normal saline to reduce immunogenic elements. There is often a visual change in color from before (left) to after (right) cleansing with pulse lavage.

suggest that for fresh osteochondral allografts, high-flow irrigation increases marrow space better than standard flow.⁶ Furthermore, there is ongoing reduction in marrow elements for up to 2 minutes of pulsed lavage.⁶ The pulsed lavage is focused on the subchondral bone portion of the graft.

Step 6: Carbon Dioxide (CO₂) Preparation

Following pulsed lavage with normal saline, the authors use pressurized CO₂ on the subchondral bone of the graft (CarboJet CO₂ Bone Preparation System; Kinamed Inc., Camarillo, CA) (Fig 6). Pressurized CO₂ significantly improves the removal of immunogenic marrow elements from osteochondral allografts when combined with pulsed lavage, relative to pulsed lavage alone.⁴ This enhanced effect is seen in each of the superficial, middle, and deep zones of the subchondral bone.⁴

Step 7: Orthobiologic Application

Cleansing the subchondral bone of marrow elements with the high-pressure pulsed lavage and pressurized CO₂ reduces the percent fill of the subchondral bone space and improves porosity.⁴ These steps also allow for improved incorporation and more uniform and deeper absorption of orthobiologic substances such as concentrated bone marrow aspirate (Fig 7).

When possible, the authors prefer to use concentrated bone marrow aspirate⁷ to provide factors thought to improve healing and incorporation. A currently unpublished study has demonstrated that patients receiving concentrated bone marrow aspirate applied to the subchondral bone of the osteochondral allograft plug have a reduction in large cysts on postoperative imaging.⁸ Furthermore, those with concentrated bone marrow aspirate had a significantly lower rate of subsequent surgeries for persistent or new symptoms

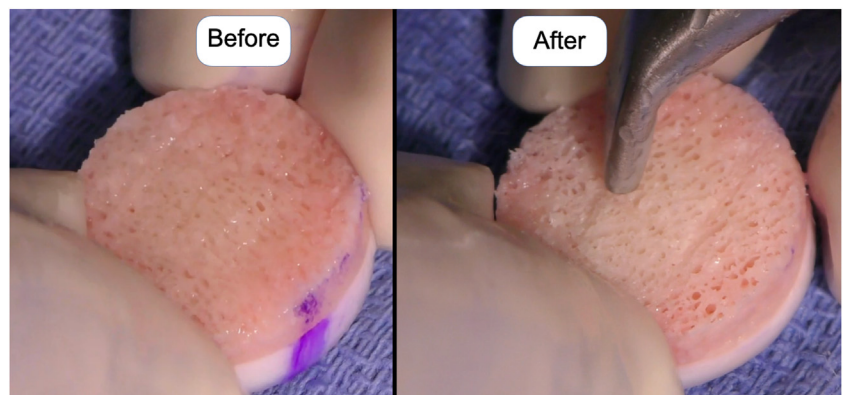


Fig 6. Pressurized carbon dioxide is applied to the subchondral bone of the allograft to further reduce immunogenic marrow elements throughout the subchondral bone depth after pulsed lavage with saline. There is often a visual change in color from before (left) to after (right) use of pressurized carbon dioxide, with a visual improvement in porosity.




Fig 7. After pulsed lavage and pressurized carbon dioxide, the graft is better prepared for orthobiologic substance application. Concentrated bone marrow aspirate application may reduce large cysts and decreased the rate of subsequent surgeries for ongoing symptoms. (A) Before application of concentrated bone marrow aspirate to subchondral bone that has been prepared with pulsed lavage and pressurized carbon dioxide. (B) After application of concentrated bone marrow aspirate to subchondral bone that was not prepared with pressurized carbon dioxide. There is less fluid uptake within the graft. (C) After application of concentrated bone marrow aspirate applied to subchondral bone that was prepared with both pulsed lavage and pressurized carbon dioxide. There is more uniform uptake of the fluid within the graft.

(5.3% subsequent surgeries with concentrated bone marrow aspirate vs 35.3% without, $P = .02$).⁸

Step 8: Rescue Suture and Minimizing Impaction Loads

When placing the donor graft into the recipient site, care is taken to limit impaction forces. Limiting impaction forces on the graft maintains cell viability. Studies demonstrate that greater impaction loads directly correlate with reduction in cell viability relative to controls.⁹

Therefore, the authors limit the use of a mallet to place the graft when possible. The graft is placed

gently using manual pressure. Furthermore, a rescue suture is placed behind the graft subchondral bone surface during graft placement (Fig 8). The suture allows for better control of the graft to fine-tune graft positioning for minimal force insertion. In addition, the suture provides a way to remove the graft if necessary. Table 1 summarizes the authors' pearls and their benefits.

Rehabilitation Protocol

Alterations in the rehabilitation protocol may be dictated by concomitant procedures. Postoperatively,

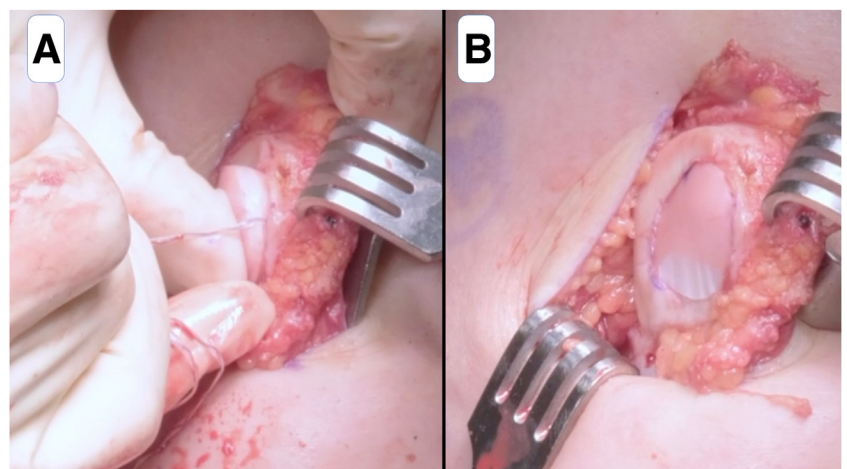


Fig 8. Minimal impaction force is used while placing the graft to maintain cell viability. The authors limit use of a mallet and utilize manual pressure when at all possible. A rescue suture is placed behind the graft to allow for better graft control and facilitates graft removal if necessary. (A) The donor patellar osteochondral allograft is placed within the recipient site on the patella with manual pressure while controlling the graft with the rescue suture. (B) The final osteochondral allograft plug sits within the patella.

patients are placed in a hinged knee brace. For isolated osteochondral allograft transplantation to the medial or lateral femoral condyle, patients are heel-touch weightbearing from postoperative weeks 0 to 6. Range of motion is advanced as tolerated. After week 6, patients transition to weight-bearing as tolerated and the goal is to achieve full range of motion. For patellofemoral (i.e., patellar or trochlear) osteochondral allograft transplantation, patients are permitted full weight-bearing as tolerated with the knee locked in extension from weeks 0-6.

Low-impact activities such as elliptical and swimming are permitted typically at 12 weeks' postoperatively. At 6 months postoperatively, functional activity is advanced and sport-specific activity and impact is permitted typically at approximately 8 months postoperatively.

Discussion

Osteochondral allograft transplantation has demonstrated reliable clinical success for appropriately indicated symptomatic osteochondral defects at mid-term¹⁰ and long-term follow-up.^{11,12} Although certain factors may increase risk of failure, such as number of previous surgical procedures, age, body mass index, and limb malalignment,^{10,13} numerous tools exist for the surgeon to optimize success after transplantation. Within the operating room, the goal of each step of the osteochondral allograft transplantation should be with ultimate biologic integration in mind.

In 2021, a study by the Metrics of Osteochondral Allografts (MOCA) Group published consensus statements on the use of viable osteochondral allografts.¹⁴ These statements are in concordance with the authors' recommendations. Specifically, the consensus statements included a similar optimal depth for femoral osteochondral allograft and using pulsed lavage on the bone before implantation.¹⁴ In addition to pulsed lavage, the authors advocate for use of pressurized CO₂ to further remove immunogenic elements and increase marrow space within the graft.⁴

Since the time of the publication of those statements, which had strong consensus for the statement "it is unknown whether osteochondral allograft bone incorporation can be enhanced by biologic adjuncts,"¹⁴ further research has been performed on the benefits of augmenting treatment with adjuncts such as concentrated bone marrow aspirate. Thus far, research suggests that concentrated bone marrow aspirate improves osseous integration with reduction in cysts and may improve pain scores and decrease failure rates.⁸ Furthermore, concentrated bone marrow aspirate may be better for osteogenic potential than platelet rich plasma.⁷ Further research in this area is ongoing, but the authors advocate for orthobiologic adjunct use (and preferably concentrated bone marrow aspirate) when

possible. Another statement with unanimous agreement was that "a standardized method for testing cartilage viability and metabolic activity should be established."¹⁴ Steps that the authors use with the goals of preserving metabolic activity and cell viability include gradual graft rewarming, reaming the graft while submerged in saline, preparing the bone for easier insertion, and using minimal impaction force when placing the graft into the socket.

The presented evidence-based pearls for osteochondral allograft handling and preparation optimize metabolic activity, reduce thermal necrosis, reduce antigenicity with removal of marrow elements, enhance biologic potential, and maintain chondrocyte viability to optimize biologic healing and clinical success.

References

1. Pylawka TK, Viridi AS, Cole BJ, Williams JM. Reversal of suppressed metabolism in prolonged cold preserved cartilage. *J Orthop Res* 2008;26:247-254.
2. Kandel RA, Gross AE, Ganel A, McDermott AG, Langer F, Pritzker KP. Histopathology of failed osteoarticular shell allografts. *Clin Orthop Relat Res* 1985;197:103-110.
3. Hunt HE, Sadr K, DeYoung AJ, Gortz S, Bugbee WD. The role of immunologic response in fresh osteochondral allografting of the knee. *Am J Sports Med* 2014;42:886-891.
4. Meyer MA, McCarthy MA, Gitelis ME, et al. Effectiveness of lavage techniques in removing immunogenic elements from osteochondral allografts. *Cartilage* 2017;8:369-373.
5. Ackermann J, Merkely G, Shah N, Gomoll AH. Decreased graft thickness is associated with subchondral cyst formation after osteochondral allograft transplantation in the knee. *Am J Sports Med* 2019;47:2123-2129.
6. Sun Y, Jiang W, Cory E, et al. Pulsed lavage cleansing of osteochondral grafts depends on lavage duration, flow intensity, and graft storage condition. *PLoS One* 2017;12:e0176934.
7. Stoker A, Baumann C, Stannard J, Cook J. Bone marrow aspirate concentrate versus platelet rich plasma to enhance osseous integration potential for osteochondral allografts. *J Knee Surg* 2018;31:314-320.
8. Yanke A, Dandu N, Bodendorfer B, et al. Paper 18: Effect of bone marrow aspirate concentrate on osteochondral allograft transplantation incorporation: A prospective, randomized, single blind investigation. *Orthop J Sports Med* 2022;10:2325967121S0058 (7_suppl 5).
9. Kang RW, Friel NA, Williams JM, Cole BJ, Wimmer MA. Effect of impaction sequence on osteochondral graft damage: The role of repeated and varying loads. *Am J Sports Med* 2010;38:105-113.
10. Frank RM, Lee S, Levy D, et al. Osteochondral allograft transplantation of the knee: Analysis of failures at 5 years. *Am J Sports Med* 2017;45:864-874.
11. Assenmacher AT, Pareek A, Reardon PJ, Macalena JA, Stuart MJ, Krych AJ. Long-term outcomes after osteochondral allograft: A systematic review at long-term follow-up of 12.3 years. *Arthroscopy* 2016;32:2160-2168.

12. Familiari F, Cinque ME, Chahla J, et al. Clinical outcomes and failure rates of osteochondral allograft transplantation in the knee: A systematic review. *Am J Sports Med* 2018;46:3541-3549.
13. Levy YD, Görtz S, Pulido PA, McCauley JC, Bugbee WD. Do fresh osteochondral allografts successfully treat femoral condyle lesions? *Clin Orthop Relat Res* 2013;471:231-237.
14. Görtz S, Tabbaa SM, Jones DG, et al. Metrics of Osteochondral Allografts (MOCA) Group Consensus Statements on the use of viable osteochondral allograft. *Orthop J Sports Med* 2021;9:2325967120983604.