



ELSEVIER

## Role of the superior labrum after biceps tenodesis in glenohumeral stability

Eric J. Strauss, MD, Michael J. Salata, MD, Robert A. Sershon, MD\*, Nickolas Garbis, MD, Matthew T. Provencher, MD, Vincent M. Wang, PhD, Kevin C. McGill, MD, Charles A. Bush-Joseph, MD, Gregory P. Nicholson, MD, Brian J. Cole, MD, Anthony A. Romeo, MD, Nikhil N. Verma, MD

Department of Orthopaedic Surgery, Rush University Medical Center, Chicago, IL, USA

**Background:** Little is known about the role that a torn superior labrum (SLAP) plays in glenohumeral stability after biceps tenodesis. This biomechanical study evaluated the contribution of a type II SLAP lesion to glenohumeral translation in the presence of biceps tenodesis. The authors hypothesize that subsequent to biceps tenodesis, a torn superior labrum does not affect glenohumeral stability and therefore does not require anatomic repair in an overhead throwing athlete.

**Methods:** Baseline anterior, posterior, and abduction and maximal external rotation glenohumeral translation data were collected from 20 cadaveric shoulders. Translation testing was repeated after the creation of anterior ( $n = 10$ ) and posterior ( $n = 10$ ) type II SLAP lesions. Translation re-evaluation after biceps tenodesis was performed for each specimen. Finally, anatomic SLAP lesion repair and testing were performed.

**Results:** Anterior and posterior SLAP lesions led to significant increases in glenohumeral translation in all directions ( $P < .0125$ ). Biceps tenodesis showed no significance in stability compared with SLAP alone ( $P > .0125$ ). Arthroscopic repair of anterior SLAP lesions did not restore anterior translation compared with the baseline state ( $P = .0011$ ) but did restore posterior ( $P = .823$ ) and abduction and maximal external rotation ( $P = .806$ ) translations. Repair of posterior SLAP lesions demonstrated no statistical difference compared with the baseline state ( $P > .0125$ ).

**Conclusions:** With no detrimental effect on glenohumeral stability in the presence of a SLAP lesion, biceps tenodesis may be considered a valid primary or revision surgery for patients suffering from symptomatic type II SLAP tears. However, biceps tenodesis should be considered with caution as the primary treatment of SLAP lesions in overhead throwing athletes secondary to its inability to completely restore translational stability.

**Level of evidence:** Basic Science Study, Biomechanics, Cadaver Model.

© 2013 Journal of Shoulder and Elbow Surgery Board of Trustees.

**Keywords:** Shoulder; superior labrum; SLAP; biceps tenodesis; glenohumeral kinematics

Funding for this study was through a grant awarded by Major League Baseball. Suture and suture anchors were donated by Smith & Nephew. Approval for this study was obtained from Rush University Medical Center Institutional Review Board (ORA # 09090101-IRB01).

\*Reprint requests: Robert A. Sershon, MD, 1611 W Harrison St, Suite 300, Chicago, IL 60612, USA.

E-mail address: bob.sershon@gmail.com (R.A. Sershon).

SLAP (superior labrum anterior-posterior) tears are associated with pain, shoulder instability, and significant glenohumeral dysfunction, especially in a throwing athlete. First described by Andrews et al<sup>1</sup> and later classified by Snyder et al,<sup>27</sup> SLAP tears have been noted to result from trauma or overuse.<sup>11,14,16,19,26</sup> Whereas SLAP lesions commonly occur in association with injuries to the rotator cuff, internal impingement, and glenohumeral instability, they may occur in isolation, acting as a primary source of shoulder pain and disability for the overhead athlete.<sup>4,8,10,20</sup>

At present, arthroscopic repair of unstable superior labral tears involving the long head of the biceps (LHB) anchor (type II SLAP lesions) has become the standard of operative care, resulting in good to excellent outcomes in the majority of published reports.<sup>4,14,21,26</sup> However, results of arthroscopic fixation in overhead throwing athletes have been less consistent, with clinical studies demonstrating a return to preinjury level of sports participation ranging from 22% to 84%.<sup>11,15,19</sup> Of 19 baseball players treated with arthroscopic suture anchor fixation of type II SLAP tears, Ide et al<sup>11</sup> reported that only 12 players (63%) had a complete return to play without pain or functional limitation at a mean follow-up of 3.5 years. It is believed that persistent pain after SLAP repair results in a loss of motion from rigidity and is the reason behind these low rates of return to overhead athletics.<sup>4,14</sup> A potential hypothesis for the high incidence of post-slap repair shoulder pain accounts for the rigidity of the suture anchor fixation with a consequent loss of physiologic motion at the labral-LHB anchor junction. Others theorize that the highly innervated proximal LHB tendon acts as the primary pain generator after injury or surgery. The low rates of return to play and the potential for continued symptoms postoperatively have led surgeons to look for alternative treatment methods for management of type II SLAP lesions.

Currently, little is known about the role that a torn superior labrum plays in glenohumeral stability after biceps tenodesis. The present biomechanical study evaluates the effects of a type II SLAP lesion on glenohumeral translation in the presence of a biceps tenodesis. We hypothesized that subsequent to biceps tenodesis, the presence of a torn superior labrum does not affect glenohumeral stability and therefore does not require anatomic repair in a throwing athlete with a type II SLAP lesion.

## Materials and methods

### Specimen preparation

Twenty-seven fresh-frozen cadaveric shoulders (mean age, 51.3 years; age range, 23-68 years; 20 men (74%), 7 women (26%); 14 left, 13 right) were stored at  $-20^{\circ}\text{C}$ . Before testing, each shoulder was thawed for 24 hours, then dissected free of skin and superficial muscle. The rotator cuff muscles were elevated from their scapular origin, and nylon sutures were attached to their muscle bellies in a grasping/locking suture configuration for uniform

loading. The LHB tendon was dissected distally to the level of the musculotendinous junction, where the tendon was transected and sutured with high-strength suture material (FiberWire #5; Arthrex, Naples, FL, USA) by grasping/locking sutures. The humeral shaft was potted into a cylindrical PVC pipe with polymethyl methacrylate and the scapula was rigidly fixed to a 4-mm-thick aluminum sheet with 3 stainless steel bolts in preparation for mounting to the shoulder testing apparatus.

Each specimen underwent an arthroscopic evaluation to assess for the presence of exclusion criteria, including full-thickness cuff tears, labral injuries, evidence of prior surgery, and osteoarthritis. Anatomic variants (sublabral foramen and Buford complex) were also excluded as several studies have indicated that anatomic variants of the anterosuperior labrum may alter intra-articular biomechanics and predispose the shoulder to labral disease.<sup>12,13,25,27,29</sup> In addition, reattachment of the Buford complex to the glenoid has been reported to restrict shoulder rotation.<sup>23</sup> In our study, 7 shoulders were excluded (6 anatomic variants and 1 rotator cuff tear).

### Shoulder testing apparatus


Specimens were mounted onto a custom shoulder testing apparatus for assessment of glenohumeral stability (Fig. 1).<sup>24</sup> The apparatus allowed for 6 degrees of freedom motion for the adjustment of the glenohumeral joint, enabling the specimen to be positioned anatomically such that the glenoid had a  $5^{\circ}$  superior inclination and neutral version. Once glenoid version was locked into place, the scapula was positioned such that the center of rotation of the glenohumeral joint coincided with the center of the apparatus. Once the center of rotation was determined, the scapula was locked into place and unchanged throughout testing.

The scapular plane was defined as a vertical plane perpendicular to the glenoid surface, parallel to the scapular mount. Abduction was defined as humeral motion in the scapular plane, and flexion was defined in the anatomic sagittal plane at an angle of  $60^{\circ}$  to the scapular plane.<sup>7</sup> The angle for glenohumeral abduction and flexion was set at  $60^{\circ}$ , corresponding to  $90^{\circ}$  of total arm abduction and flexion.<sup>9,24</sup> A total of 22 N of glenohumeral joint compression force was applied through tension on the rotator cuff muscles (supraspinatus = 3.5 N, infraspinatus/teres minor = 9.1 N, and subscapularis = 9.4 N) on the basis of muscle cross-sectional area data.<sup>3,28</sup> The LHB was anatomically loaded with 22 N of force based on the methods of previous biomechanical studies testing the impact of the LHB on glenohumeral kinematics.<sup>30</sup>

Surface markers affixed to the lateral aspect of the acromion, the lateral aspect of the humeral head, and the coracoid process enabled assessment of glenohumeral translation with a 3-dimensional scanner (NextEngine Inc., Santa Monica, CA, USA). This scanner has a resolution of 0.1 mm when it is used on the macro setting with the object of interest placed 165 mm from the scanner. Scans were viewed with the ScanStudio HD (NextEngine Inc.), and subsequent analysis was performed with this software.

### Glenohumeral translation testing

Protocol and loading of translation forces were previously described by Provencher et al<sup>24</sup> and Harryman et al.<sup>9</sup> Glenohumeral translation testing was performed for 4 separate, sequential conditions: baseline, type II anterior or posterior SLAP lesions, type II SLAP lesions with biceps tenodesis, and type II SLAP



**Figure 1** Custom shoulder testing apparatus. (A, B) The apparatus set up in neutral abduction for testing of anterior and posterior translation. (C) The shoulder set up in the ABER position.

lesions with both biceps tenodesis and SLAP repair. For anterior and posterior translations, the humerus was translated on the fixed scapula, with the translation force administered through a direct in-line pulley system loaded with 3.0 kg.

The testing sequence consisted of anterior translation at neutral rotation, posterior translation at neutral rotation, and anterior translation at 90° of abduction and maximal external rotation (ABER) (Fig. 1). Each specimen was scanned before and after each step in the testing sequence, with the difference between these two data points measured as the glenohumeral translation. The resting “zero” position of the loaded glenohumeral joint was re-established for each testing condition, confirming this position on the basis of the distances between the surface markers affixed to the specimen.

### Creation of a type II SLAP lesion

Once baseline translation data were collected for each specimen, an experimental type II SLAP lesion was created according to the protocol described by DiRaimondo et al.<sup>6</sup> Two different SLAP tear configurations were created in 10 specimens each (Fig. 2). In the first group of 10 shoulders, the superior labrum was sharply dissected free of the glenoid 5 mm medial to the glenoid rim, extending 7 mm from the posterior border of the LHB tendon to

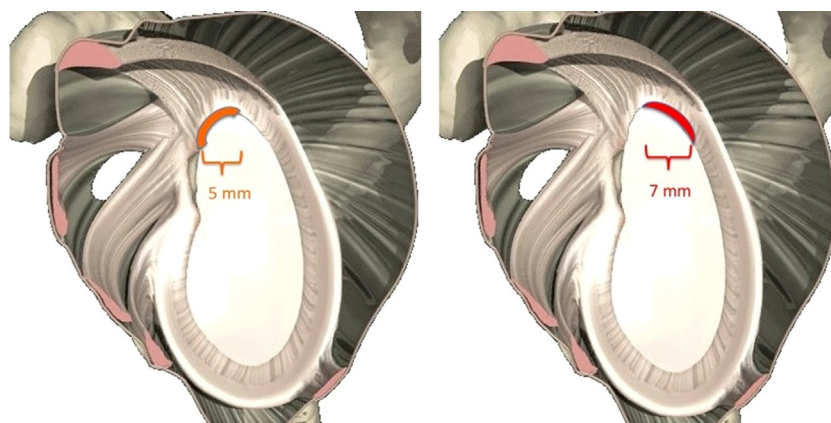
the anchor, creating an unstable posterosuperior labrum/biceps anchor complex. In the second group of 10 shoulders, the experimental SLAP tear was started at the posterior border of the LHB anchor, extending anteriorly to include the insertion of the superior glenohumeral ligament. Arthroscopic portals were then closed, and the specimen immediately underwent translational testing.

### Biceps tenodesis

Subsequent to the creation of the isolated type II SLAP lesion, each specimen then underwent biceps tenodesis by use of interference screw fixation as described by Mazzocca et al.<sup>17</sup> After arthroscopic biceps tenotomy, the tendon was pulled into an 8-mm socket drilled in the proximal humerus 1 cm below the superior border of the pectoralis major tendon, simulating an open sub-pectoralis tenodesis, and the tendon was fixed with an 8 × 12-mm PEEK interference screw (Biceptor; Smith & Nephew, Andover, MA, USA).

### SLAP repair

For the final testing condition, the SLAP lesion was repaired to the glenoid rim by suture anchor fixation (2.3 Bioraptor PK; Smith &



**Figure 2** Experimental creation of SLAP lesion. In the first group of 10 shoulders, the superior labrum was sharply dissected free of the glenoid 5 mm medial to the glenoid rim, extending 7 mm from the posterior border of the long head of the biceps tendon to the anchor, creating an unstable posterosuperior labrum/biceps anchor complex. In the second group of 10 shoulders, the experimental SLAP tear was started at the posterior border of the long head of the biceps anchor, extending anteriorly to include the insertion of the superior glenohumeral ligament.

Nephew). For the posterior SLAP configuration, 2 suture anchors were inserted, one at the 10-o'clock position and the other at the 11:30 position for a right shoulder. Specimens from the anterior SLAP configuration group had the tears fixed with 1 suture anchor placed at the 12:30 and 2-o'clock positions for a right shoulder. A single stitch from each anchor was placed around the labrum and tied with an arthroscopic knot, securing the labrum to the glenoid.

### Statistical methods

Mean translation data were compared between groups (baseline, isolated type II SLAP lesion, isolated type II SLAP lesion treated with biceps tenodesis, and type II SLAP lesion treated with biceps tenodesis and suture anchor fixation) for both the anterior and posterior SLAP lesions by use of a repeated measures one-way analysis of variance (ANOVA). In accordance with pretesting planned statistical comparisons, post-hoc Bonferroni correction was used, setting the level of significance at  $P < .0125$  because of the use of the 4 pairwise comparisons of greatest clinical interest. The pairwise comparisons included baseline to SLAP lesion, SLAP lesion to biceps tenodesis, biceps tenodesis to arthroscopic repair, and baseline to repair.

For a repeated measures one-way ANOVA design to achieve 80% power with an effect size of 1.2 (deemed clinically significant from our pilot experiments) and  $\alpha = .05$  for detection of significant differences in anterior translation among the 4 test conditions (intact, SLAP tear, biceps tenodesis, and final repair), 10 shoulders were required for each of the SLAP lesion experiments.

### Results

For specimens in the anterior SLAP cohort, anterior translation in neutral significantly increased from a mean of 5.4 mm to 9.3 mm ( $P < .0001$ ) and posterior translation in neutral significantly increased from 6.8 mm to 8.9 mm ( $P = .0120$ ) after creation of the experimental lesion. In ABER, a significant increase in anterior translation was noted in anterior SLAP specimens, increasing from 3.4 mm at baseline to

4.8 mm in the lesion state ( $P = .003$ ). Specimens in the posterior SLAP cohort demonstrated significant differences in neutral anterior and posterior translations, increasing from 6.2 mm to 10.6 mm ( $P < .0001$ ) and from 6.5 mm to 9.9 mm ( $P < .0001$ ), respectively. In the ABER position, a significant increase in anterior translation was noted from 4.7 mm to 7.7 mm ( $P < .001$ ) (Fig. 3).

Among both anterior and posterior SLAP specimens, biceps tenodesis did not significantly affect anterior glenohumeral translation compared with the lesion state. In the anterior SLAP specimens, the anterior translation was unchanged at 9.3 mm ( $P = .999$ ). Posterior translation decreased to 8.3 mm ( $P = .759$ ), and ABER translation decreased to 4.1 mm ( $P = .374$ ). For the posterior SLAP specimens after tenodesis, anterior translation decreased to 8.9 mm ( $P = .129$ ), posterior translation decreased to 9.2 mm ( $P = .591$ ), and ABER translation decreased to 5.7 mm ( $P = .045$ ) (Fig. 3).

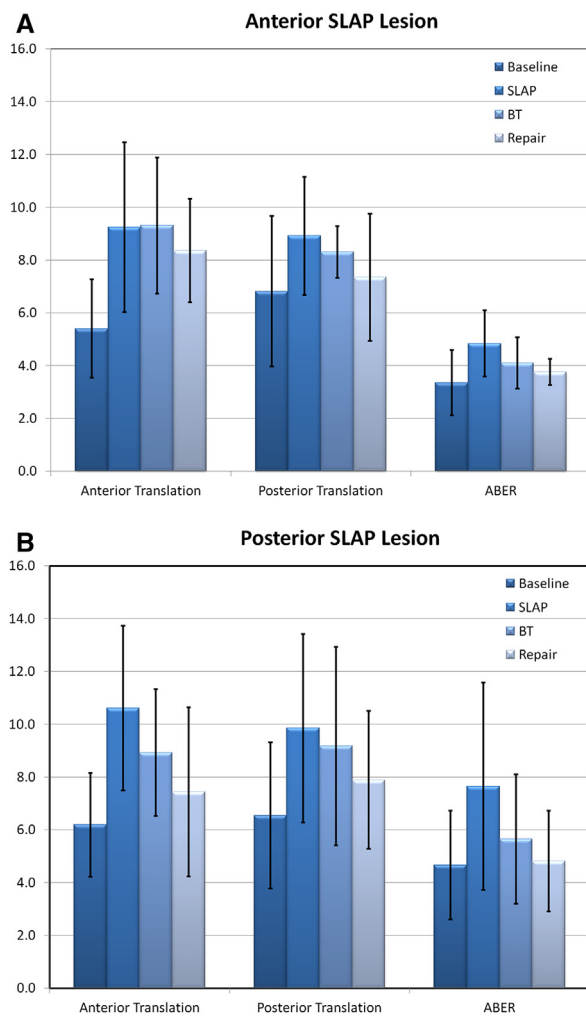
After repair of anterior SLAP specimens, anterior and posterior translations decreased to 8.4 mm and 7.4 mm ( $P = .521$ ; .439), respectively. Mean ABER translation after repair was 3.8 mm ( $P = .874$ ). Among posterior SLAP specimens, SLAP repair after biceps tenodesis decreased anterior translation to 7.4 mm ( $P = .209$ ) and decreased posterior translation to 7.9 mm ( $P = .104$ ). After repair, ABER translation decreased to 4.8 mm ( $P = .641$ ) (Fig. 3).

No statistical significance was noted in the comparisons of glenohumeral translation between the baseline state and the repaired state, with the exception of anterior SLAP specimens in anterior translation only (5.4 mm to 8.4 mm;  $P = .001$ ) (Fig. 3 and Table I).

### Discussion

In the current study, experimental type II SLAP lesions led to increases in glenohumeral translation across all parameters





**Figure 3** (A, B) Effect of experimental SLAP lesion on glenohumeral translation. \*Significant increase in translation between the baseline specimens and the SLAP lesion state. \*\*Significant increase in translation between the baseline specimens and the repaired SLAP lesion state. ABER, abduction and maximal external rotation; BT, biceps tenodesis.

for both anterior and posterior SLAP specimens. No significant difference in translation was noted between the lesion state and that seen after biceps tenodesis. Whereas biceps tenodesis did not restore glenohumeral translation in the setting of a type II SLAP lesion, it did not have a deleterious effect on stability. In our model, arthroscopic repair of the experimental SLAP lesion did not restore anterior translation to baseline values after repair of anterior type II SLAP lesions. However, repair of posterior lesions restored anterior and posterior translations to within 1.2 mm and 1.4 mm of baseline, respectively. A nearly complete restoration (within 0.4 mm) of ABER translation in both anterior and posterior SLAP states was also seen when labral repair was used.

We believe that our findings support the concept of capsular pseudolaxity associated with type II SLAP lesions reported by Morgan<sup>19</sup> and Andrews,<sup>2</sup> especially in the setting

of an anterior SLAP lesion in which injury to the superior glenohumeral ligament is coexistent with that occurring to the superior labrum. This “circle concept” of the superior labral complex postulates that disruption of one portion of the superior labrum results in instability on the opposite side of the glenoid.<sup>19</sup> In their series of 102 type II SLAP lesions without associated anterior instability, Morgan et al<sup>19</sup> found a secondary anterior-inferior pseudolaxity manifesting as an arthroscopic drive-through sign in the presence of posterior lesions, which was eliminated after SLAP repair. In our model, the capsular pseudolaxity produced by the presence of the experimental type II SLAP lesion was accentuated in the cohort of specimens in which the SLAP tear involved the insertion of the superior glenohumeral ligament anteriorly. In these specimens, persistent instability remained despite both biceps tenodesis and arthroscopic labral repair. This suggests that improved repair techniques are necessary or that in addition to reapproximation of the superior labrum to its anatomic position on the glenoid, attention should be paid to tensioning the superior glenohumeral ligament and anterior capsule as described by Andrews and Dugas.<sup>2</sup> In their series of throwing athletes with SLAP tears, 73% of those who were treated with thermal shrinkage of the anterior capsule in addition to SLAP repair were competing at 2 years of follow-up in contrast to 50% of those who underwent isolated repair without addressing the anterior capsule.<sup>2</sup>

Biomechanical studies have attempted to elucidate the effects of superior labral lesions on glenohumeral stability with varying results. Pagnani et al,<sup>21</sup> in their cadaveric study, reported that isolated lesions to the anterosuperior aspect of the superior labrum, not involving the LHB, had no significant impact on anterior-posterior glenohumeral translation both with and without loading of the LHB tendon. Extension of their experimental lesions posteriorly to include the LHB anchor led to significant increases in anterior-posterior translation both with and without loading of the LHB tendon, with translation values similar to those seen in the current model. Comparable significant increases in anterior-posterior translation measurements after creation of type II SLAP lesions were also found in a study by Panossian et al,<sup>22</sup> in which the authors evaluated the effects of type II SLAP tears on glenohumeral rotation and translation in 6 cadaveric shoulders. The authors also reported complete restoration of translation parameters on repair of both the anterior- and posterior-based SLAP lesions. Although a trend toward global restoration of translation measurements was seen in the current study, anterior translation values for anterior-based tears were not restored to baseline. Studies by Burkhart et al<sup>5</sup> and McMahon et al<sup>18</sup> also reported significant increases in glenohumeral translation after simulated type II SLAP lesions. Their baseline and lesion translation values were larger than those seen in the current study, probably secondary to their lack of simulating LHB activity. Yet, similar to our findings of persistent anterior instability in anterior-based type II SLAP lesions, arthroscopic repair of the SLAP lesions in

**Table I** Mean averages and standard deviation of anterior-based and posterior-based SLAP specimens

	Anterior SLAP			Posterior SLAP			
	Anterior translation (mm)	Posterior translation (mm)	ABER (mm)	Anterior translation (mm)	Posterior translation (mm)	ABER (mm)	
Baseline	5.4 ± 1.9	6.8 ± 2.8	3.4 ± 1.2	Baseline	6.2 ± 2.0	6.5 ± 2.8	4.7 ± 2.0
SLAP	9.3 ± 3.2	8.9 ± 2.2	4.8 ± 1.2	SLAP	10.6 ± 3.1	9.9 ± 3.6	7.7 ± 3.9
BT	9.3 ± 2.6	8.3 ± 1.0	4.1 ± 1.0	BT	8.9 ± 2.4	9.2 ± 3.7	5.7 ± 2.4
Repair	8.4 ± 2.0	7.4 ± 2.4	3.8 ± 0.5	Repair	7.4 ± 3.2	7.9 ± 2.6	4.8 ± 1.9

ABER, abduction and maximal external rotation; BT, biceps tenodesis.

the 2003 Burkhart study only partially restored glenohumeral translation stability. To our knowledge, however, no previous biomechanical study has reported solely anterior instability in the setting of repaired anterior-based SLAP lesions.

We believe that the lack of a negative effect of biceps tenodesis on glenohumeral stability demonstrated in the current study lends its use to the armamentarium for management of SLAP lesions, supporting the findings reported by Boileau et al<sup>4</sup> in a study comparing outcomes of 10 patients treated with arthroscopic repair (age, 37 years; range, 19-57 years) with those of 15 patients (age, 52 years; range, 28-64 years) managed with biceps tenodesis. The authors found that although 60% of the patients treated with SLAP repair were unsatisfied with their outcome secondary to persistent pain or inability to return to their previous level of athletic participation, 93% of those treated with biceps tenodesis were satisfied, with 87% returning to their preinjury level of sports. The authors concluded that biceps tenodesis was an effective repair alternative in the treatment of type II SLAP lesions. Although this study represented an older patient population of recreational athletes and no overhead throwers, the clinical data suggest the LHB as a pain generator in the setting of superior labral tears and that LHB tenodesis results in improved clinical outcomes in comparison to labral repair. Especially among recreational athletes, eliminating this potential pain generator without having a detrimental effect on stability may help increase the percentage of patients returning to symptom-free play after type II SLAP tears. However, on the basis of our data, biceps tenodesis should be considered with caution as the primary treatment of SLAP lesions in the elite overhead throwing athlete secondary to its inability to completely restore normal translational stability. Although the current study reports ABER translation (which most closely simulates the cocking phase of overhead throwing) to be restored within 0.4 mm after labral repair for both SLAP subgroups, anterior instability remained in specimens with anterior-based SLAP tears. Therefore, in patients who may require restoration of normal glenohumeral kinematics for maximal shoulder function, anatomic SLAP repair with attention paid to the anterior capsule may be the most appropriate initial treatment approach.

Similar conclusions were reported in a clinical study by Provencher et al.<sup>23</sup> The findings showed excellent outcomes in a subgroup of active military patients younger than 40 years who underwent primary repair for type II SLAP lesions, suggesting primary SLAP repair as the recommended treatment for younger patients with high athletic demands. However, the group older than 40 years was found to have a higher failure rate with primary SLAP repair, specifically a 3.45 relative risk of failure for those older than 36 years. The authors concluded that in older athletes with type II SLAP tears, the surgeon should discuss the risks of type II SLAP repair versus biceps tenodesis at the initial surgery. In both groups, biceps tenodesis was the most common revision procedure (42 of 44 cases).

The limitations of the current study include those inherent in a cadaveric model of simulated shoulder injuries. The time-zero cadaveric model does not allow the recreation of the multiple dynamic components of glenohumeral stability that are present in vivo and represents an oversimplification of the complex injury mechanism that results in SLAP tears in the clinical scenario. In addition, our model does not take into account healing potential. Potential effects of repetitive testing must also be considered, although care was taken to preserve the specimen throughout testing. The simulated type II SLAP lesions created were produced by sharply cutting the superior labrum from its glenoid attachment, probably oversimplifying the complex mechanism that results in these lesions clinically. In addition, no direct comparison to SLAP repair with biceps intact was made during this study.

## Conclusion

In the current cadaveric biomechanical study, experimental type II SLAP lesions produced increases in anterior, posterior, and ABER translations compared with baseline. Biceps tenodesis did not fully restore baseline translation values but did not have a negative effect on glenohumeral stability compared with the SLAP state. Posterior SLAP lesions were effectively treated with arthroscopic repair, whereas persistent

increased anterior translation was present after the repair of anterior SLAP lesions in this cadaveric model. With no detrimental effect on glenohumeral stability in the presence of a SLAP lesion, biceps tenodesis may be considered a valid primary or revision surgery for patients suffering from symptomatic type II SLAP tears. However, on the basis of our data, biceps tenodesis should be considered with caution as the primary treatment of SLAP lesions in the elite overhead throwing athlete secondary to its inability to completely restore normal translational stability.

## Disclaimer

The authors, their immediate families, and any research foundations with which they are affiliated have not received any financial payments or other benefits from any commercial entity related to the subject of this article.

## References

- Andrews JR, Carson WG, McLeod WD. Glenoid labrum tears related to the long head of the biceps. *Am J Sports Med* 1985;13:337-41.
- Andrews JR, Dugas JR. Diagnosis and treatment of shoulder injuries in the throwing athlete: the role of thermal-assisted capsular shrinkage. *Instr Course Lect* 2001;50:17-21.
- Blasier RB, Soslowky LJ, Malicky DM, Palmer ML. Posterior glenohumeral subluxation: active and passive stabilization in a biomechanical model. *J Bone Joint Surg Am* 1997;79:433-40.
- Boileau P, Parratte S, Chuinard C, Roussanne Y, Shia D, Bicknell R. Arthroscopic treatment of isolated type II SLAP lesions: biceps tenodesis as an alternative to reinsertion. *Am J Sports Med* 2009;37:929-36. <http://dx.doi.org/10.1177/0363546508330127>
- Burkart A, Debski RE, Musahl V, McMahon PJ. Glenohumeral translations are only partially restored after repair of a simulated type II superior labral lesion. *Am J Sports Med* 2003;31:56-63.
- DiRaimondo CA, Alexander JW, Noble PC, Lowe WR, Lintner DM. A biomechanical comparison of repair techniques for type II SLAP lesions. *Am J Sports Med* 2004;32:727-33. <http://dx.doi.org/10.1177/0095399703258751>
- Gerber C, Werner CM, Macy JC, Jacob HA, Nyffeler RW. Effect of selective capsulorrhaphy on the passive range of motion of the glenohumeral joint. *J Bone Joint Surg Am* 2003;85:48-55.
- Grauer JD, Paulos LE, Smutz WP. Biceps tendon and superior labral injuries. *Arthroscopy* 1992;8:488-97.
- Harryman DT, Sidles JA, Harris SL, Matsen FA 3rd. The role of the rotator interval capsule in passive motion and stability of the shoulder. *J Bone Joint Surg Am* 1992;74:53-66.
- Ide J, Maeda S, Takagi K. Arthroscopic Bankart repair using suture anchors in athletes: patient selection and postoperative sports activity. *Am J Sports Med* 2004;32:1899-905. <http://dx.doi.org/10.1177/0363546504265264>
- Ide J, Maeda S, Takagi K. Sports activity after arthroscopic superior labral repair using suture anchors in overhead-throwing athletes. *Am J Sports Med* 2005;33:507-14. <http://dx.doi.org/10.1177/0363546504269255>
- Ilahi OA, Labbe MR, Cosculluela P. Variants of the anterosuperior glenoid labrum and associated pathology. *Arthroscopy* 2002;18:882-6. <http://dx.doi.org/10.1053/jars.2002.36119>
- Kanatli U, Ozturk BY, Bolukbasi S. Anatomical variations of the anterosuperior labrum: prevalence and association with type II superior labrum anterior-posterior (SLAP) lesions. *J Shoulder Elbow Surg* 2010;19:1199-203. <http://dx.doi.org/10.1016/j.jse.2010.07.016>
- Kim SH, Ha KI, Choi HJ. Results of arthroscopic treatment of superior labral lesions. *J Bone Joint Surg Am* 2002;84:981-5.
- Kim TK, Queale WS, Cosgarea AJ, McFarland EG. Clinical features of the different types of SLAP lesions: an analysis of one hundred and thirty-nine cases. *J Bone Joint Surg Am* 2003;85:66-71.
- Maffet MW, Gartsman GM, Moseley B. Superior labrum-biceps tendon complex lesions of the shoulder. *Am J Sports Med* 1995;23:93-8.
- Mazzocca AD, Rios CG, Romeo AA, Arciero RA. Subpectoral biceps tenodesis with interference screw fixation. *Arthroscopy* 2005;21:896. <http://dx.doi.org/10.1016/j.arthro.2005.04.002>
- McMahon PJ, Burkart A, Musahl V, Debski RE. Glenohumeral translations are increased after a type II superior labrum anterior-posterior lesion: a cadaveric study of severity of passive stabilizer injury. *J Shoulder Elbow Surg* 2004;13:39-44. <http://dx.doi.org/10.1016/j.jse.2003.09.004>
- Morgan CD, Burkhart SS, Palmeri M, Gillespie M. Type II SLAP lesions: three subtypes and their relationships to superior instability and rotator cuff tears. *Arthroscopy* 1998;14:553-65.
- Musgrave DS, Rodosky MW. SLAP lesions: current concepts. *Am J Orthop* 2001;30:29-38.
- Pagnani MJ, Speer KP, Altchek DW, Warren RF, Dines DM. Arthroscopic fixation of superior labral lesions using a biodegradable implant: a preliminary report. *Arthroscopy* 1995;11:194-8.
- Panossian VR, Mihata T, Tibone JE, Fitzpatrick MJ, McGarry MH, Lee TQ. Biomechanical analysis of isolated type II SLAP lesions and repair. *J Shoulder Elbow Surg* 2005;14:529-34. <http://dx.doi.org/10.1016/j.jse.2004.11.002>
- Provencher MT, McCormick F, Dewing C, McIntire S, Solomon D. A prospective analysis of 179 type 2 superior labrum anterior and posterior repairs: outcomes and factors associated with success and failure. *Am J Sports Med* 2013;41:880-6. <http://dx.doi.org/10.1177/0363546513477363>
- Provencher MT, Mologne TS, Hongo M, Zhao K, Tasto JP, An KN. Arthroscopic versus open rotator interval closure: biomechanical evaluation of stability and motion. *Arthroscopy* 2007;23:583-92. <http://dx.doi.org/10.1016/j.arthro.2007.01.010>
- Rao AG, Kim TK, Chronopoulos E, McFarland EG. Anatomical variants in the anterosuperior aspect of the glenoid labrum: a statistical analysis of seventy-three cases. *J Bone Joint Surg Am* 2003;85:653-9.
- Snyder SJ, Banas MP, Karzel RP. An analysis of 140 injuries to the superior glenoid labrum. *J Shoulder Elbow Surg* 1995;4:243-8.
- Snyder SJ, Karzel RP, Del Pizzo W, Ferkel RD, Friedman MJ. SLAP lesions of the shoulder. *Arthroscopy* 1990;6:274-9.
- Warner JJ, Deng XH, Warren RF, Torzilli PA. Static capsuloligamentous restraints to superior-inferior translation of the glenohumeral joint. *Am J Sports Med* 1992;20:675-85.
- Williams MM, Synder SJ, Buford D. The Buford complex—the "cord-like" middle glenohumeral ligament and absent anterosuperior labrum complex: a normal anatomic capsulolabral variant. *Arthroscopy* 1994;10:241-7.
- Youm T, ElAttrache NS, Tibone JE, McGarry MH, Lee TQ. The effect of the long head of the biceps on glenohumeral kinematics. *J Shoulder Elbow Surg* 2009;18:122-9. <http://dx.doi.org/10.1016/j.jse.2008.06.003>