

“Most study results have shown encouraging outcomes after SCR in patients with these complex conditions...”

Update on Superior Capsular Reconstruction

Clinical Outcomes and Analysis of Failures

RON GILAT, MD / ERIC D. HAUNSCHILD, BS / BRADY T. WILLIAMS, MD / NOLAN CONDRON, BS / MICHAEL C. FU, MD
GRANT E. GARRIGUES, MD / ANTHONY ROMEO, MD / NIKHIL VERMA, MD / BRIAN J. COLE, MD, MBA

AUTHOR AFFILIATIONS

Department of Orthopedic Surgery (Drs Gilat, Williams, Fu, Garrigues, Romeo, Verma, and Cole; and Messrs Haunschild and Condrón), Rush University Medical Center; and Midwest Orthopaedics at Rush (Drs Garrigues, Romeo, Verma, and Cole), Chicago, Illinois; and Department of Orthopedic Surgery, Shamir Medical Center and Tel Aviv University, Tel Aviv, Israel (Dr Gilat).

CORRESPONDING AUTHOR

Brian J. Cole, MD, MBA; Rush University Medical Center and Midwest Orthopaedics at Rush, 1611 W Harrison St, Suite 300, Chicago, IL 60612 (brian.cole@rushortho.com).

INTRODUCTION

Management of patients who have symptoms of an irreparable rotator cuff tear for whom conservative treatment has failed remains challenging.¹ Physicians have used many procedures to address rotator cuff deficiency, including partial repair,² debridement and subacromial decompression,^{3,4} tuberosplasty,⁵ reversed subacromial decompression,⁶ muscle and tendon transpositions or transfers,⁷⁻¹¹ graft augmentation,^{12,13} subacromial spacer implantation,¹⁴ and reverse total shoulder arthroplasty (RTSA).¹⁵ However, to date, no procedure has provided optimal and reliable outcomes in terms of pain relief and restoration of function.^{1,16}

Arthroscopic superior capsular reconstruction (SCR) is a relatively new procedure for the treatment of irreparable rotator cuff tears. After Mihata et al¹⁶ introduced SCR, many researchers have described surgical techniques for the procedure.¹⁷⁻¹⁹ Most study results have shown encouraging outcomes after SCR in patients with these complex conditions, and surgeons worldwide increasingly are adopting the procedure.^{16,20-26} As with many relatively new procedures, patient selection for SCR has not been defined optimally, and patient factors associated with treatment failure have yet to be studied extensively.

In this study, we aim to identify demographic, clinical, radiographic, and surgical factors associated with failure after SCR. We also will describe the clinical and functional outcomes in this subset of patients.

MATERIALS AND METHODS

Patient Population

After we received approval from our institutional review board, we identified subjects through a database of prospectively collected data in patients who had undergone arthroscopic SCR

with a dermal allograft between 2015 and 2018 at our institution. We included patients who had undergone SCR for an irreparable rotator cuff tear with a minimum 1-year follow-up. We excluded patients with anterior, posterior, or inferior instability; patients without 1-year follow-up; and patients with advanced osteoarthritis (Hamada grades 4b and 5²⁷).

Data Collection

We recorded demographic characteristics and results of the preoperative physical examination. An orthopedic surgery resident (R.G.), who was blinded for review, performed imaging and measurements by means of a picture archiving and communications system (Opal-RAD PACS; Viztek, Garner, North Carolina). We recorded surgical details, including the presence of a subscapularis tear, technique details, and concomitant procedures. Clinical and functional outcomes included postoperative range of motion (ROM), patient-reported outcomes (PROs), and conversion to RTSA. We set a low threshold to define failure, including 1 or more of the following criteria: conversion to RTSA, a decrease in 1-year postoperative shoulder-specific PROs compared with preoperative scores, or patient

reporting at final follow-up that his or her shoulder was in worse condition than before surgery.

Operative Technique

We positioned patients in the beach chair position, draped the shoulder, and prepared in the usual sterile fashion. We then established posterior, anterior, and lateral portals and performed subacromial decompression and debridement of the superior labrum and the rotator cuff footprint. If necessary, we repaired the infraspinatus, subscapularis, or both before performing the SCR. In most cases, we placed 3 knotless anchors medially on the glenoid and 2 anchors just lateral to

the humeral head articular margin at the medial edge of the rotator cuff footprint. We performed measurements and prepared an acellular dermal allograft on the back table (Figure 1). After preparing the graft, we passed it into the joint (Figure 2) and secured it to the anchors by using sutures medially and suture tapes laterally, and then we placed 2 lateral row anchors. We then placed side-to-side sutures to close the interval between the graft and the infraspinatus and subscapularis where possible (Figure 3).

Statistical Analysis

We performed univariate logistic regression analysis (Stata version 13.0;

StataCorp, College Station, Texas) to assess the association between the failure criteria and each of the demographic, imaging, and operative variables. We performed additional analysis for statistically significant continuous variables associated with failure by using receiver operating characteristic (ROC) curve analysis and the Youden index to define the optimal cutoff point. We assessed differences between preoperative and postoperative active ROM, American Shoulder and Elbow Surgeons (ASES), Constant, and 12-Item Short Form Health Survey (SF-12) scores by using the paired student *t* test.



Figure 1. Preparation of the Dermal Allograft on the Back Table.

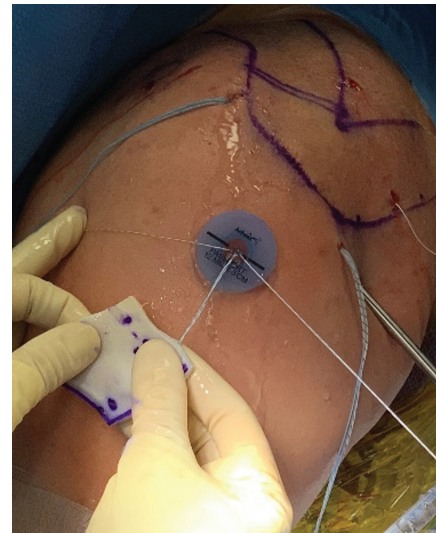


Figure 2. Preparation for Graft Passage Into the Shoulder Joint. Before passing the graft, we cut the cannula with scissors to allow the graft easy passage. We also used a back grasper to facilitate graft passage to the joint and assist in the appropriate positioning of the graft.

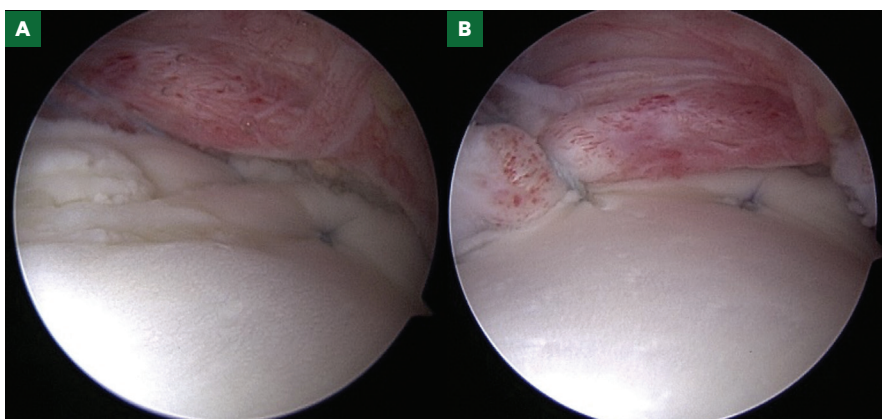


Figure 3. Arthroscopic View. **A,** A completed superior capsular reconstruction with a dermal allograft. **B,** Side-to-side sutures allowing marginal convergence between the remnant rotator cuff tissue and the dermal allograft.

RESULTS

Patient Demographic Characteristics

We included in the study 44 patients (mean [SD] age, 56.7 [5.6] years; range, 46-70 years) who had undergone SCR, with minimum 1-year follow-up. Mean follow-up after surgery was 19 months (range, 12-43 months). There were 13 (29.5%) smokers and 17 (38.6%) patients with a workers' compensation claim. Of the 24 (54.5%) patients who had undergone rotator cuff repair (RCR) that failed, 10 (22.7%) had undergone biceps tenodesis during primary RCR (Table 1).

Imaging Findings, Measurements, and Classifications

The average acromiohumeral distance (AHD) was 5.25 mm. Sixteen (36.4%) patients had signs of acromioclavicular joint arthritis. Radiographic imaging was not available for 1 patient, and of the remaining 43 patients, 8 (18.6%) had signs of some glenohumeral arthritis, with Hamada grade 3 in 7 (16.3%) patients and Hamada grade 4a in 1 (2.3%) patient. Assessment using magnetic resonance imaging (MRI) demonstrated the supraspinatus was torn in all 44 (100%) patients, the infraspinatus was torn in 22 (50%) patients, and the subscapularis was torn in 9 (20.5%) patients (Table 2).

ROM

Mean preoperative active ROM for forward flexion, abduction, and external and internal rotation are detailed in Table 3. There was no statistically significant difference in preoperative vs postoperative ROM, including forward flexion, abduction, and external and internal rotation ($P = .53, .87, .75, \text{ and } .14$, respectively).

Outcomes

Thirty-two (73%) patients had a minimum of 1 year of completed PROs for analysis. Mean ASES scores improved from 47.4 preoperatively

Table 1. Demographic Characteristics

Characteristic	Patient Data (N = 44)
Age, Mean (SD), y	56.7 (5.6)
Sex, No. (%)	
Female	14 (31.8)
Male	30 (68.2)
Affected Side, No. (%)	
Right	23 (52.3)
Left	21 (47.7)
Dominant hand affected	21 (47.7)
BMI, Mean (SD), kg/m²	30.7 (5.5)
Workers' Compensation Claim, No. (%)	17 (38.6)
Prior Health Conditions, No. (%)	
Smoking	13 (29.5)
Hypertension	16 (36.4)
Diabetes	6 (13.6)
Prior Surgical Procedure, No. (%)	
None	20 (45.5)
RCR ^{a,b}	14 (31.8)
RCR+BT ^c	10 (22.7)

Abbreviations: BMI, body mass index; BT, biceps tenodesis; RCR, rotator cuff repair.

^aOne patient had undergone biceps tenotomy, and 1 patient had undergone biceps tenotomy and distal clavicle excision.

^bAt the time of superior capsular reconstruction, 6 (13.6%) patients had an absent biceps tendon, with unknown status of tenodesis, tenotomy, or prior rupture.

^cOne patient had undergone concomitant distal clavicle excision, 1 patient had undergone revision RCR, 1 had undergone 2 revision RCRs, and 1 had undergone manipulation and capsular release.

to 65.5 by 6 months postoperatively ($P < .001$), with further statistically significant improvement seen from 6 to 12 months (65.5-68.3; $P = .01$). Mean Constant and SF-12 Physical Health scores also showed significant improvement between preoperative and 6-month scores (12.6-17.1; $P = .002$, and 32.3-35.4; $P = .04$, respectively). Although mean scores continued to trend toward further improvement at 12 months, the increase was not statistically significant ($P = .24$ and $.11$, respectively) (Table 4).

Factors Associated With Failure

Ten patients (22.7%) met the criteria for clinical failure. Of these, 3 patients had undergone RTSA in the 6 to 12 months

after SCR, 1 of whom experienced complications due to subsequent prosthetic dislocation.

We examined 28 factors for their association with failure. Lower preoperative active forward flexion was associated with failure ($P = .041$). ROC curve analysis revealed an area under the curve of 0.64 (95% CI, 0.396-0.879) (Figure 4). The optimally predictive cutoff point was 110°; patients with less than 110° preoperative forward elevation experienced failure (sensitivity, 60%; specificity, 81.25%; $P = .018$).

Of the 44 patients, 9 had a subscapularis tear. Of the 34 patients who had a successful SCR, 5 patients had a

Table 2. Imaging Findings, Measurements, and Classifications

Characteristic	Patient Data (N = 44)
Mean Acromiohumeral Distance, mm	5.25
Acromioclavicular Joint Arthritis, No. (%)	16 (36.4)
Hamada Classification Grade, No. (%)	(n = 43) ^a
1	27 (62.8)
2	8 (18.6)
3	7 (16.3)
4a	1 (2.3)
Tears, No. (%)	
Supraspinatus	44 (100)
Infraspinatus	22 (50)
Subscapularis	10 (24.4)
Goutallier Classification Grade, No. (%) ^{a,28}	
0	1 (2.4)
1	4 (9.8)
2	12 (29.3)
3	13 (31.7)
4	11 (26.8)
Thomazeau Classification Grade, No. (%) ^{b,29}	
1	14 (34.1)
2	15 (36.6)
3	12 (29.3)

^aRadiographic imaging was not available for 1 patient.

^bWe performed Goutallier classification with MRI and not computed tomography, as first described by Goutallier.²⁸ Three patients did not have imaging uploaded to our servers to allow classification.

Table 3. Preoperative and Postoperative Active ROM

Action	ROM		P Value
	Preoperative	Postoperative	
Forward Flexion, Mean (SD)	138.2° (41.1)	142° (36.3)	.53
Abduction, Mean (SD)	107.5° (45.8)	102.1° (30.8)	.87
External Rotation, Mean (SD)	48.9° (15.1)	50.5° (14.5)	.75
Internal Rotation, Mean (range)	~L2 (T8-S1)	~L1 (T7-S1)	.14

Abbreviation: ROM, range of motion

Table 4. Preoperative and Postoperative Patient-Reported Outcome Scores

Survey Instrument	Preoperative	6 Months	12 Months
ASES	47.4	65.5 ^a	68.3 ^a
Constant	12.6	17.1 ^a	20.0
SF-12 Physical Health	32.3	35.4 ^a	40.3
SF-12 Mental Health	53.3	56.1	52.1

Abbreviations: ASES, American Shoulder and Elbow Surgeons; SF-12, 12-Item Short Form Health Survey.

^aStatistically significant increase when compared with preoperative or 6-month postoperative scores.

subscapularis tear (14.7%), all of which we repaired. Of the 10 patients whose surgery failed, 4 had a subscapularis tear (40%). Of these tears, we repaired 3. We determined that the presence of a subscapularis tear at preoperative MRI or diagnosed during the procedure was associated with failure ($P = .027$). All other variables included in the analysis were not associated with failure in a statistically significant way.

DISCUSSION

The main findings of this study are that limited preoperative forward flexion and the presence of a subscapularis tear are associated with failure after arthroscopic SCR. We also report a significant improvement in PROs in this cohort of patients, supporting earlier outcome studies of arthroscopic SCR.

Two recently published systematic reviews evaluated the efficacy and complication rates of SCR for irreparable rotator cuff tears. Catapano et al²⁰ included 7 published articles and 3 abstracts, reporting on a total of 350 shoulders, with a mean follow-up of 20.6 months. The authors found a significant improvement in PROs in all studies. They also reported a combined radiographic and clinical failure ranging between 3.4% and 36.1%. This study's results also showed a statistically significant improvement in PROs. Although ROM for active forward flexion and external rotation improved after SCR, the difference was not statistically significant. Our clinical failure rate was 22.7% and is well within the range of the studies included in the systematic review by Catapano et al.²⁰

Sochacki et al³⁰ performed a similar systematic review, reporting improvement in PROs and ROM. They reported a 14.2% graft failure at MRI, 3.8% complications, and an 11.7% reoperation rate. However, the results of this systematic review should be appreciated with the understanding that patients included

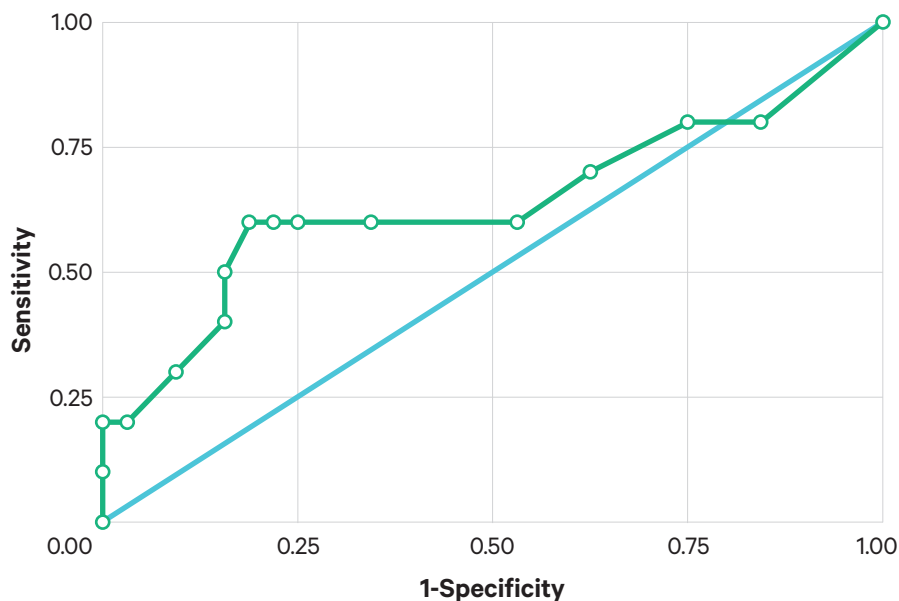


Figure 4. Receiver operating characteristic curve for preoperative active forward elevation association with failure after superior capsular reconstruction.

those undergoing SCR with autologous fascia lata, as well as those receiving an acellular dermal allograft.³¹

Studies in which the authors reported on factors associated with SCR failure are limited. Lee and Min²² studied the effect of an inadequate increase in AHD after SCR and poor posterior remnant tissue on retear rates. They included 32 patients (36 shoulders) who had undergone arthroscopic SCR by using either fascia lata autograft or dermal allograft. They reported 13 (36%) retears diagnosed by means of ultrasonography and MRI and found retears to be associated with small AHD improvement and poor posterior remnant tissue. Denard et al²¹ published preliminary results of a case series of 59 patients undergoing arthroscopic SCR with a dermal allograft. On the basis of postoperative MRI, they found that subscapularis atrophy was lower in the group of patients with healed graft.

In our study, we focused on patient factors associated with clinical outcomes rather than on radiographic outcomes.

We found lower preoperative active forward flexion and the presence of a subscapularis tear to be associated with failure. These results are consistent with those of the study published by Denard et al,²¹ which showed that preoperative subscapularis atrophy was associated with a higher rate of graft tearing with postoperative MRI surveillance.

Lastly, this study provides a statistically significant ($P = .018$) cutoff point of 110° forward flexion, under which patients might be at an increased risk of treatment failure after SCR with a dermal allograft. However, the area under the curve of our ROC analysis was 0.64, which is below the acceptable value of assessing ROC model reliability (0.7).³² Thus, this cutoff should be regarded as suggestive only.

The main limitation of the current study is the relatively small sample size. However, the number of patients in this study is comparable with that of most studies published on this relatively new surgical procedure. Another limitation is the lack of 1-year PROs for several

study patients. However, all patients in the study group had a minimum 1-year follow-up with their physician, reporting on the status of their shoulder. Also, our PRO compliance rate is still relatively high (73%), and that is without including 3 patients who had undergone arthroplasty and were not relevant for 1-year PROs. Although a minimum 1-year follow-up is considered short term, we believe most failures that are not related to progression of arthropathy occur during this period, similar to failures after RCR.

CONCLUSIONS

SCR is a successful procedure in most cases, demonstrating high satisfaction rates and a steady increase in PROs. Limited preoperative forward flexion and the presence of a subscapularis tear are associated with increased risk of failure after SCR. We need further high-quality studies to substantiate these preliminary findings. ❖

References and financial disclosures are available online at www.rush.edu/orthopedicsjournal.