

# The American Journal of Sports Medicine

<http://ajs.sagepub.com/>

---

## Arthroscopic Repair of Full-Thickness Rotator Cuff Tears With and Without Acromioplasty: Randomized Prospective Trial With 2-Year Follow-up

Geoffrey D. Abrams, Anil K. Gupta, Kristen E. Hussey, Elizabeth S. Tetteh, Vasili Karas, Bernard R. Bach, Jr, Brian J. Cole, Anthony A. Romeo and Nikhil N. Verma

*Am J Sports Med* published online April 14, 2014

DOI: 10.1177/0363546514529091

The online version of this article can be found at:

<http://ajs.sagepub.com/content/early/2014/04/14/0363546514529091>

---

Published by:



<http://www.sagepublications.com>

On behalf of:

American Orthopaedic Society for Sports Medicine



Additional services and information for *The American Journal of Sports Medicine* can be found at:

Published online April 14, 2014 in advance of the print journal.

**P<P**

**Email Alerts:** <http://ajs.sagepub.com/cgi/alerts>

**Subscriptions:** <http://ajs.sagepub.com/subscriptions>

**Reprints:** <http://www.sagepub.com/journalsReprints.nav>

**Permissions:** <http://www.sagepub.com/journalsPermissions.nav>

>> [OnlineFirst Version of Record](#) - Apr 14, 2014

[What is This?](#)

# Arthroscopic Repair of Full-Thickness Rotator Cuff Tears With and Without Acromioplasty

## Randomized Prospective Trial With 2-Year Follow-up

Geoffrey D. Abrams,<sup>\*†‡</sup> MD, Anil K. Gupta,<sup>§</sup> MD, MBA, Kristen E. Hussey,<sup>||</sup> BS, Elizabeth S. Tetteh,<sup>||</sup> MD, Vasili Karas,<sup>¶</sup> MD, Bernard R. Bach Jr,<sup>||</sup> MD, Brian J. Cole,<sup>||</sup> MD, MBA, Anthony A. Romeo,<sup>||</sup> MD, and Nikhil N. Verma,<sup>||</sup> MD  
*Investigation performed at Rush University Medical Center, Chicago, Illinois, USA*

**Background:** Acromioplasty is commonly performed during arthroscopic rotator cuff repair, but its effect on short-term outcomes is debated.

**Purpose:** To report the short-term clinical outcomes of patients undergoing arthroscopic repair of full-thickness rotator cuff tears with and without acromioplasty.

**Study Design:** Randomized controlled trial; Level of evidence, 2.

**Methods:** Patients undergoing arthroscopic repair of full-thickness rotator cuff tears were randomized into acromioplasty or non-acromioplasty groups. The Simple Shoulder Test (SST), American Shoulder and Elbow Surgeons (ASES) score, Constant score, University of California–Los Angeles (UCLA) score, and Short Form–12 (SF-12) health assessment were collected along with physical examination including range of motion and dynamometer strength testing. Intraoperative data including tear size, repair configuration, and concomitant procedures were recorded. Follow-up examination was performed at regular intervals up to 2 years. Preoperative imaging was reviewed to classify the acromial morphologic type, acromial angle, and lateral acromial angulation.

**Results:** A total of 114 patients were initially enrolled in the study, and 95 (83%; 43 nonacromioplasty, 52 acromioplasty) were available for a minimum 2-year follow-up. There were no significant differences in baseline characteristics, including number of tendons torn, repair configuration, concomitant procedures, and acromion type and angles. Within groups, there was a significant ( $P < .001$ ) improvement in all functional outcome scores from preoperatively to all follow-up time points, including 2 years, for the nonacromioplasty and acromioplasty groups (ASES score: 55.1-91.5, 48.8-89.0; Constant score: 48.3-75.0, 51.9-78.7, respectively). There were no significant differences in functional outcomes between nonacromioplasty and acromioplasty groups or between subjects with different acromial features at any time point.

**Conclusion:** The results of this study demonstrate no difference in clinical outcomes after rotator cuff repair with or without acromioplasty at 2 years postoperatively.

**Keywords:** rotator cuff; acromioplasty; shoulder; acromion; repair

Building upon previous work by Codman and Akerson,<sup>2</sup> researchers have implicated the anterior acromion in the pathogenesis of what Neer<sup>14</sup> initially described as chronic impingement syndrome. It was hypothesized that excrescences on the acromion caused mechanical impingement on the rotator cuff, resulting in rotator cuff injury and attrition. Neer<sup>14</sup> discussed the role of performing acromioplasty, with and without rotator cuff repair, to smooth the area of contact over the supraspinatus tendon and

decrease mechanical wear. Open acromioplasty developed into a viable treatment option for impingement syndrome as a primary treatment or as an adjunct to subacromial decompression.<sup>19</sup> As modern arthroscopic techniques evolved, Ellman<sup>4</sup> developed a technique for an arthroscopic anterior acromioplasty. Advantages of the arthroscopic approach are that it allows a more thorough evaluation of the glenohumeral joint, treatment of intra-articular injuries, improved cosmesis, preservation of the deltoid origin, and quicker postoperative rehabilitation.<sup>3</sup> Because of these factors, arthroscopic acromioplasty is being performed with increasing frequency.<sup>21</sup> A recent randomized controlled trial, however, suggested that arthroscopic acromioplasty showed no significant benefit compared with

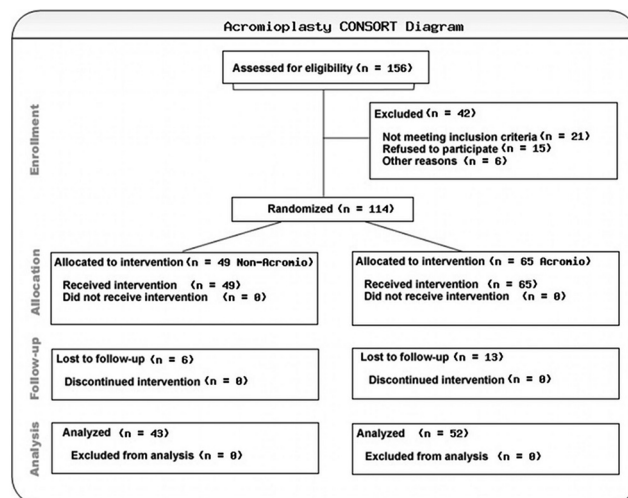
a supervised and structured exercise program for the treatment of subacromial impingement.<sup>8</sup>

Acromioplasty is commonly performed concomitantly with rotator cuff repair if the acromion is believed to be a source of mechanical wear on the rotator cuff. There have been no high-level investigations, however, that demonstrate an improved clinical outcome with acromioplasty at the time of rotator cuff repair.<sup>10</sup> Despite this, the incidence of acromioplasty at the time of rotator cuff repair has significantly increased recently.<sup>22</sup> The purpose of this study was to evaluate short-term functional outcomes of patients undergoing arthroscopic rotator cuff repair with and without acromioplasty. The null hypothesis was that no difference in clinical outcomes would be found after arthroscopic repair of full-thickness rotator cuff tears in patients with or without concomitant acromioplasty.

## MATERIALS AND METHODS

This prospective randomized clinical trial offered enrollment to patients meeting inclusion criteria of a primary arthroscopic repair of a full-thickness tear of the superior rotator cuff who were at least 18 years of age. Exclusion criteria included isolated subscapularis tear, partial tears, irreparable tears or partial repair (those which could not be completely repaired to the footprint even after appropriate releases), and revision surgery. Enrollment occurred from October 2007 to January 2011, and consent was gained from each patient agreeing to participate, under the institutional review board–approved protocol.

Patients were randomized to acromioplasty or nonacromioplasty groups via a sealed envelope (Figure 1). Assignments were not disclosed to the patient. Before surgery, age, sex, marital status, occupation, worker compensation status, hand dominance, alcohol consumption, cigarette use, diabetes, and family history of rotator cuff lesions were recorded. If patients recounted a discrete traumatic episode within 6 weeks (such as a fall) that precipitated their shoulder pain, they were classified as having an acute rotator cuff tear. All others were classified as having degenerative tears. Preoperative American Shoulder and Elbow Surgeons (ASES),<sup>12</sup> Simple Shoulder Test (SST), University of California–Los Angeles (UCLA), visual analog scale (VAS) for pain, and Constant scores were calculated. In addition, patients completed a physical examination,



**Figure 1.** CONSORT diagram indicating number of patients screened, enrolled, randomized, and lost to follow-up.

performed by a sports medicine research fellow, including bilateral shoulder range of motion (forward flexion, external rotation at the side, and external and internal rotation at 90° of abduction) and strength testing in both forward elevation in the scapular plane and external rotation at the side via an Isobex static dynamometer (Medical Device Solutions AG, Burgdorf, Switzerland) and/or J-Tech Commander PowerTrack II dynamometer (Salt Lake City, Utah, USA). The maximum strength recorded over 3 trials was included for both the operative and nonoperative shoulder.

Preoperative shoulder radiographs for enrolled patients were reviewed by 2 independent observers to assess 4 parameters of acromial structure: anterior slope of the acromion in the sagittal plane (Figure 2), lateral acromial angulation in the coronal plane (Figure 3), and the presence or absence of medial encroachment. The angle of the anterior slope of the acromion was categorized as type I (0°–15°), type II (16°–30°), or type III (>30°), as first described by Bigliani et al.<sup>1</sup> In the sagittal plane, a line through the middle of the acromion was drawn from the posterior to anterior. Another line was then drawn through the angulation in the acromion anteriorly. The angle created by these 2 lines was considered to be the anterior slope of the acromion.<sup>11</sup> Lateral acromial angulation in

\*Address correspondence to Geoffrey D. Abrams, MD, 3801 Miranda Avenue, Mail Code 112, Palo Alto, CA 94304, USA (e-mail: gabrams@gmail.com).

<sup>†</sup>Department of Orthopedic Surgery, Stanford University, Stanford, CA, USA.

<sup>‡</sup>Veterans Administration Palo Alto, Palo Alto, CA, USA.

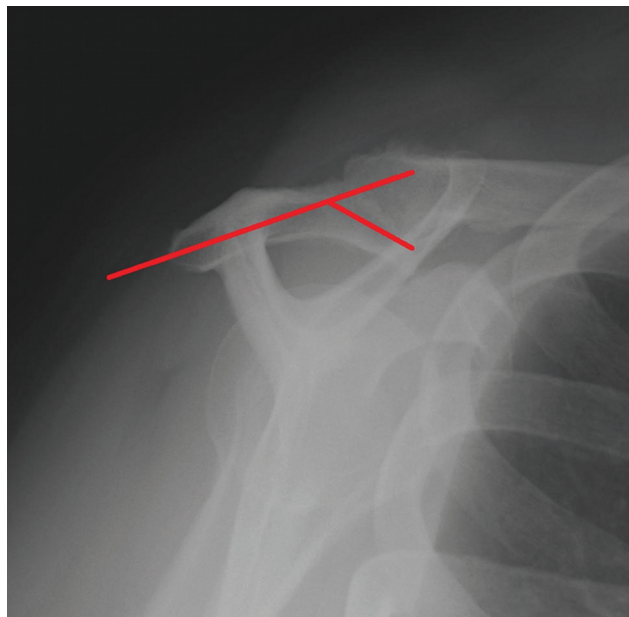
<sup>§</sup>Florida Orthopedic Institute, Tampa, FL, USA.

<sup>||</sup>Department of Orthopedic Surgery, Rush University Medical Center, Chicago, IL, USA.

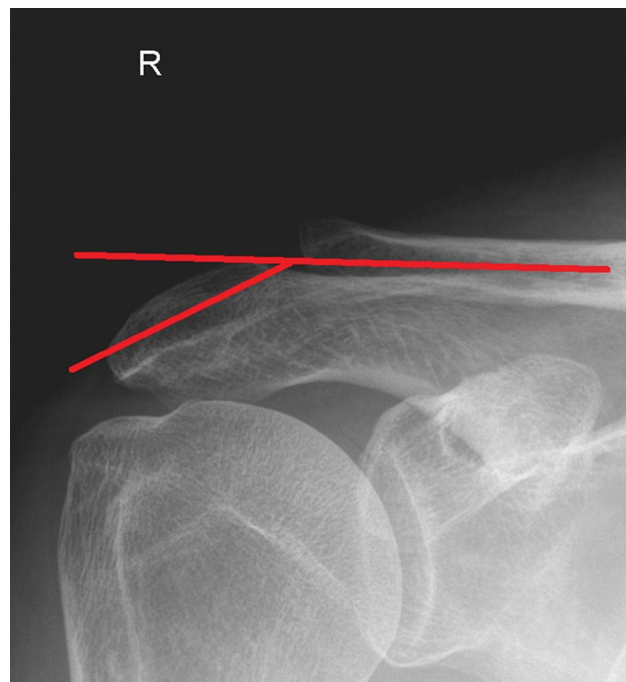
<sup>¶</sup>Department of Orthopedic Surgery, Duke University, Durham, NC, USA.

Presented as a poster at the 39th annual meeting of the AOSSM, Chicago, Illinois, USA, July 2013.

One or more of the authors has declared the following potential conflict of interest or source of funding: B.R.B.: research support: Arthrex, ConMed Linvatec, DJ Orthopaedics, Ossur, Smith & Nephew, and Tornier; publisher compensation: Slack Inc; board member: AAOSM, *Orthopedics Today*. N.N.V.: royalties: Smith & Nephew; paid speaker: Arthroscopy; consultant: Smith & Nephew, Arthrex; stock/options: Omeros; research support: Arthrex, Smith & Nephew, Athletico, ConMed Linvatec, Miomed, Mitek, Arthroscopy; royalties/publisher support: Vindico Medical, *Orthopedics Hyperguide*, *Arthroscopy*; board member: *Journal of Knee Surgery*, *Arthroscopy*, Slack Inc, Arthroscopy Association Learning Center Committee. B.J.C.: board member: AANA; consultant: Genzyme, Arthrex, Zimmer, Carticept, Regentis, DJO, Johnson & Johnson; research support: MLB, OREF, NIH/MIMAS, Arthrex, Zimmer, Arthroscopy, Medipost, Johnson & Johnson; royalties: Arthrex, DJO. A.A.R.: royalties: Arthrex; paid speaker: Arthrex, DJ Orthopaedics; consultant: Arthrex; research support: Arthrex, Ossur, Smith & Nephew; nonincome support: Arthrex, DJ Orthopaedics; board member: AOSSM, ASES, AANA.



**Figure 2.** Scapular-Y radiograph of a right shoulder demonstrating the method for measurement of the anterior slope of the acromion.



**Figure 3.** Anterior-posterior radiograph of a right shoulder demonstrating the method for measurement of the lateral acromial angulation.

the coronal plane was classified in relation to the distal end of the clavicle (Figure 3). A line was drawn through the midportion of the acromioclavicular joint while a second line was drawn through the middle of the acromion. The angle subtended by these 2 lines was recorded as the lateral acromion angulation and dichotomized into type A ( $0^{\circ}$ - $10^{\circ}$ ) and type B (down-sloping  $>10^{\circ}$ ).<sup>11</sup>

Patients with an initial clinical and radiographic diagnosis of a rotator cuff tear were verified in the operating room to have a full-thickness tear of the rotator cuff via arthroscopy. The tendon(s) involved, size of the tear as measured with a standard probe or shaver/bur of a known size, tear pattern, degree of retraction, tendon quality, and concomitant procedures were assessed intraoperatively and recorded. Rotator cuff repair was then performed by 1 of the 4 senior authors (B.R.B., B.J.C., A.A.R., N.N.V.) using their preferred technique. All surgeons were fellowship-trained sports medicine or upper extremity surgeons practicing at a high-volume orthopaedic surgery practice. Preferred suture passing techniques typically included use of a curved shuttling device through the posterior portal while viewing from lateral. Details including type and number of anchors used as well as repair configuration were recorded.

Those in the acromioplasty group underwent release of the coracoacromial ligament and flattening of the anterior-inferior surface of the acromion. This was performed with a combination of shaver and electrocautery use to remove bursal tissue and define the lateral border and undersurface of the acromion. A motorized bur was then used to remove bone until the undersurface of the acromion was flat when viewed from the lateral portal using a posterior cutting block technique. Rotator cuff repair was performed in standard fashion by use of a combination of suture

passing devices and repair configurations as described in the Results section. Extensive releases were not performed with the exception of rotator interval releases to assist with reduction of retracted tears.

All patients were discharged on the day of the surgery. Physical therapy was standardized for both groups; it was instituted approximately 1 to 2 weeks after surgery, after the first postoperative visit, and focused on passive motion only. Sling immobilization when patients were not performing physical therapy or a home exercise program was continued for 6 weeks after surgery. Active range of motion was begun at 6 weeks, and strengthening was deferred until 12 weeks postoperatively. Patients returned for follow-up visits, completed an identical questionnaire, and repeated the physical examination at increments of 6 months, 1 year, and 2 years postoperatively. Any additional surgery on the operative shoulder after the index procedure was noted. Patients unable to return for follow-up visits completed surveys via phone call or home mailing, but physical examinations could not be completed for these patients.

Continuous variables were compared using independent samples *t* test, and dichotomous variables were compared using either a chi-square or Fisher exact test. Results are reported as mean  $\pm$  standard deviation. When *t* tests were performed, the Levene test was used to determine whether equality of variance among the particular groups and time points could be assumed. A kappa statistic was calculated for acromial type, whereas an intraclass correlation coefficient was calculated for anterior and lateral acromial angle. An alpha value of .05 with a Bonferroni correction for multiple comparisons was set as significant.



TABLE 1  
Patient Demographics and Intraoperative Information Within the Nonacromioplasty and Acromioplasty Cohorts<sup>a</sup>

|                                 | Nonacromioplasty Group (n = 43) | Acromioplasty Group (n = 52) | P   |
|---------------------------------|---------------------------------|------------------------------|-----|
| Age, y                          | 58.0 ± 8.0                      | 59.6 ± 8.2                   | .32 |
| Male sex                        | 27 (62.8)                       | 37 (71.2)                    | .39 |
| Physical examination at 2 years | 9 (20.9)                        | 8 (15.4)                     | .48 |
| Smoker                          | 4 (9.3)                         | 2 (3.8)                      | .28 |
| Diabetic                        | 3 (7.0)                         | 5 (9.6)                      | .65 |
| Workers compensation            | 7 (16.3)                        | 8 (15.4)                     | .91 |
| Acute tear                      | 24 (56)                         | 27 (52)                      | .95 |
| Degenerative tear               | 19 (44)                         | 25 (48)                      | .89 |
| Involved tendons                | 1.3 ± 0.5                       | 1.4 ± 0.6                    | .47 |
| Tear size, mm                   | 25.8 ± 8.5                      | 25.8 ± 10.8                  | .98 |
| Retraction, mm                  | 12.5 ± 10.4                     | 12.3 ± 11.9                  | .93 |
| Anchors used                    | 3.2 ± 1.5                       | 2.9 ± 1.2                    | .26 |
| Double row                      | 24 (68.6)                       | 26 (56.5)                    | .27 |
| Single row                      | 11 (31.4)                       | 17 (37.0)                    | .60 |
| Side to side                    | 0 (0)                           | 3 (6.5)                      | —   |
| Biceps tenodesis/tenotomy       | 17 (39.5)                       | 23 (43.4)                    | .64 |
| Distal clavicle excision        | 2 (4.7)                         | 3 (5.7)                      | .81 |

<sup>a</sup>Values are expressed as mean ± standard deviation or No. (%).

A post hoc power analysis was conducted before enrollment closure based on previously published data by MacDonald et al.<sup>10</sup> Those investigators reported ASES scores at 2-year follow-up between patients undergoing rotator cuff repair with and without acromioplasty and found a 95% confidence interval of -13.0 to 3.2 for the score difference. Using the reported standard deviation from these 2 study groups,<sup>10</sup> a minimal clinically important difference (MCID) of 10 points in the ASES score,<sup>16,20</sup> and group size of 45 patients each, we would be powered at 81.1% to detect a difference.<sup>9</sup> We therefore set a goal of 50 patients in each of the groups for the current investigation to account for attrition.

## RESULTS

A total of 114 patients were initially enrolled in the study, and 95 (83%) were available for a minimum 2-year follow-up. Six patients were not available for 2-year follow-up in the nonacromioplasty group and 13 in the acromioplasty group after repeated phone and mailing attempts. Cohort and surgical characteristics are presented in Table 1.

A majority of patients in both cohorts had a type II acromion, but there was no significant difference in the proportion of patients with a type I, II, or III acromion. In addition, acromial angle (used to determine acromion type) as well as lateral acromial angle showed no overall differences between the 2 groups (Table 2). Interobserver agreement for acromion type, acromial angle, and lateral acromial angle is presented in Table 2.

Within the nonacromioplasty group, there was significant improvement in all functional scores at all follow-up time points (6 months, 1 year, 2 years) compared with preoperatively (Figure 4). There were no differences in any functional scores between 1- and 2-year time points (Figure 4). For the acromioplasty group, a similar trend was

seen. There were significant improvements in all functional measures from preoperatively to the 6-month, 1-year, and 2-year time points, while scores between 1 and 2 years did not significantly improve (Figure 4). Between the nonacromioplasty and acromioplasty groups, there were no differences in any functional score or range of motion measurement at any time point during the follow-up period (Figure 4; see also the Appendix, available online at <http://ajsm.sagepub.com/supplemental>).

When functional scores and range of motion based on acromial type were examined, there were no significant differences at any time point either within group or between groups (Table 3). As an example, there was no significant difference in outcomes within the acromioplasty group for type I versus type III patients at 2 years postoperatively nor was there a significant difference in outcomes between type III acromion patients in the nonacromioplasty and acromioplasty groups. These nonsignificant findings were also seen when functional outcomes and range of motion measurements of lateral acromial angles types A (<10°) and B (>10°) were compared between the nonacromioplasty and acromioplasty cohorts.

During the follow-up period, 4 additional procedures were performed in the nonacromioplasty group and 1 in the acromioplasty group ( $P = .11$ ) (Table 4). This included 3 revision rotator cuff repairs in the nonacromioplasty group and 1 revision repair in patients undergoing acromioplasty.

## DISCUSSION

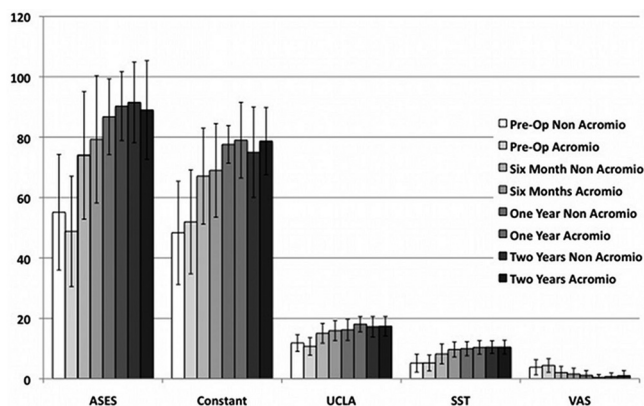
The objective of this investigation was to determine the effect of acromioplasty on short-term functional outcomes after arthroscopic repair of full-thickness rotator cuff tears. Using a randomized, prospective, and blinded study design, we found that patients undergoing rotator cuff

TABLE 2  
Radiographic Parameters Among the Nonacromioplasty and Acromioplasty Groups<sup>a</sup>

|                             | Nonacromioplasty Group | Acromioplasty Group | P   | Kappa | ICC   |
|-----------------------------|------------------------|---------------------|-----|-------|-------|
| Acromion type <sup>b</sup>  |                        |                     |     | 0.694 |       |
| I                           | 6 (15.4)               | 4 (8.3)             | .31 |       |       |
| II                          | 24 (61.5)              | 33 (68.6)           | .48 |       |       |
| III                         | 8 (20.5)               | 11 (22.9)           | .79 |       |       |
| Acromial angle, deg         | 23.0 ± 9.8             | 23.4 ± 9.7          | .87 |       | 0.936 |
| Lateral acromial angle, deg | 10.1 ± 6.6             | 9.0 ± 7.8           | .46 |       | 0.954 |

<sup>a</sup>Values are expressed as mean ± standard deviation or No. (%). ICC, interobserver correlation coefficient.

<sup>b</sup>According to Bigliani et al.<sup>1</sup>



**Figure 4.** Preoperative functional scores versus those at 6-month, 1-year, and minimum 2-year follow-up for the non-acromioplasty (Non Acromio) and acromioplasty (Acromio) groups. There were no significant differences between groups at any time point during the study period. ASES, American Shoulder and Elbow Surgeons score; Constant, Constant score; SST, Simple Shoulder Test score; UCLA, University of California–Los Angeles score; VAS, visual analog scale score.

repair either with or without acromioplasty had similar postoperative functional scores at a minimum of 2 years after surgery. We also did not find a significant effect of acromial type on functional outcomes in either group.

Whether rotator cuff tears arise from intrinsic degeneration<sup>7,15</sup> of the tendon or external mechanical abrasion<sup>14</sup> remains controversial. Despite the controversy, acromioplasty has become a commonly performed procedure.<sup>21</sup> Standard performance of the procedure, however, has some theoretical disadvantages that include weakening of the deltoid origin<sup>17</sup> and acromioclavicular joint, anterosuperior instability of the humerus, and the formation of adhesions between the undersurface of the acromion and the rotator cuff tendon that may limit range of motion.<sup>6</sup> Acromioplasty also increases operative time, leading to increased soft tissue swelling in the arthroscopic setting due to fluid egress. Potential advantages of acromioplasty include decreasing contact between the rotator cuff and

acromion and formation of bleeding bone, which may biologically augment healing.

Prior investigations have reported the effect of acromioplasty on postoperative outcomes after rotator cuff repair. Most recently, Shin et al<sup>18</sup> reported on functional outcomes of patients without acromial osteophytes or spurs undergoing arthroscopic repair of full-thickness rotator cuff tears with and without acromioplasty. The investigators did not find any differences in pain, range of motion, functional outcome scores, or retear rates between the 2 groups. Similarly, in a multicenter, randomized, clinical trial, no differences in functional outcomes scores were found between the nonacromioplasty and acromioplasty groups at any time point up to 2 years postoperatively.<sup>10</sup> Potential interactions between acromion type and functional outcome were also investigated, and no significant associations were found. The investigators did, however, report a significantly higher rate in the number of patients requiring additional surgery for the nonacromioplasty group. Although we did not find a statistically significant difference in the reoperation rate between the groups, there were more patients in the nonacromioplasty group who required revision rotator cuff repair. The number of patients in the current study undergoing revision surgery is insufficient to draw any conclusions, and further study with long-term follow-up and postoperative imaging is required. Other investigations reporting outcomes after rotator cuff repair with and without acromioplasty have also reported no significant differences in functional scores between the 2 groups.<sup>5,13</sup>

This investigation did not find an association between outcome scores and acromial morphologic type either within or between groups. While it is possible that acromial type truly has no effect on functional scores, we were underpowered with respect to this subgroup analysis. In addition, our current functional outcome metrics may not be sensitive enough to detect subtle differences between these groups. This is consistent with data reported by MacDonald et al,<sup>10</sup> who did not find any association between functional outcome score and acromion type. Henkus et al,<sup>7</sup> however, examined the effect of acromial morphologic type in patients undergoing bursectomy alone versus bursectomy and decompression after failing nonoperative treatment for primary impingement without

TABLE 3  
Functional Scores and Range of Motion for the Nonacromioplasty and Acromioplasty Groups Sorted by Acromion Type<sup>a</sup>

|          | Nonacromioplasty |             |             |             | Acromioplasty |             |             |             |
|----------|------------------|-------------|-------------|-------------|---------------|-------------|-------------|-------------|
|          | Preoperative     | 6 Months    | 1 Year      | 2 Years     | Preoperative  | 6 Months    | 1 Year      | 2 Years     |
| ASES     |                  |             |             |             |               |             |             |             |
| All      | 55.1 ± 19.1      | 74.0 ± 21.1 | 86.8 ± 12.6 | 91.5 ± 13.3 | 48.8 ± 18.2   | 79.3 ± 21.0 | 90.3 ± 11.4 | 89.0 ± 16.4 |
| Type I   | 46.4 ± 20.0      | 72.5 ± 23.8 | 95.5 ± 7.7  | 83.1 ± 21.7 | 52.9 ± 19.3   | 83.9 ± 19.5 | —           | 84.2 ± 25.4 |
| Type II  | 54.2 ± 19.4      | 70.4 ± 21.5 | 82.4 ± 12.2 | 89.5 ± 12.6 | 48.4 ± 20.8   | 82.6 ± 20.0 | 90.1 ± 11.0 | 87.3 ± 17.0 |
| Type III | 59.5 ± 13.5      | 74.7 ± 24.9 | 84.2 ± 22.4 | 98.1 ± 5.3  | 50.6 ± 14.0   | 73.1 ± 23.7 | 88.8 ± 16.5 | 95.5 ± 9.5  |
| SST      |                  |             |             |             |               |             |             |             |
| All      | 5.1 ± 3.0        | 8.2 ± 3.3   | 9.9 ± 2.3   | 10.5 ± 2.1  | 5.2 ± 2.6     | 9.7 ± 2.5   | 10.4 ± 2.2  | 10.5 ± 2.3  |
| Type I   | 4.2 ± 2.5        | 7.6 ± 4.2   | 11.3 ± 1.2  | 9.8 ± 2.6   | 4.3 ± 3.3     | 11.0 ± 1.0  | —           | 10.3 ± 3.5  |
| Type II  | 5.0 ± 3.0        | 7.6 ± 3.0   | 9.4 ± 2.4   | 10.0 ± 2.3  | 5.3 ± 2.6     | 9.6 ± 2.9   | 10.1 ± 2.5  | 10.2 ± 2.4  |
| Type III | 6.2 ± 3.8        | 8.6 ± 4.2   | 9.0 ± 4.2   | 11.4 ± 0.9  | 6.2 ± 2.9     | 9.7 ± 1.6   | 11.0 ± 1.2  | 10.7 ± 1.6  |
| UCLA     |                  |             |             |             |               |             |             |             |
| All      | 11.8 ± 2.8       | 15.0 ± 3.3  | 16.2 ± 3.5  | 17.2 ± 3.4  | 10.7 ± 2.9    | 15.9 ± 3.3  | 18.1 ± 2.5  | 17.4 ± 3.3  |
| Type I   | 12.7 ± 3.0       | 15.5 ± 3.0  | 18.7 ± 2.3  | 16.3 ± 4.5  | 9.3 ± 3.1     | 16.0 ± 3.5  | —           | 17.3 ± 3.4  |
| Type II  | 11.2 ± 2.8       | 14.5 ± 3.3  | 15.3 ± 3.7  | 16.5 ± 3.6  | 10.5 ± 2.8    | 16.5 ± 3.4  | 18.1 ± 2.4  | 17.0 ± 3.5  |
| Type III | 12.0 ± 2.8       | 13.2 ± 7.7  | 18.0 ± 2.8  | 19.5 ± 1.4  | 11.7 ± 3.6    | 14.6 ± 3.2  | 17.0 ± 3.8  | 18.2 ± 2.8  |
| VAS      |                  |             |             |             |               |             |             |             |
| All      | 3.8 ± 2.5        | 2.0 ± 2.0   | 1.2 ± 1.6   | 0.7 ± 1.2   | 4.4 ± 2.3     | 1.6 ± 1.9   | 0.5 ± 0.9   | 1.0 ± 1.7   |
| Type I   | 4.5 ± 2.6        | 1.8 ± 2.1   | 0.7 ± 1.2   | 1.5 ± 2.1   | 6.0 ± 2.4     | 1.7 ± 2.9   | —           | 1.0 ± 1.2   |
| Type II  | 3.7 ± 2.3        | 2.7 ± 2.0   | 1.5 ± 1.6   | 0.7 ± 1.1   | 4.2 ± 2.4     | 1.1 ± 1.6   | 0.5 ± 1.0   | 1.2 ± 1.9   |
| Type III | 5.0 ± 2.8        | 2.7 ± 2.7   | 2.0 ± 2.8   | 0.3 ± 0.5   | 4.2 ± 2.1     | 2.4 ± 2.3   | 0.5 ± 1.0   | 0.4 ± 0.9   |
| Constant |                  |             |             |             |               |             |             |             |
| All      | 48.3 ± 17.1      | 67.1 ± 15.9 | 77.8 ± 6.2  | 75.0 ± 15.0 | 51.9 ± 17.2   | 69.0 ± 15.5 | 79.0 ± 12.5 | 78.7 ± 11.1 |
| Type I   | 49.0 ± 15.5      | 54.0 ± 8.5  | 77.3 ± 9.4  | 81.8 ± 18.7 | 47.2 ± 7.4    | 76.0 ± 10.8 | —           | —           |
| Type II  | 50.0 ± 16.6      | 67.1 ± 14.6 | 75.2 ± 5.8  | 68.6 ± 16.6 | 50.9 ± 17.6   | 68.1 ± 18.7 | 79.2 ± 14.3 | 76.2 ± 12.0 |
| Type III | 45.9 ± 22.5      | 73.8 ± 23.4 | 84.5 ± n/a  | 64.7 ± n/a  | 64.0 ± 9.8    | 68.5 ± 6.5  | 78.1 ± 7.5  | 86.0 ± 3.4  |

<sup>a</sup>Values are expressed as mean ± standard deviation. Acromion type according to Bigliani et al.<sup>1</sup> —, no data available for that patient subset at that time point; ASES, American Shoulder and Elbow Surgeons score; Constant, Constant score; n/a, standard deviation could not be calculated; SST, Simple Shoulder Test score; UCLA, University of California–Los Angeles score; VAS, visual analog scale for pain score.

TABLE 4  
Revision Procedures After Index Rotator Cuff Repair by Cohort<sup>a</sup>

|                              | Nonacromioplasty Group            | Acromioplasty Group | Acromion Type <sup>b</sup> |
|------------------------------|-----------------------------------|---------------------|----------------------------|
| Revision procedures, No. (%) | 4 (9.3)                           | 1 (1.9)             |                            |
| Patient A                    | Revision RTC repair               | —                   | II                         |
| Patient B                    | Capsular release, biceps tenotomy | —                   | II                         |
| Patient C                    | Revision RTC repair               | —                   | II                         |
| Patient D                    | Revision RTC repair               | —                   | II                         |
| Patient E                    | —                                 | Revision RTC repair | II                         |

<sup>a</sup>RTC, rotator cuff. — indicates that that particular patient was not included in the group because they had the alternative surgical procedure.

<sup>b</sup>According to Bigliani et al.<sup>1</sup>

rotator cuff tear. Using a prospective and randomized study design, the investigators reported that a type III acromion had a negative effect on the Constant score, SST, and VAS for pain compared with a type I acromion. It should be noted, however, that our subgroup analysis for those with acromion types I and III was small and therefore likely underpowered to detect a clinically significant difference if present.

There are a number of limitations to this study. The number of patients in the acromioplasty group exceeded

the number of patients in the nonacromioplasty group due to unintentional randomization bias that was generated. An increased number of patients who were enrolled in the nonacromioplasty group were examined intraoperatively and excluded for a lack of full-thickness rotator cuff tear. The randomization assignment given to the excluded patients was initially not restored into the randomization pool, leading to a significantly increased number within the acromioplasty group. This error was recognized and randomization assignments given to excluded patients

were repopulated into the randomization pool and enrollment was continued, minimizing the final disparity. During the entire process no patients were converted from one group to another, and the primary randomization assignment was always kept. Other limitations included the lack of postoperative physical examinations in all patients because some surveys were completed by mail or phone interview. Because of this, postoperative Constant and UCLA scores as well as individual strength and range of motion data could not be collected for all patients (Table 1). One-year follow-up, however, included 46% of available UCLA scores and 32% of available Constant scores, so comparisons made at this time point may be more valid. In addition, the inclusion of more than 1 surgeon, who used individualized techniques for rotator cuff repair, may have added an additional confounding factor to the results. We did not obtain postoperative imaging and therefore could not assess the appropriateness of the decompression or the effect that acromioplasty may have had on asymptomatic retear rates. It is possible that some decompressions were not performed adequately. If this were the case, preoperative acromion type for those in the acromioplasty group would have little effect on functional outcome scores and instead the scores would reflect a metric (postoperative acromion type) that we did not capture. Finally, the number of patients with type I or III acromion was limited and therefore analyses within and between these subgroups were underpowered.

Although this investigation was not able to detect a difference between the 2 groups, this does not mean that concomitant acromioplasty at the time of rotator cuff repair has no merit. In some circumstances, primary impingement causing rotator cuff injury may be a true phenomenon. This may occur in severe type III acromion or when a large lateral or anterior spur has developed. Acromioplasty may also have a role in non-type III acromions. One study found increased reoperation rates for those not receiving acromioplasty at the time of rotator cuff repair.<sup>10</sup> We also found an increased number of patients undergoing revision rotator cuff repair in the nonacromioplasty group, although this finding was nonsignificant. Interestingly, none of these patients had type III acromions. It is possible that the studies to date have not enrolled enough patients to be able to consistently detect clinical differences within these subgroups. Further, the effect of acromioplasty on rotator cuff healing has not been determined. As discussed above, it is also possible that acromial bleeding may provide an improved biological environment for tendon healing after acromioplasty, similar to improved meniscal healing after concomitant ACL reconstruction. Recent data from Shin et al,<sup>18</sup> however, indicate that there is no significant difference in retear rates between those undergoing acromioplasty and those not undergoing acromioplasty at the time of rotator cuff repair. Finally, long-term follow-up is needed to determine whether differences exist in long-term functional outcome or retear rates between groups.

In conclusion, this investigation did not demonstrate a difference in clinical outcomes after arthroscopic repair of full-thickness rotator cuff tears with or without

concomitant acromioplasty at short-term follow-up. However, specific analysis of type III acromion, follow-up with postoperative imaging, and long-term follow-up are needed to determine whether functional or structural differences exist in patients undergoing arthroscopic rotator cuff repair with or without acromioplasty.

## ACKNOWLEDGMENT

The authors thank Jason Shin, MD, for his assistance with data acquisition.

## REFERENCES

1. Bigliani LU, Morrison DS, April EW. The morphology of the acromion and its relationship to rotator cuff tears. *Orthop Trans.* 1986;10:216.
2. Codman EA, Akerson IB. The pathology associated with rupture of the supraspinatus tendon. *Ann Surg.* 1931;93(1):348-359.
3. Davis AD, Kakar S, Moros C, Kaye EK, Schepsis AA, Voloshin I. Arthroscopic versus open acromioplasty: a meta-analysis. *Am J Sports Med.* 2010;38(3):613-618.
4. Ellman H. Arthroscopic subacromial decompression: analysis of one- to three-year results. *Arthroscopy.* 1987;3(3):173-181.
5. Gartsman GM, O'Connor DP. Arthroscopic rotator cuff repair with and without arthroscopic subacromial decompression: a prospective, randomized study of one-year outcomes. *J Shoulder Elbow Surg.* 2004;13(4):424-426.
6. Goldberg BA, Nowinski RJ, Matsen FA III. Outcome of nonoperative management of full-thickness rotator cuff tears. *Clin Orthop Relat Res.* 2001;382:99-107.
7. Henkus HE, de Witte PB, Nelissen RG, Brand R, van Arkel ER. Bursectomy compared with acromioplasty in the management of subacromial impingement syndrome: a prospective randomised study. *J Bone Joint Surg Br.* 2009;91(4):504-510.
8. Ketola S, Lehtinen J, Arnala I, et al. Does arthroscopic acromioplasty provide any additional value in the treatment of shoulder impingement syndrome? A two-year randomised controlled trial. *J Bone Joint Surg Br.* 2009;91(10):1326-1334.
9. Lenth RV. Java applets for power and sample size [computer software]. Available at: <http://www.stat.uiowa.edu/~rlenth/Power>. Accessed July 10, 2013.
10. MacDonald P, McRae S, Leiter J, Mascarenhas R, Lapner P. Arthroscopic rotator cuff repair with and without acromioplasty in the treatment of full-thickness rotator cuff tears: a multicenter, randomized controlled trial. *J Bone Joint Surg Am.* 2011;93(21):1953-1960.
11. MacGillivray JD, Fealy S, Potter HG, O'Brien SJ. Multiplanar analysis of acromion morphology. *Am J Sports Med.* 1998;26(6):836-840.
12. Michener LA, McClure PW, Sennett BJ. American Shoulder and Elbow Surgeons Standardized Shoulder Assessment Form, patient self-report section: reliability, validity, and responsiveness. *J Shoulder Elbow Surg.* 2002;11(6):587-594.
13. Milano G, Grasso A, Salvatore M, Zarelli D, Deriu L, Fabbriani C. Arthroscopic rotator cuff repair with and without subacromial decompression: a prospective randomized study. *Arthroscopy.* 2007;23(1):81-88.
14. Neer CS II. Anterior acromioplasty for the chronic impingement syndrome in the shoulder. 1972. *J Bone Joint Surg Am.* 2005;87(6):1399.
15. Ogata S, Uthoff HK. Acromial enthesopathy and rotator cuff tear: a radiologic and histologic postmortem investigation of the coracoacromial arch. *Clin Orthop Relat Res.* 1990;254:39-48.
16. Roy JS, MacDermid JC, Woodhouse LJ. Measuring shoulder function: a systematic review of four questionnaires. *Arthritis Rheum.* 2009;61(5):623-632.



17. Sher JS, Iannotti JP, Warner JJ, Groff Y, Williams GR. Surgical treatment of postoperative deltoid origin disruption. *Clin Orthop Relat Res.* 1997;343:93-98.
18. Shin SJ, Oh JH, Chung SW, Song MH. The efficacy of acromioplasty in the arthroscopic repair of small- to medium-sized rotator cuff tears without acromial spur: prospective comparative study. *Arthroscopy.* 2012;28(5):628-635.
19. Spangehl MJ, Hawkins RH, McCormack RG, Loomer RL. Arthroscopic versus open acromioplasty: a prospective, randomized, blinded study. *J Shoulder Elbow Surg.* 2002;11(2):101-107.
20. Tashjian RZ, Deloach J, Green A, Porucznik CA, Powell AP. Minimal clinically important differences in ASES and simple shoulder test scores after nonoperative treatment of rotator cuff disease. *J Bone Joint Surg Am.* 2010;92(2):296-303.
21. Yu E, Cil A, Harmsen WS, Schleck C, Sperling JW, Cofield RH. Arthroscopy and the dramatic increase in frequency of anterior acromioplasty from 1980 to 2005: an epidemiologic study. *Arthroscopy.* 2010;26(9 suppl):S142-147.
22. Zhang AL, Montgomery SR, Ngo SS, Hame SL, Wang JC, Gamradt SC. Analysis of rotator cuff repair trends in a large private insurance population. *Arthroscopy.* 2013;29(4):623-629.

---

For reprints and permission queries, please visit SAGE's Web site at <http://www.sagepub.com/journalsPermissions.nav>