



# Glenoid Diameter Is an Inaccurate Method for Percent Glenoid Bone Loss Quantification: Analysis and Techniques for Improved Accuracy

Sanjeev Bhatia, M.D., Anil Saigal, M.S., Rachel M. Frank, M.D., Bernard R. Bach Jr., M.D., Brian J. Cole, M.D., M.B.A., Anthony A. Romeo, M.D., and Nikhil N. Verma, M.D.

**Purpose:** To compare diameter-based glenoid bone loss quantification with a true geometric calculation for the area of a circular segment. **Methods:** By use of Maxima 12.01.0 mathematics modeling software (Macysma, Boston, MA), the diameter-based glenoid bone loss equation ( $\% \text{ Bone loss} = [\text{Defect width } (w)/\text{Inferior glenoid circle diameter } (D)] \times 100\%$ ) was compared with a true geometric calculation for the area of a circular segment of the glenoid (Wolfram Research, Champaign, IL) rearranged in terms of  $w$  and  $D$ :  $\text{Percent bone loss} = (100/2\pi) (2 \times \arccos [1 - 2 (w/D)] - \sin \{2 \times \arccos [1 - 2 (w/D)]\})$ . Percent error was calculated by taking the difference between the diameter equation and the true geometric calculation at varying true glenoid defect widths ( $w$ ) (0% to 50% of diameter). **Results:** The commonly used diameter equation overestimated true glenoid bone loss at all values of  $w$  except at 0% and 50% of the diameter. The mean overestimation error was  $3.9\% \pm 1.9\%$  (range, 0.0% to 5.8%), with the maximum error occurring when  $w$  was 20% of the diameter: At this value,  $w/D \times 100\%$  (diameter equation) predicts 20% bone loss when true bone loss is actually 14.2%. **Conclusions:** Diameter-based glenoid bone loss quantification overestimates true glenoid bone loss, with the maximum error occurring when theorized bone loss is 20%. To address situations for which a diameter-based bone loss quantification method must be performed or to improve the accuracy of surface-area calculations in previous diameter-based bone loss estimations, a corrective factor can be applied. Clinicians quantifying glenoid loss to make treatment decisions should be aware of the measurement methods used in the biomechanical studies on which they are basing their surgical decisions. **Clinical Relevance:** Diameter-based glenoid bone loss quantification overestimates true glenoid bone loss, with the maximum error occurring when theorized bone loss is 20%, a commonly used threshold for bone grafting.

The integrity of the bony architecture of the glenoid has recently been highlighted as one of the most important factors influencing the success of treatment in patients with glenohumeral instability.<sup>1,2</sup> After a

traumatic anterior shoulder dislocation initially occurs, an associated glenoid rim fracture may compromise the fundamental static restraints of the glenohumeral joint, thereby making future shoulder instability events more likely.<sup>1,3,4</sup> Loss of the glenoid's osseous conformity significantly inhibits its ability to withstand shear stress.<sup>5</sup> Over time, recurrent dislocations may further propagate attritional bone loss, leading to additional instability.<sup>4</sup>

In patients with recurrent anterior shoulder instability, the principles of surgical management are guided by the extent of glenoid osseous deficiency, in addition to other factors such as humeral bone defects, surgeon experience, and patient-specific considerations such as work and athletic demands.<sup>1,3</sup> Cadaveric studies have shown that as the amount of glenoid bone loss approaches 15% to 20% of the anterior glenoid surface, significant alterations in the biomechanical stability of the glenohumeral joint occur.<sup>6</sup> For this reason, current treatment algorithms in high-demand patients with

From the Department of Orthopaedic Surgery, Rush University Medical Center, Chicago Illinois, U.S.A.

The authors report the following potential conflict of interest or source of funding: B.J.C. receives support from Arthrex, Regents, Zimmer, DJ Orthopedics, and Aricept. Research support from Johnson & Johnson, Medicos, and Zimmer. A.A.R. receives support from Arthrex. Research support from Arthrex, DJO Surgical, Smith & Nephew, and Össur. N.N.V. receives support from Minivasive, Smith & Nephew, Vindico Medial-Orthopedics Hyperguide, Cymedica, Minivasive, and Omeros. Research support from Johnson & Johnson, Medipost, and Zimmer.

Received May 5, 2014; accepted February 16, 2015.

Address correspondence to Rachel M. Frank, M.D., Department of Orthopaedic Surgery, Rush University Medical Center, 1611 W Harrison St, Ste 300, Chicago, IL 60612, U.S.A. E-mail: [rmfrank3@gmail.com](mailto:rmfrank3@gmail.com)

© 2015 by the Arthroscopy Association of North America

0749-8063/14387/\$36.00

<http://dx.doi.org/10.1016/j.arthro.2015.02.020>

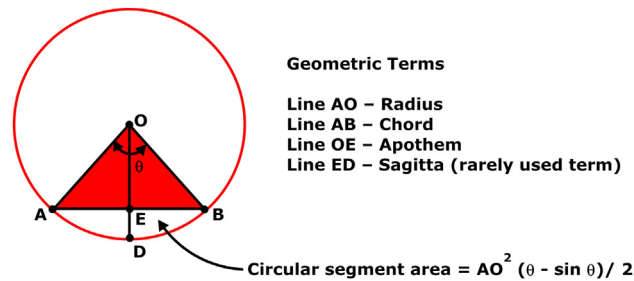
recurrent anterior shoulder instability suggest that an open procedure, such as the Latarjet procedure or bone grafting with autologous iliac crest or distal tibial allograft, should be strongly considered over a soft tissue—only repair when quantified bone loss exceeds 20%.<sup>1,3,4</sup>

Although surgical decision making in patients with recurrent shoulder instability depends on the quantification of glenoid osseous deficiency, quantification techniques are still somewhat limited, primarily because of the non-geometric shape of the glenoid. Huysmans et al.,<sup>7</sup> in a cadaveric study involving 40 scapulae, noted that the shape of the inferior two-thirds of the glenoid can be modeled as a true circle. Accordingly, this analogy has now been widely used in most mathematical quantification schemes for glenoid bone loss calculation to apply principles of geometry to the unusually shaped bone.<sup>1,3,4,8-10</sup> One of the most common glenoid bone loss quantification methods described in the literature uses the diameter of the “best-fit circle”—as measured on a 3-dimensional (3D) computed tomography (CT) en face view of the glenoid—as a guide for measuring bone loss.<sup>3,11</sup> Simply put, by measuring the width of the osseous defect and dividing it by the diameter of the best-fit circle, the percentage defect can be calculated. As shown by various authors, this method is easily determined with a CT scan, as well as arthroscopically, using the glenoid bare spot as an estimation of the center of the circle.<sup>3,8,10-12</sup>

Although diameter-based quantification schemes are easy to perform with advanced imaging or arthroscopic tools, the mathematical accuracy of surface-area calculations involving this technique has never been validated. Geometrically, when one is modeling the inferior aspect of the glenoid as a true circle, the glenoid bone defect is exactly analogous to a circular segment, a figure with a very complex area calculation. Therefore the purpose of this study was to compare diameter-based glenoid bone loss quantification with the true geometric calculation for the area of a circular segment. Given that the diameter-based quantification scheme incorrectly assumes that the geometric area calculation of a circular segment is analogous to an area calculation of a segment of a square, it was hypothesized that this method overestimates actual glenoid bone loss.

### Methods

As noted in the literature, glenoid bone loss is frequently calculated with a simple diameter-based equation defined by defect width ( $w$ ) and inferior glenoid best-fit circle diameter ( $D$ ): Percent bone loss =  $w/D \times 100\%$ .<sup>3,8,11,12</sup> In geometry, the calculation of the area of a circular segment—an analogous figure



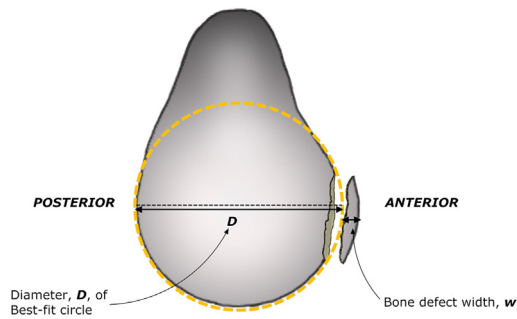
**Fig 1.** In geometry, a circular segment is an area of a circle “cut off” from the rest of the circle by a secant or chord. This relation most closely resembles glenoid bone loss quantification schemes that model the inferior glenoid as a circle. The calculation of the area of a circular segment is far more complex than simply taking a percentage of the diameter and often requires an understanding of the circle’s  $\theta$  angle (measured in radians).

to that of a glenoid bone defect—is far more complex and often requires an understanding of the circle’s  $\theta$  angle (measured in radians), in addition to the radius and possibly also the chord distance:  $R^2 (\theta - \sin \theta) / 2$  (Wolfram Research, Champaign, IL) (Fig 1, Appendix). By rearranging this equation in terms of  $w$  and  $D$ , the 2 variables central to the diameter-based equation, a geometrical proof can be performed to determine accuracy.

### Construction of Geometrical Proof

By use of the expertise of a mathematics consultant (A.S.) with proficiency in complex equation modeling and Maxima 12.01.0 mathematics modeling software (Macysma, Boston, MA), the true geometric calculation for the area of a circular segment (Wolfram Research) was rearranged in terms of  $w$  and  $D$ , the 2 variables necessary for diameter-based bone loss quantification. The resultant equation, in terms of  $w$  and  $D$ , was as follows: Percent bone loss =  $(100/2\pi) (2 \times \arccos [1 - 2 (w/D)] - \sin \{2 \times \arccos [1 - 2 (w/D)]\})$  (Fig 2).

To compare the accuracy of the diameter-based quantification method with the true geometric calculation for the area of a circular segment, each equation was modeled at varying true glenoid defect widths ( $w$ ) (0% to 50% of diameter). For accuracy in comparisons, all levels of  $w$  were modeled within this range (0% to 50% of diameter). Percent error was then calculated and graphed by taking the difference between the diameter equation and the true geometric calculation at varying true glenoid defect widths ( $w$ ) (0% to 50% of diameter). Because we sought to deconstruct the mathematics involved in comparing the diameter equation with that of a true geometric calculation, imaging modalities were not used in this study.



**Diameter Equation:** Percent Bone Loss =  $\frac{w}{D} \times 100\%$

**True Geometric Calculation:** Percent Bone Loss =  $\left(\frac{1}{2\pi}\right)(2 * \cos(1-2(w/D)\pi) - \sin(2 * \cos(1-2(w/D)\pi))) \times 100\%$

**Fig 2.** By use of a mathematics consultant with expertise in complex equation modeling and Maxima 12.01.0 mathematics modeling software, the true geometric calculation for the area of a circular segment was rearranged in terms of defect width and diameter, the 2 variables necessary for diameter-based bone loss quantification. To measure these 2 variables, a best-fit circle is inscribed on the inferior two-thirds of the glenoid. The diameter of this circle represents the diameter ( $D$ ) of the glenoid before injury, whereas the bone defect width ( $w$ ) represents the bone missing from the circle. Reprinted with permission.<sup>3</sup>

## Results

The commonly used diameter equation overestimated true glenoid bone loss at all values of  $w$  (width) except when  $w$  was 0% and 50% of the diameter ( $D$ ). A summary comparing diameter-based equation glenoid bone loss estimations with actual glenoid bone loss based on corresponding surface-area calculations of the inferior glenoid is provided in Table 1. The mean overestimation error was  $3.9\% \pm 1.9\%$  (range, 0.0% to 5.8%). Interestingly, the maximum error in the diameter-based equation occurred when the defect width ( $w$ ) was 20% of the diameter ( $D$ ) (Fig 3). At this value,  $w/D \times 100\%$  (diameter equation) predicted 20% bone loss when true bone loss was actually 14.2%.

## Discussion

The principal findings of this study suggest that determining percent surface-area glenoid bone loss based on the glenoid diameter is inaccurate. Diameter-based glenoid bone loss quantification methods only represent the deficit in anteroposterior width of the glenoid and overestimate the true surface-area glenoid bone loss, with the maximum error occurring when defect width ( $w$ ) is 20% of the glenoid diameter ( $D$ ). Such a scenario falsely results in diameter-based estimation of glenoid bone loss to be 20%, a threshold used by many surgeons for determining the need for

open bone grafting versus an arthroscopic approach for shoulder stabilization. It is important to note in the original work conducted by Burkhart et al.<sup>8</sup> describing diameter-based glenoid bone loss quantification methods, they did not claim that glenoid diameter equals glenoid surface area. Nevertheless, because this is a relatively easy parameter to measure, many clinicians have interpreted their study findings falsely, using the diameter of the glenoid as a method for calculating glenoid bone loss, and therefore may have overestimated the true amount of glenoid bone loss.

Although the mathematics necessary for calculating the area of a circular segment—an analogous figure to that of a glenoid bone defect when the inferior glenoid is modeled as a circle—is complex, conceptualizing why a diameter-based quantification scheme may overestimate bone loss is more straightforward. Simply put, a diameter-based scheme incorrectly assumes that the geometric area calculation of a circular segment is analogous to an area calculation of a segment of a square (Fig 4A). For a square, calculating the percent area of a segment (relative to the total area of the square) can easily be performed by dividing the width of the segment by the total length of the square. Unfortunately, this model cannot be applied to a true circle because of its shape, and applying this model results in an overestimation error (Fig 4B). Furthermore, when one is applying this method arthroscopically by relying on the bare spot as a reference point, the accuracy of calculations of the defect size may be inaccurate because the bare spot is not located in the exact center of the inferior glenoid circle.<sup>13,14</sup>

Errors in glenoid bone loss quantification during surgical decision making in patients with recurrent anterior shoulder instability may result in poor treatment decisions.<sup>3,4</sup> It is interesting to note that the maximum error in diameter-based glenoid bone loss quantification schemes occurred when the defect width ( $w$ ) was 20% of the diameter ( $D$ ). At this value,  $w/D \times 100\%$  (diameter equation) predicted 20% bone loss (a threshold for strongly considering an open procedure) when true bone loss was actually 14.2%. By overestimating the actual degree of glenoid bone loss (as defined by the surface area of the glenoid) using a diameter-based scheme, it is conceivable that a patient with recurrent anterior shoulder instability could theoretically be steered toward an open bony augmentation procedure when an arthroscopic soft tissue—only procedure may suffice.

By the same token, it is also conceivable that the threshold for measuring the critical limit for surface-area bone loss that results in osseous instability of the glenoid may be inaccurate, given the reliance on diameter-based bone loss quantification schemes in previous studies.<sup>8,12,15-17</sup> In a classic biomechanical

**Table 1.** Comparison Between Diameter-Based Equation Glenoid Bone Loss Estimations and Actual Glenoid Bone Loss Based on Corresponding Surface-Area Calculations of Inferior Glenoid

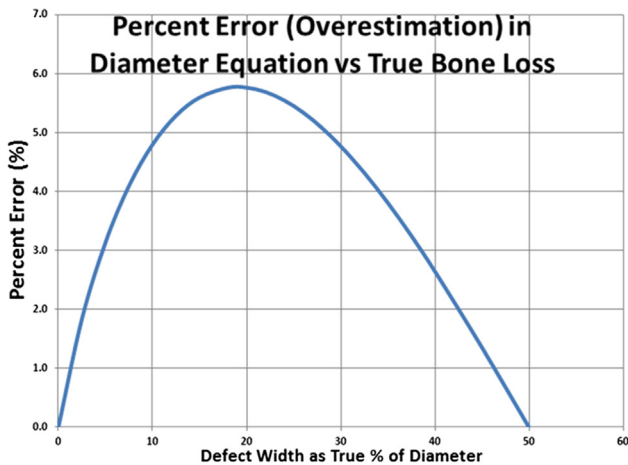
Bone Defect Width as % of Diameter	Diameter Equation Estimation of Glenoid Bone Loss, %	Actual Glenoid Bone Loss Based on Surface Area, %	Overestimation Error in Diameter Equation, %	Comments
0	0	0.0	0.0	Zero error
2.5	2.5	0.7	1.8	Increasing error
5	5	1.9	3.1	Increasing error
7.5	7.5	3.4	4.1	Increasing error
10	10	5.2	4.8	Increasing error
12.5	12.5	7.2	5.3	Increasing error
15	15	9.4	5.6	Increasing error
18	18	12.2	5.8	Maximum error
20	20	14.2	5.8	Maximum error
22	22	16.3	5.7	Decreasing error
24	24	18.5	5.5	Decreasing error
26	26	20.7	5.3	Decreasing error
28	28	22.9	5.1	Decreasing error
30	30	25.2	4.8	Decreasing error
32.5	32.5	28.2	4.3	Decreasing error
35	35	31.2	3.8	Decreasing error
37.5	37.5	34.3	3.2	Decreasing error
40	40	37.4	2.6	Decreasing error
45	45	43.6	1.4	Decreasing error
50	50	50.0	0.0	Zero error

NOTE. Overestimation error has been quantified and can be used as a corrective factor when using a diameter-based bone loss quantification scheme.

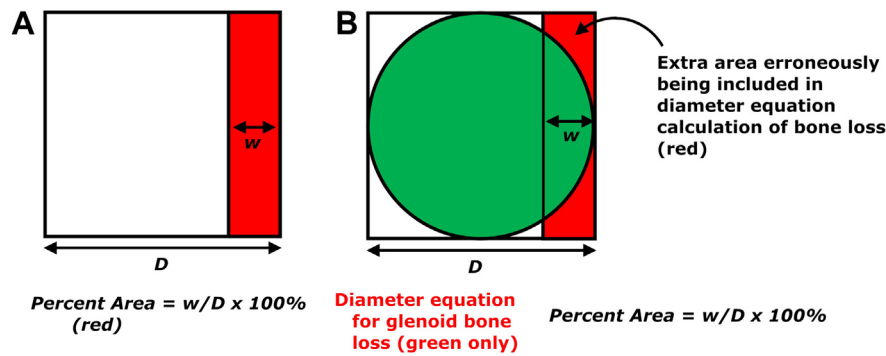
study, Itoi et al.<sup>6</sup> performed sequential osteotomies resulting in a progressive removal of bone from the anteroinferior portion of 10 cadaveric glenoid specimens to ascertain the critical amount of bone loss

resulting in glenohumeral instability. They correctly found that glenohumeral instability was significantly increased when the width of the defect approached 6.8 mm. A percent glenoid length quantification method was then used to conclude that this amount of bone loss corresponds to 21% of the glenoid length. As described by Piasecki et al.,<sup>1</sup> this 21% threshold must be interpreted with care because it is neither a diameter-based threshold nor a surface-area calculation. In a similar manner, in patients with recurrent anterior shoulder instability, Lo et al.<sup>17</sup> used arthroscopy to clinically measure the anteroposterior widths of glenoids that were determined to have an inverted-pear appearance. After measuring the width of a bone defect that resulted in the inverted-pear glenoid shape—7.8 to 8.6 mm accordingly—they then extrapolated these measurements into a percent bone loss threshold using the diameter-based equation. They concluded that 28.8% to 36% of bone loss in the anteroposterior dimension is necessary to result in an inverted pear-shaped glenoid, a clinically observed morphology that results in an inherently unstable glenoid. Although they did not extrapolate this into a surface-area calculation, their work has become a commonly used threshold when interpreting surface-area measurements from advanced imaging software; it should be noted that significantly less surface-area bone loss is necessary to result in an inverted pear-shaped glenoid.<sup>1,18</sup>

Although this is the first work to quantify the percent error inherent to diameter-based glenoid surface-area



**Fig 3.** Percent overestimation error inherent to diameter-based glenoid bone loss quantification methods. The commonly used diameter equation overestimated true glenoid bone loss at all values of width (*w*) except when *w* was 0% and 50% of the diameter (*D*). The mean overestimation error was 3.9% ± 1.9% (range, 0.0% to 5.8%). Interestingly, the maximum error in the diameter-based equation occurred when the defect *w* was 20% of the *D*. At this value, *w/D* × 100% (diameter equation) predicted 20% bone loss when true bone loss was actually 14.2%.



**Fig 4.** (A) Illustration showing how overestimation of circular segment surface area occurs when diameter is used. In a square, percent diameter can be used for accurate estimations of the percent surface area of a segment because of its geometric properties—all sides of the square are equal in length. (B) In a circle, percent diameter does not accurately reflect the percent surface area of a circular segment because this method erroneously includes the area of the corners of the square, which is not congruous with the circle. Thus overestimation of area occurs. ( $D$ , diameter;  $w$ , width.)

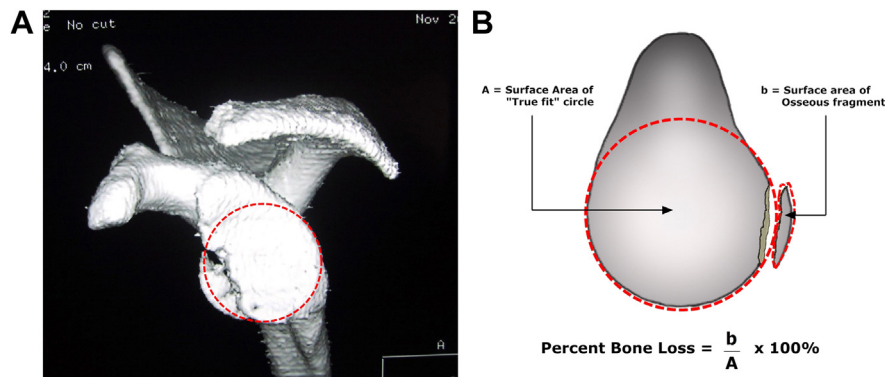
quantification methods and illustrate its variability, other authors have alluded to the same overestimation error noted in this study.<sup>1,18</sup> Sugaya et al.,<sup>18</sup> in a clinical series involving 42 patients with chronic recurrent glenohumeral instability, calculated glenoid bone loss by use of 2 methods—a surface-area digital calculation with 3D CT scan and a diameter-based equation—and noted that the 2 values were slightly different. They concluded that digitally measuring the surface area with the aid of a computer was more accurate than the diameter-based method, which was deemed “close.” Similarly, Piasecki et al.,<sup>1</sup> in a review, recently suggested that glenoid bone loss quantification is overestimated when the diameter of the inferior circle is used for bone loss quantification rather than the area ratio of the defect and inferior glenoid circle.

Certainly, there is clear variability in previously published studies regarding which percentage of bone loss constitutes the need for bone grafting. This percentage is reported to be as low as 15% in some studies and as high as 30% glenoid bone loss in other studies. Importantly, these percentages—regardless of the actual number—may, in fact, not be valid because they may have been measured inaccurately or interpreted incorrectly by the “circle method.” The results from our study underscore the need to accurately measure surface-area bone loss in clinical and biomechanical models of glenohumeral instability to validate the exact surface-area percentage of loss required for consideration of bone grafting (as opposed to soft-tissue reconstruction alone).

Given the errors associated with using the diameter of the inferior glenoid for surface-area bone loss quantification, a variety of alternative methods may be tried to improve accuracy. As described by Sugaya et al.,<sup>11,19</sup> digitally measuring the area of both the best-fit circle on the inferior glenoid and the area of the bone defect

may allow for improved accuracy.<sup>1,3,4</sup> To perform this technique, a best-fit circle is inscribed on a 3D CT en face view of the affected glenoid with humeral head subtraction. The area of this circle is digitally measured using specialized software and recorded. Next, the defect is carefully outlined and defined as the area of missing bone within the best-fit circle (Fig 5). Although the shape of this structure will inherently be amorphous, its area can be digitally calculated because the software can count the number of pixels within. Once the area of the defect and the area of the best-fit circle are known, the values can be inputted into the following formula<sup>3,4,19</sup>: Percent bone loss = Defect area/Circle area  $\times$  100%. Another technique for improving accuracy, the Pico method, was first described by Baudi et al.<sup>20</sup> In this method a CT scan of the patient’s contralateral uninjured glenoid is performed. By use of a 3D CT en face view of the uninjured glenoid, a best-fit circle is drawn on the inferior portion of the glenoid and its area is digitally calculated using multiplanar reconstruction software. By superimposing this circle onto the inferior portion of the injured glenoid, the bone defect can easily be outlined on the anterior glenoid and its area digitally calculated.<sup>3,20</sup> These 2 area calculations can then be inputted into the same formula as previously noted.

Recently, Altan et al.<sup>21</sup> used 3D CT scans of 36 patients to compare 2 different techniques for measuring the size of glenoid bone defects. One technique was based on linear measurement of bone loss (glenoid index<sup>22</sup>), whereas the other was based on surface-area measurement, essentially using a best-fit circle and the following formula<sup>18</sup>: Percent bone loss = Defect area/Circle area  $\times$  100%. The authors found a near-perfect correlation between the methods when the defect area was less than 6% of the inferior glenoid circle but noted a worsening correlation with larger defects, in



**Fig 5.** As described by Sugaya et al.,<sup>11,19</sup> digitally measuring the area of both the best-fit circle on the inferior glenoid and the area of the bone defect may allow for improved accuracy.<sup>1,3,4</sup> (A) To perform this technique, a best-fit circle is inscribed on a 3-dimensional computed tomography en face view of the affected glenoid with humeral head subtraction, as noted on this left shoulder. The area of this circle is digitally measured using specialized software and recorded. (B) Next, the defect is carefully outlined and defined as the area of missing bone within the best-fit circle. Although the shape of this structure will inherently be amorphous, its area can be digitally calculated because the software can count the number of pixels within. Once the area of the defect and the area of the best-fit circle are known, the values can be inputted into the following formula<sup>3,4,19</sup>: Percent bone loss = Defect area/Circle area  $\times$  100%. It is important to note that many times a fragment will not actually be present—in these situations, bone loss is believed to be attritional and not acute. Reprinted with permission.<sup>3</sup>

particular after the defect reached 14% of the inferior glenoid circle. Clearly, the inconsistency of calculating glenoid bone loss using a circle-based method can be difficult, and our study suggests incorporating a corrective factor to improve accuracy. Although mathematically quantifying the corrective factor is too cumbersome for clinical practice, simply understanding that surface-area bone loss is about 5% less than what diameter calculations would suggest at bone loss widths of 10% to 30% of diameter is useful in guiding clinical decision making (Table 1).

Digital quantification of area on a 3D CT en face view of the glenoid with humeral head subtraction is an excellent means for area calculation because it allows for the measurement of both geometric and non-geometric shapes. Although these methods are extremely accurate, they are often difficult to perform without the aid of advanced software programs. ImageJ, a public-domain Java image processing program that is freely available from the National Institutes of Health (<http://rsb.info.nih.gov/ij/>), has been shown to be extremely effective at measuring the area of elliptical or irregularly shaped selections.<sup>23-25</sup> The program simplifies area calculations by digitally measuring the number of pixels within a selection. As such, it may be easily applied to the previously mentioned glenoid bone loss quantification schemes for enhancement of accuracy in measuring the area of a best-fit circle, as well as the area of the irregularly shaped bone defect.<sup>19,20</sup>

Diameter-based glenoid bone loss quantification has the inherent advantage of being simple, easy to

conceptualize, and appropriate for intraoperative measurements of glenoid bone loss with the use of a graduated probe. In situations for which this technique is deemed necessary or most convenient, a correction factor for conversion between percent diameter and surface area can be applied for improved accuracy (Table 1). Alternatively, diameter-based quantification, when solely used for determining a ratio of defect width to glenoid width as described by Burkhart et al.,<sup>8</sup> could still have a role in identifying troublesome bone defects; however, care should be taken to properly distinguish this from surface-area calculations of glenoid bone loss.

### Limitations

There are some limitations to this study. First, these results do not consider which amount of glenoid bone loss is deemed clinically relevant and, thus, do not consider at which point the differences in the quantification strategies becomes clinically relevant. Because of this, it is difficult to make treatment-type recommendations for patients with glenoid bone loss. Certainly, in future studies, the methods presented in this study could be used in a biomechanical or clinical model to validate what percentage of glenoid loss constitutes the need for bone grafting. In addition, our model does not account for the concavity of the glenoid, which may affect the calculations. Finally, the lower portion of the glenoid is assumed to represent a circle, and it could be argued that this area of the glenoid should be modeled as the area of an arc of a sphere, which may also affect the calculations.

## Conclusions

Diameter-based glenoid bone loss quantification overestimates true glenoid bone loss, with the maximum error occurring when theorized bone loss is 20%. To address situations for which a diameter-based bone loss quantification method must be performed or to improve the accuracy of surface-area calculations in previous diameter-based bone loss estimations, a corrective factor can be applied. Clinicians quantifying glenoid loss to make treatment decisions should be aware of the measurement methods used in the biomechanical studies on which they are basing their surgical decisions.

## References

- Piasecki DP, Verma NN, Romeo AA, Levine WN, Bach BR Jr, Provencher MT. Glenoid bone deficiency in recurrent anterior shoulder instability: Diagnosis and management. *J Am Acad Orthop Surg* 2009;17:482-493.
- Rowe CR, Zarins B, Ciullo JV. Recurrent anterior dislocation of the shoulder after surgical repair. Apparent causes of failure and treatment. *J Bone Joint Surg Am* 1984;66:159-168.
- Provencher MT, Bhatia S, Ghodadra NS, et al. Recurrent shoulder instability: Current concepts for evaluation and management of glenoid bone loss. *J Bone Joint Surg Am* 2010;92:133-151 (suppl 2).
- Bhatia S, Ghodadra NS, Romeo AA, et al. The importance of the recognition and treatment of glenoid bone loss in an athletic population. *Sports Health* 2011;3:435-440.
- Mologne TS, Provencher MT, Menzel KA, Vachon TA, Dewing CB. Arthroscopic stabilization in patients with an inverted pear glenoid: Results in patients with bone loss of the anterior glenoid. *Am J Sports Med* 2007;35:1276-1283.
- Itoi E, Lee SB, Berglund LJ, Berge LL, An KN. The effect of a glenoid defect on anteroinferior stability of the shoulder after Bankart repair: A cadaveric study. *J Bone Joint Surg Am* 2000;82:35-46.
- Huysmans PE, Haen PS, Kidd M, Dhert WJ, Willems JW. The shape of the inferior part of the glenoid: A cadaveric study. *J Shoulder Elbow Surg* 2006;15:759-763.
- Burkhart SS, Debeer JF, Tehrany AM, Parten PM. Quantifying glenoid bone loss arthroscopically in shoulder instability. *Arthroscopy* 2002;18:488-491.
- Ghodadra N, Gupta A, Romeo AA, et al. Normalization of glenohumeral articular contact pressures after Latarjet or iliac crest bone-grafting. *J Bone Joint Surg Am* 2010;92:1478-1489.
- Provencher MT, Detterline AJ, Ghodadra N, et al. Measurement of glenoid bone loss: A comparison of measurement error between 45 degrees and 0 degrees bone loss models and with different posterior arthroscopy portal locations. *Am J Sports Med* 2008;36:1132-1138.
- Sugaya H, Kon Y, Tsuchiya A. Arthroscopic repair of glenoid fractures using suture anchors. *Arthroscopy* 2005;21:635.
- Burkhart SS, De Beer JF. Traumatic glenohumeral bone defects and their relationship to failure of arthroscopic Bankart repairs: Significance of the inverted-pear glenoid and the humeral engaging Hill-Sachs lesion. *Arthroscopy* 2000;16:677-694.
- Aigner F, Longato S, Fritsch H, Kralinger F. Anatomical considerations regarding the "bare spot" of the glenoid cavity. *Surg Radiol Anat* 2004;26:308-311.
- Kralinger F, Aigner F, Longato S, Rieger M, Wambacher M. Is the bare spot a consistent landmark for shoulder arthroscopy? A study of 20 embalmed glenoids with 3-dimensional computed tomographic reconstruction. *Arthroscopy* 2006;22:428-432.
- Yamamoto N, Itoi E, Abe H, et al. Effect of an anterior glenoid defect on anterior shoulder stability: A cadaveric study. *Am J Sports Med* 2009;37:949-954.
- Bigliani LU, Newton PM, Steinmann SP, Connor PM, McIlveen SJ. Glenoid rim lesions associated with recurrent anterior dislocation of the shoulder. *Am J Sports Med* 1998;26:41-45.
- Lo IK, Parten PM, Burkhart SS. The inverted pear glenoid: An indicator of significant glenoid bone loss. *Arthroscopy* 2004;20:169-174.
- Sugaya H, Moriishi J, Kanisawa I, Tsuchiya A. Arthroscopic osseous Bankart repair for chronic recurrent traumatic anterior glenohumeral instability. *J Bone Joint Surg Am* 2005;87:1752-1760.
- Sugaya H, Moriishi J, Dohi M, Kon Y, Tsuchiya A. Glenoid rim morphology in recurrent anterior glenohumeral instability. *J Bone Joint Surg Am* 2003;85:878-884.
- Baudi P, Righi P, Bolognesi D, et al. How to identify and calculate glenoid bone deficit. *Chir Organi Mov* 2005;90:145-152.
- Altan E, Ozbaydar MU, Tonbul M, Yalcin L. Comparison of two different measurement methods to determine glenoid bone defects: Area or width? *J Shoulder Elbow Surg* 2014;23:1215-1222.
- Chuang TY, Adams CR, Burkhart SS. Use of preoperative three-dimensional computed tomography to quantify glenoid bone loss in shoulder instability. *Arthroscopy* 2008;24:376-382.
- Patzkowski JC, Kirk KL, Orr JD, Waterman BR, Kirby JM, Hsu JR. Quantification of posterior ankle exposure through an Achilles tendon-splitting versus posterolateral approach. *Foot Ankle Int* 2012;33:900-904.
- Terry C, Sellami M, Fichel C, et al. Rapid method of quantification of tight-junction organization using image analysis. *Cytometry A* 2013;83:235-241.
- Bhatia S, Bell R, Frank RM, et al. Bony incorporation of soft tissue anterior cruciate ligament grafts in an animal model: Autograft versus allograft with low-dose gamma irradiation. *Am J Sports Med* 2012;40:1789-1798.

### Appendix: Derivation of Glenoid Bone Loss Formula

Derivation of the glenoid bone loss formula is shown in Appendix Figure 1. The area of a segment ( $A_s$ ) was defined as  $A_s = (R^2/2) (\theta - \sin \theta)$ , where  $\theta$  is in radians and  $R$  is any unit of distance ( $\pi$  equals  $180^\circ$ ). The area of a circle ( $A_c$ ) was defined as  $A_c = \pi R^2$ .

Segment area as a percentage of circular area—analogueous to true glenoid bone loss ( $Y$ )—was defined as  $Y = A_s/A_c$ , or  $Y = (1/2\pi) (\theta - \sin \theta)$ . However, the angle  $\theta$  is defined as  $\theta = 2 \times \arccos (d/R)$ . Substituting  $h$  (segment height) for  $d$  (height of the triangle), we obtain the following:

$$\theta = 2 \times \arccos [1 - (h/R)]$$

Substituting  $R$  with  $D/2$  (where  $D$  is the diameter), we obtain the following:

$$\theta = 2 \times \arccos [1 - (2h/D)]$$

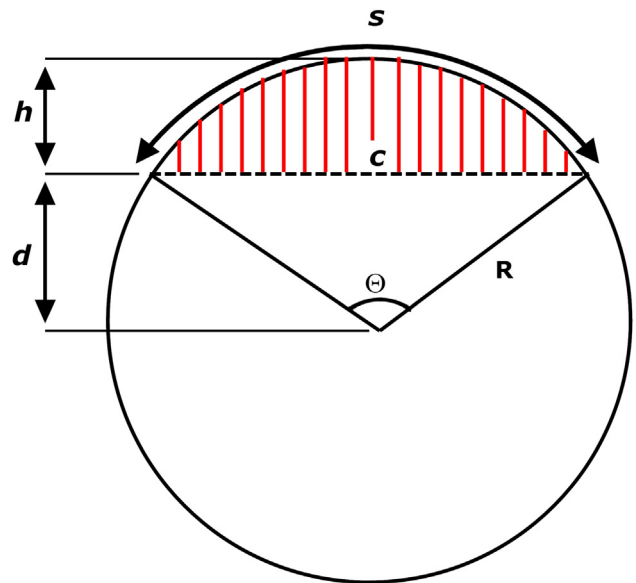
Substituting the value of  $\theta$  in the expression for  $Y$  described earlier, we obtain the following:

$$Y = (1/2\pi) \{ 2 \times \arccos [1 - (2h/D)] - \sin [2 \times \arccos [1 - (2h/D)]] \}$$

Recognizing that  $h$  represents the width of the defect ( $D$  minus posterior-anterior distance, also represented as  $w$  in this article), we can express the diameter equation as  $X = h/D$ . We can now rewrite  $Y$  (true glenoid bone loss) in terms of  $X$  (diameter equation) as follows:

$$Y = (1/2\pi) \{ 2 \times \arccos (1 - 2X) - \sin [2 \times \arccos (1 - 2X)] \}$$

The true glenoid bone loss equation can also be expressed as a percent by multiplying the numerator by 100:



**Appendix Figure 1.** A circular segment (in red) is enclosed between a secant/chord (dashed line) and the arc whose endpoints equal those of the chord (the arc shown above the red area), where  $R$  is the radius of the circle,  $\theta$  is the central angle in degrees,  $\alpha$  is the central angle in radians,  $c$  is the chord length,  $s$  is the arc length,  $h$  is the height of the segment, and  $d$  is the height of the triangular portion.

$$Y = (100/2\pi) \{ 2 \times \arccos (1 - 2X) - \sin [2 \times \arccos (1 - 2X)] \}$$

For the same glenoid bone loss, the difference between  $Y$  and  $X$  represents the error at any specific value of  $X$ . This difference can be indicated as a percent.