

## Retrospective Analysis of Arthroscopic Management of Glenohumeral Degenerative Disease

Geoffrey S. Van Thiel, M.D., M.B.A., Steven Sheehan, B.S., Rachel M. Frank, B.S., Mark Slabaugh, M.D., Brian J. Cole, M.D., M.B.A., Gregory P. Nicholson, M.D., Anthony A. Romeo, M.D., and Nikhil N. Verma, M.D.

---

**Purpose:** The purpose of this study was to examine the results of arthroscopic debridement for isolated degenerative joint disease of the shoulder. **Methods:** We retrospectively identified 81 patients who had arthroscopic debridement to treat glenohumeral arthritis. Of these patients, 71 (88%) were available for follow-up. The preoperative Simple Shoulder Test score, American Shoulder and Elbow Surgeons score, Short Form 12 score, visual analog scale score for pain, and range of motion were recorded. These were compared against postoperative scores by use of the statistical paired *t* test. In addition, patients completed postoperative University of California, Los Angeles; Constant; and Single Assessment Numeric Evaluation scores. Forty-six preoperative radiographs were blindly evaluated and classified. Finally, the need for subsequent shoulder arthroplasty was recorded. **Results:** The mean follow-up for the 55 patients who did not progress to arthroplasty was 27 months. The mean preoperative and postoperative American Shoulder and Elbow Surgeons, Simple Shoulder Test, and pain visual analog scale scores all significantly improved ( $P < .05$ ). Furthermore, range of motion significantly improved ( $P < .05$ ) in flexion, abduction, and external rotation. Additional postoperative scores were as follows: University of California, Los Angeles, 28.3; Single Assessment Numeric Evaluation, 71.1; Constant score for affected shoulder, 72.0; and Constant score for unaffected shoulder, 78.5. Of the patients, 16 (22%) underwent arthroplasty at a mean of 10.1 months after debridement. Radiographic review showed that 13 shoulders with a mean joint space of 1.5 mm and grade 2.4 arthrosis went on to have shoulder arthroplasty. In contrast, 33 shoulders with a mean joint space of 2.6 mm and grade 1.9 arthrosis did not go on to have shoulder arthroplasty. **Conclusions:** Patients with residual joint space and an absence of large osteophytes can avoid arthroplasty and have increased function with decreased pain after arthroscopic debridement for degenerative joint disease. Significant risk factors for failure include the presence of grade 4 bipolar disease, joint space of less than 2 mm, and large osteophytes. **Level of Evidence:** Level IV, case series.

---

**D**egenerative disease of the glenohumeral joint is a significant problem primarily affecting older patients. However, in some cases it can also impact younger, active individuals. As shown by Matsen et al.,<sup>1</sup>

these patients have significant pain and are functionally limited when compared with patients with normal shoulders. Gartsman et al.<sup>2</sup> further illustrated a significant decrease in Short Form 36 variables with shoulder arthrosis. Thus, shoulder arthrosis creates a substantial patient burden.

Multiple sources can contribute to patient discomfort in addition to the joint degeneration, including labral pathology, biceps tenosynovitis, rotator cuff pathology, loose bodies, and articular cartilage damage. Initial treatment for these conditions consists of conservative management with physical therapy, injections, and activity modification.<sup>3,4</sup> However, if these measures fail and the patient

---

From Rush University Medical Center, Chicago, Illinois, U.S.A.

The authors report no conflict of interest.

Received July 25, 2009; accepted February 18, 2010.

Address correspondence and reprint requests to Geoffrey S. Van Thiel, M.D., M.B.A., 720 N Larrabee, Ste 1010, Chicago, IL 60654, U.S.A. E-mail: [Geoffrey\\_vanthiel@rush.edu](mailto:Geoffrey_vanthiel@rush.edu)

© 2010 by the Arthroscopy Association of North America

0749-8063/9445/\$36.00

doi:10.1016/j.arthro.2010.02.026

continues to have significant pain, the surgeon is left with relatively few options. Shoulder arthroplasty has been shown to provide good pain relief but has significant risks and results in postoperative limitations. In the younger and more active patient population, these post-replacement restrictions may impair lifestyle or job requirements. Furthermore, there is a heightened concern about prosthetic loosening and early failure in this patient population.

In lieu of arthroplasty, arthroscopy of the shoulder may provide improvements in symptoms and increases in shoulder function as well as prevent or delay the need for shoulder arthroplasty. Multiple arthroscopic techniques can be used, including debridement, chondroplasty, capsular release, biceps tenotomy or tenodesis, and subacromial decompression, in an attempt to improve symptoms and shoulder function. Limited reports to date have provided evidence that arthroscopic techniques may improve shoulder pain and function for patients with shoulder arthritis.<sup>4-6</sup>

The purpose of this study was to review the outcomes of patients who have undergone arthroscopic debridement procedures for glenohumeral degenerative joint disease at a single institution. The hypothesis was that arthroscopic management of shoulder arthritis would result in improvement in shoulder pain and function.

## METHODS

The study was reviewed by our institutional review board, and all patients provided informed consent. From 2001 to 2007, the senior surgeons' operative databases were reviewed based on Current Procedural Terminology coding, and 81 patients were retrospectively identi-

fied who had arthroscopic debridement for the management of glenohumeral arthritis. Of these patients, 71 (88%) were available for follow-up. The procedure was performed by 1 of 4 surgeons at a single institution. Inclusion criteria consisted of patients who had a preoperative and postoperative diagnosis of glenohumeral degenerative joint disease. Exclusion criteria included a postoperative diagnosis of adhesive capsulitis, concomitant labral, or rotator cuff repair and previous shoulder surgery within the last year. Patients were contacted and invited to return for follow-up evaluation. Subjective scoring scales were obtained and a physical examination performed by a single orthopaedic research fellow independent of the operating surgeon.

The study group consisted of 47 men and 24 women. The mean age was 47 years (range, 18 to 77 years). Given that pain generation in the shoulder is a multifactorial process, concomitant diagnoses included biceps tears/tendonitis, impingement syndromes, loose bodies, and SLAP tears with no rotator cuff tears (Table 1). Importantly, given the relatively young age of our patients, there were 12 postsurgical osteoarthritis/chondrolysis diagnoses. Previous operations included 12 previous stabilization procedures, 6 unspecified arthroscopic procedures, 1 rotator cuff repair, and 1 thermal capsulorrhaphy.

In this series the following procedures were performed in addition to the glenohumeral debridement: 44 capsular releases, 14 biceps tenodeses/tenotomies, 11 microfractures, 12 loose body/osteophyte removals, and 28 subacromial decompressions (Table 1). The operative reports were reviewed, and all patients were confirmed to have significant articular damage to the humerus and/or glenoid at the time of surgery.

**TABLE 1.** Concomitant Procedures for Patients in Non-Arthroplasty Subset (All Patients Had Debridement)

No.	Diagnosis	Capsular Release	Acromioplasty	Loose Body Removal or Osteophyte Resection	SAD	Biceps Tenotomy/Tenodesis	Microfracture
10	DJD	X					
7	DJD, loose body	X		X			
3	DJD, subacromial bursitis	X			X		
5	DJD, biceps	X				X	
5	DJD, AVN	X					X
4	DJD, biceps, impingement	X			X	X	
7	DJD, impingement	X	X		X		
3	DJD, impingement, biceps, subacromial bursitis	X	X		X	X	
6	DJD, impingement		X		X		X
3	DJD, impingement, loose body		X	X	X		
2	DJD, biceps, subacromial bursitis			X	X	X	

Abbreviations: SAD, subacromial decompression; DJD, degenerative joint disease; AVN, avascular necrosis.

The need for subsequent shoulder surgery, Simple Shoulder Test (SST) score, American Shoulder and Elbow Surgeons (ASES) score, Short Form 12 score, visual analog scale (VAS) for pain, and range of motion were recorded preoperatively and postoperatively. In addition, at the time of follow-up, patients were asked to complete the University of California, Los Angeles (UCLA), Constant, and Single Assessment Numeric Evaluation (SANE) scores. Finally, the patients were questioned about their willingness to undergo the procedure again.

Physical examination of the operative shoulder was conducted at the time of follow-up. Range-of-motion data were measured and recorded with a goniometer, including forward elevation in the scapular plane and external rotation with the arm at the side. Strength testing was performed with an Isobex handheld dynamometer (Cursor, Bern, Switzerland) for both forward elevation and external rotation at the side. A total of 3 measurements were made, and the mean was recorded.

In addition, 46 preoperative radiographs were blindly evaluated and classified by the amount of joint space narrowing (in millimeters) on the anteroposterior radiograph, as well as by the method proposed by Samilson and Prieto<sup>7,8</sup> (Fig 1). Arthritic shoulders were divided into 4 grades: 0, normal; 1, mild (osteophytes <3 mm on humeral head); 2, moderate (osteophytes between 3 and 7 mm on humeral head or glenoid rim); or 3, severe (osteophytes >7 mm with or without articular incongruity).<sup>7</sup> These findings were compared against postoperative outcomes.

### Statistical Analysis

All results were analyzed by statistical testing comparing preoperative measures with corresponding postoperative measures at the last follow-up. Paired *t* tests were performed, and results were considered statistically significant at  $P < .05$ . Multivariate regression was used to determine correlations between variables.

## RESULTS

Seventy-one patients were available for follow-up and were segmented into either an arthroplasty or non-arthroplasty subset; the mean age was 47 years (range, 18 to 77 years). At final follow-up, 16 (22%) had undergone shoulder replacement at a mean of 10.1 months (range, 2.5 to 27.2 months; SD, 6.41) after debridement; 4, hemiarthroplasty; 9, total shoulder arthroplasty; and 3, humeral head allograft. The remaining 55 patients comprise the non-arthroplasty subset. There were no statisti-

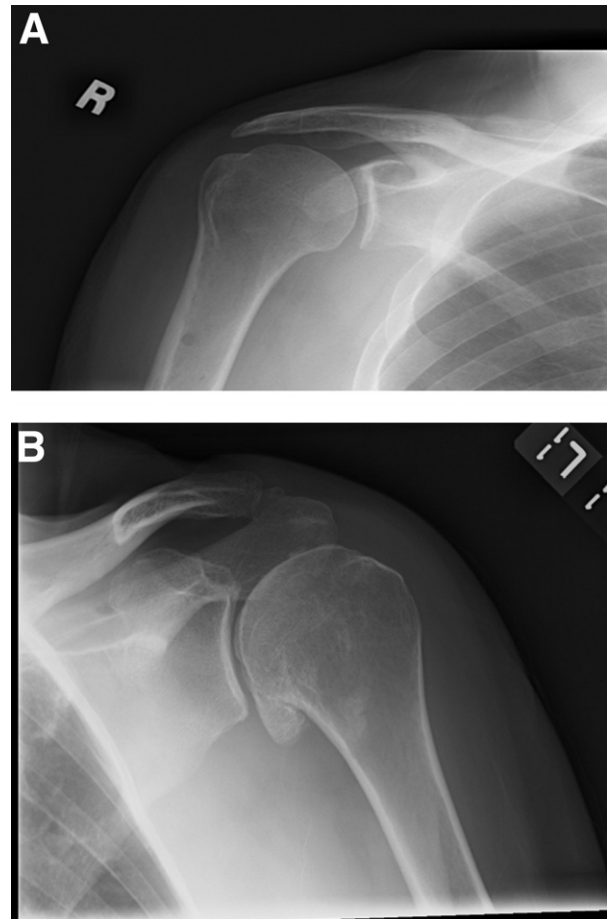


FIGURE 1. (A) Successful debridement with improved range of motion and pain. (B) Unsuccessful debridement. Patient progressed to arthroplasty. Note the large inferior humeral head osteophytes and decreased joint space.

cally significant differences between the 2 groups with regard to age or gender.

We blindly evaluated 46 preoperative radiographs (65%) for joint space narrowing on the anteroposterior radiograph in the plane of the scapula and using the classification system of Samilson and Prieto.<sup>7,8</sup> There was a significant decrease in joint space and an increase in classification between the 2 groups. The results are shown in Table 2.

In the non-arthroplasty group, the mean follow-up was 27 months (range; 12 to 90 months; SD, 20.1). In this group 39 patients had grade 4, 16 had grade 3, and 2 had grade 2 articular changes. Furthermore, 41 of these patients had bipolar articular damage, 12 had only humeral destruction, and 2 had isolated glenoid degenerative changes. With regard to shoulder outcome scores, there was a significant increase from

**TABLE 2.** Radiographic Classification: Joint Space on Anteroposterior Radiograph and Samilson and Prieto Classification

	Arthroplasty			Non-Arthroplasty			P Value
	Mean	Range	SD	Mean	Range	SD	
Joint space (mm)	1.5	0-4	1.37	2.6	0-6	1.70	<.05
Grade	2.5	1-3	0.81	1.9	1-3	0.80	<.05

preoperative values in ASES and SST scores, with a significant decrease in VAS. However, Short Form 12 values did not show a significant change. These values are shown in Table 3. Of the 55 patients available for follow-up, 37 had preoperative range of motion recorded. These patients had a significant increase in range of motion in flexion, abduction, and external rotation (Table 3). Preoperative Constant, UCLA, and SANE scores were not available, but postoperative scores are shown in Table 3. The mean Constant score ratio of the affected shoulder to the unaffected shoulder was 0.9. Regression analysis of the data showed no significant correlations between joint space and arthritic grade relating to patient SANE, ASES, SST, and VAS scores in the non-arthroplasty group. Lastly, 45 of the 55 patients (82%) who underwent arthroscopy said that they would repeat the procedure knowing the results they experienced, and none of them has undergone a subsequent procedure.

In the group who progressed to arthroplasty, all 16 patients had grade 4 articular cartilage damage and 14 of these patients had bipolar changes. There was significantly less joint space and larger humeral head

osteophytes on preoperative imaging when compared with the non-arthroplasty group (Table 2).

## DISCUSSION

The principal results of our study show that arthroscopic debridement can be a successful treatment adjunct for degenerative joint disease of the shoulder in select patients. We treated 71 patients with glenohumeral arthritis with arthroscopic debridement and followed them up at a mean of 27 months. Of these patients, 16 (22%) went on to shoulder replacement at a mean of 10 months. These patients routinely had less than 2 mm of joint space on the preoperative anteroposterior radiograph with substantial humeral head osteophytes. The remaining 55 patients had significant pain relief, improved functional scores, and increased range of motion after debridement. The significant differences on preoperative imaging combined with the improvements in the non-arthroplasty group suggest that the appropriately chosen patient can expect increased shoulder function and decreased pain with an arthroscopic debridement for degenerative joint disease.

**TABLE 3.** Shoulder Scores and Range of Motion

	Preoperatively			Postoperatively			P Value
	Mean	Range	SD	Mean	Range	SD	
SST	6.1	0-12	3.1	9.0	3-12	2.9	<.05
ASES	51.8	8-85	18.6	72.7	10-100	23.9	<.05
VAS	4.8	1-9	2.0	2.7	0-9	2.6	<.05
SF-12	35.9	27-43	4.5	36.1	23-42	5.5	>.05
Constant							
Affected				72.0	31.7-99.1	17.5	N/A
Unaffected				78.5	23.8-100	15.1	N/A
UCLA				28.3	16-35	5.3	N/A
SANE				71.1	5-100	24.6	
Range of motion (°)							
Flexion	137	80-180	29.9	157	90-180	22.4	<.05
Abduction	129	80-180	33.1	145	81-180	31.8	<.05
External rotation	48	10-90	20.2	63	12-90	21.1	<.05

Abbreviations: SF-12, Short Form 12; N/A, not applicable.



Ogilvie-Harris and Wiley<sup>9</sup> provided one of the first descriptions of arthroscopic management of osteoarthritis. They evaluated 54 patients at a mean of 3 years' follow-up and found that two-thirds of the cases with mild arthritis on arthroscopy did well with a debridement and about one-third of patients with severe degeneration had a good result. There were a variety of concomitant pathologies in these patients that were also addressed at the time of arthroscopy. Ellman et al.<sup>10</sup> identified a group of 18 patients who were being treated arthroscopically for impingement and had grade 2 or 3 glenohumeral arthritis. These patients were treated with debridement, and good short-term results were reported.

Furthermore, Weinstein et al.<sup>11</sup> evaluated the outcomes of patients who underwent glenohumeral debridement for arthritis at a mean follow-up of 34 months. Of these patients, 80% had good to excellent results, and of the patients with preoperative stiffness, 83% had improved range of motion postoperatively. This led the authors to conclude that glenohumeral debridement provided an effective step in the management of glenohumeral osteoarthritis. Of note, patients with a frozen shoulder were included in this group, and 52% of patients had grade 2 arthritic changes or lower. Thus, Cameron et al.<sup>12</sup> looked at patients with grade 4 osteochondral lesions that were treated with arthroscopic debridement. Of these patients, 87% stated that they would have the surgery again, and 88% achieved significantly less pain and greater range of motion. It was noted that this pain relief lasted a mean of 28 months, and the authors recommended adding a capsular release if there was a loss of 15° of motion in any plane.

Our reported results do support the use of arthroscopic debridement in the management of shoulder arthritis; however, longer-term follow-up is necessary to further elucidate the natural disease progression of the relatively young patients in our study. The mean age of the patients in this study does compare with the limited number of previous reports<sup>11,13</sup>; however, there are limitations to this study. Most notably, this was a retrospective analysis with no control group. These patients were "self-selected" and not considered to be candidates for arthroplasty based on the degree of disease on radiography, the patient's age or activity level, and/or the patient's desire to avoid arthroplasty. Therefore it must be noted that the findings in this group may not be extrapolated to a general group of patients with end-stage osteoarthritis in whom shoulder arthroplasty is indicated. Furthermore, if patients "self-selected" themselves based on their desire to avoid shoulder

replacement, this may be reflected in their subjective outcomes and satisfaction with the procedure. Second, radiographs were not available for all patients included in this study. Therefore we were limited in our ability to provide a comparison between patients who subsequently required shoulder arthroplasty and those who did not. However, there was an association between higher grade of joint space narrowing on radiographs and subsequent need for shoulder arthroplasty. Finally, Constant, UCLA, and SANE scores were not available for patients preoperatively.

## CONCLUSIONS

Patients with residual joint space and an absence of large osteophytes can avoid arthroplasty and have increased function with decreased pain after arthroscopic debridement for degenerative joint disease. Significant risk factors for failure include the presence of grade 4 bipolar disease, joint space of less than 2 mm, and large osteophytes.

## REFERENCES

1. Matsen FA III, Ziegler DW, DeBartolo SE. Patient self-assessment of health status and function in glenohumeral degenerative joint disease. *J Shoulder Elbow Surg* 1995;4:345-351.
2. Gartsman GM, Brinker MR, Khan M, Karahan M. Self-assessment of general health status in patients with five common shoulder conditions. *J Shoulder Elbow Surg* 1998;7:228-237.
3. Silverstein E, Leger R, Shea KP. The use of intra-articular hyaluron G-F 20 in the treatment of symptomatic osteoarthritis of the shoulder: A preliminary study. *Am J Sports Med* 2007;35:979-985.
4. Sinha I, Lee M, Cobiella C. Management of osteoarthritis of the glenohumeral joint. *Br J Hosp Med (Lond)* 2008;69:264-268.
5. Bishop JY, Flatow EL. Management of glenohumeral arthritis: A role for arthroscopy? *Orthop Clin North Am* 2003;34:559-566.
6. Richards DP, Burkhart SS. Arthroscopic debridement and capsular release for glenohumeral osteoarthritis. *Arthroscopy* 2007;23:1019-1022.
7. Brox JI, Lereim P, Merckoll E, Finnanger AM. Radiographic classification of glenohumeral arthrosis. *Acta Orthop Scand* 2003;74:186-189.
8. Samilson RL, Prieto V. Dislocation arthropathy of the shoulder. *J Bone Joint Surg Am* 1983;65:456-460.
9. Ogilvie-Harris DJ, Wiley AM. Arthroscopic surgery of the shoulder. A general appraisal. *J Bone Joint Surg Br* 1986;68:201-207.
10. Ellman H, Harris E, Kay SP. Early degenerative joint disease simulating impingement syndrome: Arthroscopic findings. *Arthroscopy* 1992;8:482-487.
11. Weinstein DM, Bucchieri JS, Pollock RG, Flatow EL, Bigliani LU. Arthroscopic debridement of the shoulder for osteoarthritis. *Arthroscopy* 2000;16:471-476.
12. Cameron BD, Galatz LM, Ramsey ML, Williams GR, Iannotti JP. Non-prosthetic management of grade IV osteochondral lesions of the glenohumeral joint. *J Shoulder Elbow Surg* 2002;11:25-32.
13. Kerr BJ, McCarty EC. Outcome of arthroscopic debridement is worse for patients with glenohumeral arthritis of both sides of the joint. *Clin Orthop Relat Res* 2008;466:634-638.