

# The Influence of Bone Loss on Glenoid Version Measurement: A Computer-Modeled Cadaveric Analysis

Justin W. Griffin, M.D., Michael Collins, M.D., Timothy S. Leroux, M.D.,  
Brian J. Cole, M.D., Bernard R. Bach, M.D., Brian Forsythe, M.D., Nikhil N. Verma, M.D.,  
Anthony A. Romeo, M.D., and Adam B. Yanke, M.D.

**Purpose:** To characterize how increasing computed tomography (CT)—quantified glenoid bone loss influences measured version. **Methods:** Six embalmed cadaveric shoulders were used for this study. Glenoid bone defects were computer modeled in cadaveric shoulders; CT images were obtained and segmented using OsiriX software, creating 3-dimensional en face glenoids. Glenoid defects were made on CT images of intact glenoids superimposed with a glenoid clock face viewed en face to simulate anterior and posterior bone loss. Bony defects in various positions comprising 3%, 9.5%, and 19.5% were created posteriorly. Best-fit circles were superimposed to represent 10% and 25% defects anteriorly. Version was measured using the Friedman method. **Results:** The average glenoid version measured 4° of retroversion, 2° after 10% anterior bone loss, and neutral version in the 25% bone loss group. Version was significantly altered when we compared intact glenoids versus 10% and 25% anterior glenoid bone loss ( $P < .001$ ). Increasing from 10% to 25% bone loss showed a significant difference in measured version ( $P = .025$ ). Posterior defects from the 6:30 to 8:30 clock-face position averaged 4.6° of retroversion; from the 6:30 to 9:30 clock-face position, 6.2° of retroversion; and from the 6:30 to 10:30 clock-face position, 8.7° of retroversion. When comparing glenoid defects at the 6:30 to 8:30 clock-face position with those involving the 6:30 to 9:30 and 6:30 to 10:30 clock-face positions ( $P < .001$ ), a 1° correction may be used for every 5% of bone loss to account for version changes seen with bone loss. **Conclusions:** In this cadaveric analysis, glenoid version was altered in the setting of increasing posterior and anterior bone loss. A correction factor may be considered to account for this. When comparing glenoid defects at the 6:30 to 8:30 clock-face position with those involving the 6:30 to 9:30 and 6:30 to 10:30 clock-face positions ( $P < .001$ ), a 1° correction may be used for every 5% of bone loss to account for version changes seen with bone loss. **Clinical Relevance:** This cadaveric study shows that glenoid bone loss alters glenoid version, as measured by CT, in a meaningful way. This information is important in managing anterior and posterior shoulder instability, and correction of measured version should be considered in this setting to provide an accurate and comprehensive evaluation.

From the Jordan-Young Institute for Orthopaedic Surgery & Sports Medicine, Eastern Virginia Medical School (J.W.G.), Virginia Beach, Virginia; Department of Orthopaedic Surgery, Rush University Medical Center (M.C., B.J.C., B.R.B. B.F., N.N.V., A.A.R., A.B.Y.), Chicago, Illinois, U.S.A.; and Department of Orthopaedic Surgery, University of Toronto (T.S.L.), Toronto, Canada.

The authors report the following potential conflict of interest or source of funding: A.A.R. receives support related to board membership from Orthopedics Today, and support from Arthrex related to consultancy, lectures, patents, royalties, and educational presentations. A.B.Y. receives research funding from Arthrex and NuTech Medical. B.F. receives support or has relevant activities related to consultancy from Sonoma and Stryker, grants from Stryker, lectures from ArthroSurface and Sonoma, and stocks from Jace Medical. N.N.V. receives support or has relevant activities related to board membership from American Shoulder and Elbow Surgeons, Arthroscopy Association Learning Center, Journal of Knee Surgery, and SLACK, consultancy from Minivasive, Orthospace, Smith and Nephew, and Arthrex, royalties from Arthroscopy, Smith and Nephew, and Vindico Medical Orthopedics Hyperguide, stocks from Cymedica, Minivasive, and Omeros, and institutional

support from Arthrex, ArthroSurface, DJ Orthopedics, Smith and Nephew, Athletico, ConMed Linvatec, Miomed, and Mitek. J.W.G. receives support from Arthrex related to consultancy, lectures, and educational presentations and serves as a committee member for the American Shoulder and Elbow Surgeons. B.J.C. receives support or has relevant activities related to consultancy from Arthrex, Regentis, and Zimmer, royalties Arthrex and DJ Orthopedics, stocks from Carticept and Regentis, research support from Medipost, Aesculap/B.Braun, Arthrex, and Cytori, and other financial or material support from Smith and Nephew, Tornier, and Ossur. Full ICMJE author disclosure forms are available for this article online, as [supplementary material](#).

Received July 5, 2016; accepted March 5, 2018.

Address correspondence to Justin W. Griffin, M.D., Jordan-Young Institute for Orthopaedic Surgery & Sports Medicine, Eastern Virginia Medical School, 5716 Cleveland St, Ste 200, Virginia Beach, VA 23462, U.S.A. E-mail: [justinwilliamgriffin@gmail.com](mailto:justinwilliamgriffin@gmail.com)

© 2018 by the Arthroscopy Association of North America  
0749-8063/16409/\$36.00

<https://doi.org/10.1016/j.arthro.2018.03.019>

The interplay between glenohumeral instability and glenoid version has been extensively evaluated without consensus. The influence between glenoid version and posterior instability has been well demonstrated in previous studies.<sup>1-8</sup> Several studies have shown mixed reports regarding the relation between anterior shoulder instability and glenoid version.<sup>4</sup> On the other hand, the related importance of glenoid bone loss in anterior and posterior shoulder instability management is well established and has been extensively evaluated.

An increasing body of literature has suggested a strong connection between posterior shoulder instability and glenoid version.<sup>1-7</sup> A recent prospective magnetic resonance imaging (MRI) study showed an association between glenoid retroversion and posterior instability.<sup>7</sup> This has led some surgeons to consider opening-wedge osteotomies for posterior instability with altered glenoid version.<sup>9</sup> Adding to this evidence, a recent study using computed tomography (CT) reported a relation between glenoid retroversion and posterior instability.<sup>6</sup>

Glenoid bone loss remains a critical component of shoulder instability management.<sup>10-13</sup> Careful calculation of the amount of glenoid bone loss has been described and remains a mainstay for surgical decision making in shoulder instability.<sup>14,15</sup> The effect of glenoid bone loss on glenoid version is less well defined and may hold important implications in shoulder instability management.

The purpose of this study was to characterize how increasing CT-quantified glenoid bone loss influences measured version. We hypothesized that increased glenoid bone loss anteriorly or posteriorly would cause alterations in glenoid version measurement.

## Methods

The inclusion criteria were inspected unmatched cadaveric shoulders (3 right and 3 left) with preservation of bony anatomy and cartilage. The exclusion criteria were set as cadavers with arthritis, cancer, or evidence of prior shoulder surgery. The scapulae were dissected free of all soft tissue. After the specimens were prepared, they underwent CT scans in the axial, coronal, and sagittal planes by use of 0.625-mm slices with a 20-cm field of view and 512 × 512 matrices (Volume Zoom; Siemens, Malvern, PA). The digital images of the glenoid faces were uploaded into a personal computer, and a best-fit circle of the inferior two-thirds of the glenoid was determined by use of commercial software (Adobe Photoshop CS [Adobe, San Jose, CA] and Universal Desktop Ruler [AVPSOFT, Moscow, Russia]). The area of the best-fit circle was calculated in square millimeters after it was digitally calibrated with the sizing marker. CT images were imported in DICOM (Digital Imaging and Communications in Medicine) format and

segmented using OsiriX imaging software (Pixmeo) to create 3-dimensional en face glenoid models.

Glenoid osteotomy templates were created at 45° in relation to the longitudinal axis of the glenoid to make a simulated digital anterior-inferior glenoid bone defect of the area of the best-fit circle of the inferior glenoid by use of the computer software. Anterior glenoid defects were made using a best-fit circle superimposed onto the glenoid face to calculate 10% and 25% defects based on glenoid area. The defects were created between the 3- and 6-o'clock positions on the glenoid face. Digital defect lines were drawn in a direct superior-inferior direction (Fig 1).

Posterior glenoid digital defects were made on the intact 3-dimensional en face glenoid models (Fig 1). Posterior defects were drawn using a superimposed clock face, starting at the 6:30 clock-face position and extending posteriorly and superiorly to the 10:30 clock-face position. Defects were made from the 6:30 to 8:30, 6:30 to 9:30, and 6:30 to 10:30 clock-face positions. These positions correspond to 3%, 9.5%, and 19.5% defects, respectively, based on circle area. These positions were chosen based on a previous clinical study, showing the pattern of posterior glenoid wear starting at the 6-o'clock position and extending posteriorly and superiorly to the 10:30 clock-face position while halting progression anteriorly and superiorly at the 6:30 clock-face position. After creation of the digital defects, version measurements were made using the Friedman method<sup>2</sup> (Fig 2) for the intact glenoids, as well as subsequent measurements for each defect size. As a result of these posterior findings, a 1° correction can be made roughly for every 5% of bone loss.

Statistical analysis was performed with repeated-measures analysis of variance (ANOVA) to compare version measurements between multiple groups (intact specimens and subsequent defect sizes) for anterior and posterior defects. For comparisons of 2 groups, paired *t*

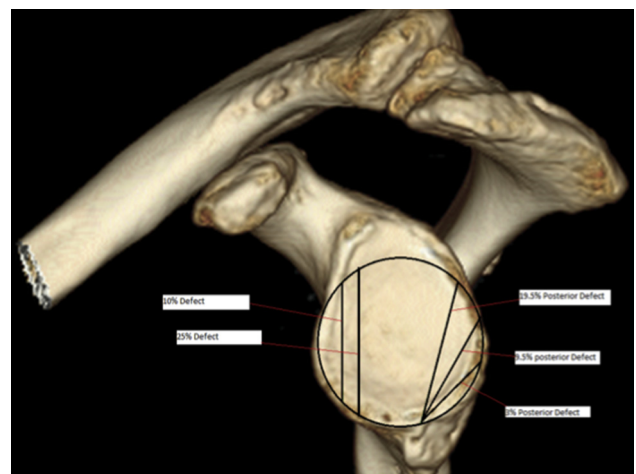
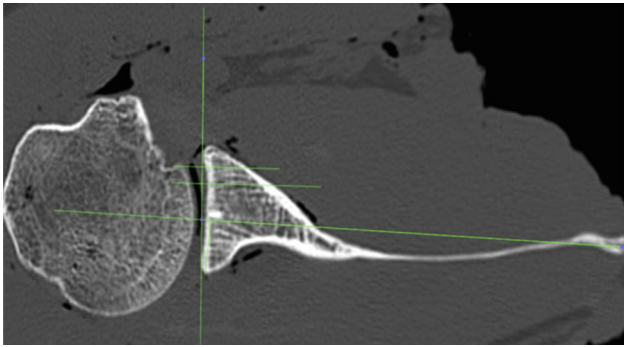


Fig 1. Computer-created defect in native intact left glenoid.



**Fig 2.** Axial computed tomography view showing measurement of glenoid version by Friedman method in native right glenoid.

tests were used. All statistical analysis was conducted with significance set at  $P < .05$ .

## Results

The results of the glenoid version measurements for intact specimens and anterior defects are shown in [Table 1](#). Average glenoid version for intact specimens showed  $4.3^\circ \pm 2.9^\circ$  of retroversion. After creation of 10% digital defects, average version was  $2.6^\circ \pm 2.7^\circ$ , and after creation of 25% defects, the average version measurement was  $0.8^\circ \pm 2.0^\circ$ . Glenoid version was significantly altered when we compared intact shoulders with shoulders with 10% ( $P < .001$ ) and 25% ( $P < .001$ ) anterior glenoid bone loss by CT quantification. Repeated-measures ANOVA showed no significant difference among intact specimens, 10% digital defects, and 25% digital defects ( $P = .095$ ).

Version analysis for posterior glenoid bone loss is summarized in [Table 2](#). The average version measurement after creation of defects from 6:30 to 8:30 (3%) on the glenoid clock face was  $4.6^\circ \pm 2.9^\circ$  of retroversion; defects from 6:30 to 9:30 (9.5%),  $6.2^\circ \pm 2.8^\circ$ ; and defects from 6:30 to 10:30 (19.5%),  $8.7^\circ \pm 2.8^\circ$ . No significant difference in version was found between the intact glenoid and the 3% posterior defects ( $P = .58$ ). Significant differences were found between intact specimens and defects from the 6:30 to 9:30 clock-face position ( $P = .0285$ ) and 6:30 to 10:30 clock-face position ( $P = .0019$ ). ANOVA showed no significant difference among intact specimens and 3%, 9.5%, and 19.5% digital defects ( $P = .056$ ).

## Discussion

The principal findings of this study show that glenoid bone loss in a computer-generated model alters glenoid version measurement; specifically, glenoid defects at the 6:30 to 8:30 clock-face position are different than those at the 6:30 to 9:30 and 6:30 to 10:30 clock-face positions. In glenoids with posterior bone loss, version appears to be altered based on the position and extent of glenoid bone loss. Several previous studies have shown the importance of considering glenoid version in shoulder instability.<sup>4,5</sup> The importance of glenoid bone loss quantification in making treatment decisions for patients with shoulder instability is well established.<sup>10,16</sup> This cadaveric computer model study evaluated the relation between glenoid bone loss and measurement of glenoid version to evaluate its implications in shoulder instability.

The average glenoid retroversion for intact specimens correlated well with previous anatomic studies.<sup>17</sup> Using the technique for measurement of glenoid version described by Friedman et al.,<sup>18</sup> this study showed that glenoid version may be altered in the presence of bone loss in a computer-generated model. After creation of the anterior bone loss states, the average version was  $2.6^\circ \pm 2.7^\circ$  after 10% bone loss and  $0.8^\circ \pm 2.0^\circ$  after creation of 25% defects. When compared with intact specimens, glenoid version was significantly altered when 10% and 25% anterior glenoid bone loss existed by CT quantification.

The relation between anterior shoulder instability and excessive anteversion has been less clear than its posterior counterpart.<sup>19</sup> Cyprien et al.<sup>20</sup> performed a radiographic study and found no association between version and recurrent anterior instability. More recently, Privitera et al.<sup>8</sup> evaluated the relation between glenoid version and glenohumeral instability anteriorly and posteriorly. They analyzed 3 groups of patients: 33 patients with anterior instability, 34 with posterior instability, and 30 without bone loss on MRI. They found no relation between anterior instability and glenoid version in terms of its predictive value. No studies to date have evaluated the combined effect of glenoid bone loss and glenoid version anteriorly. The decreased degree of anteversion measured in the presence of bone loss in our study may play an important role in this regard, although the overall change appears small.

Early work showed the relation between recurrent posterior shoulder instability and glenoid version, and

**Table 1.** Version Analysis of Anterior Glenoid Bone Loss

	Intact	10% Bone Loss	25% Bone Loss	Repeated-Measures ANOVA
Average version, mean $\pm$ SD, $^\circ$	4.29 $\pm$ 2.9	2.55 $\pm$ 2.7	0.80 $\pm$ 2.0	$P < .001$
Paired <i>t</i> test vs intact		$P = .0006$	$P = .0057$	

NOTE. Significance was set at  $P < .05$ .

ANOVA, analysis of variance; SD, standard deviation.

**Table 2.** Version Analysis of Posterior Glenoid Bone Loss

	Intact	6:30-8:30 Clock-Face Position (3%)	6:30-9:30 Clock-Face Position (9.5%)	6:30-10:30 Clock-Face Position (19.5%)	Repeated-Measures ANOVA
Average version, mean $\pm$ SD, $^{\circ}$	4.29 $\pm$ 2.9	4.60 $\pm$ 2.9	6.24 $\pm$ 2.8	8.58 $\pm$ 2.8	$P < .001$
Paired $t$ test vs intact	—	$P = .58$	$P = .0285$	$P = .0019$	

NOTE. Significance was set at  $P < .05$ .

ANOVA, analysis of variance; SD, standard deviation.

such instability has historically been treated with glenoidplasty.<sup>9</sup> In a recent analysis of patients with posterior instability and labral tears, Privitera et al.<sup>8</sup> evaluated glenoid version using MRI. They reported the posterior instability group had  $5^{\circ}$  more retroversion than controls by use of the Friedman measurement method. Presumably, no patients in their study had significant bone loss. Their study showed that glenoid retroversion with reference to the scapular axis was greater in both shoulders with posterior instability and shoulders with posterior labral tears but did not vary with anterior pathology. The average retroversion increased with increasing posterior glenoid defects. Hurley et al.<sup>2</sup> evaluated 25 patients who underwent nonoperative treatment and 25 in whom nonoperative measures failed and who underwent surgery and noted that the posterior instability group had significantly more retroversion than the control group. In a recent prospective study, Owens et al.<sup>6</sup> showed that glenoid retroversion was related to posterior instability in young cadets. This study calls into question whether the increased measured retroversion as a result of posterior bone loss has any effect on posterior instability.

With regard to posterior instability, previous studies have shown that symptomatic posterior defects are often in the posteroinferior quadrant.<sup>21</sup> For this reason, defects were computer modeled and calculated estimates were arrived at from 6:30 to 8:30 (3%), 6:30 to 9:30 (9.5%), and 6:30 to 10:30 (19.5%) on the glenoid clock face. No significant difference in version was found between the intact glenoid and the 3% posterior defects, but there was a change in version. Significant differences were found between intact specimens and defects from the 6:30 to 9:30 and 6:30 to 10:30 clock-face positions. When posterior bone loss exists, a correction factor of  $1^{\circ}$  for every 5% of bone loss could be considered based on these findings. Although other factors must be considered, this study shows that in the setting of glenoid bone loss posteriorly, apparent retroversion may appear increased.

Future directions should evaluate how this may apply in the setting of retroversion in shoulder arthroplasty. In addition, further clinical studies will be required to determine how the various bone loss situations described alter clinical outcomes as they relate to version. Future studies should evaluate the influence of combined

measured glenoid version alteration and glenoid bone loss on outcomes in glenohumeral instability.

### Limitations

The major limitation of this study is that it is inherently an anatomic study without clinical follow-up. Additional limitations include that this study was performed with digital rendering, which may not mimic true intraoperative bone loss situations. Using purely computer-generated images of glenoid cuts based on cadaveric specimens has not been previously validated and thus is a limitation of the study. Despite these limitations, this study shows that glenoid bone loss alters glenoid version measurement, and if noted, correction for this can be performed.

### Conclusions

In this cadaveric analysis, glenoid version was altered in the setting of increasing posterior and anterior bone loss. A correction factor may be considered to account for this. When comparing glenoid defects at the 6:30 to 8:30 clock-face position with those involving the 6:30 to 9:30 and 6:30 to 10:30 clock-face positions ( $P < .001$ ), a  $1^{\circ}$  correction may be used for every 5% of bone loss to account for version changes seen with bone loss.

### References

1. Wirth MA, Seltzer DG, Rockwood CA Jr. Recurrent posterior glenohumeral dislocation associated with increased retroversion of the glenoid. A case report. *Clin Orthop Relat Res* 1994;(308):98-101.
2. Hurley JA, Anderson TE, Dear W, Andrish JT, Bergfeld JA, Weiker GG. Posterior shoulder instability. Surgical versus conservative results with evaluation of glenoid version. *Am J Sports Med* 1992;20:396-400.
3. Inui H, Sugamoto K, Miyamoto T, et al. Glenoid shape in atraumatic posterior instability of the shoulder. *Clin Orthop Relat Res* 2002;(403):87-92.
4. Hohmann E, Tetsworth K. Glenoid version and inclination are risk factors for anterior shoulder dislocation. *J Shoulder Elbow Surg* 2015;24:1268-1273.
5. Mauro CS, McClincy MP, Bradley JP. Effect of glenoid version and width on outcomes of arthroscopic posterior shoulder stabilization. *Am J Sports Med* 2016;44:941-947.
6. Owens BD, Campbell SE, Cameron KL. Risk factors for posterior shoulder instability in young athletes. *Am J Sports Med* 2013;41:2645-2649.

7. Owens BD, Campbell SE, Cameron KL. Risk factors for anterior glenohumeral instability. *Am J Sports Med* 2014;42:2591-2596.
8. Privitera DM, Siegel EJ, Miller LR, Sinz NJ, Higgins LD. Glenoid version and its relationship to glenohumeral instability and labral tears. *J Shoulder Elbow Surg* 2016;25:1056-1063.
9. Johnston GH, Hawkins RJ, Haddad R, Fowler PJ. A complication of posterior glenoid osteotomy for recurrent posterior shoulder instability. *Clin Orthop Relat Res* 1984;(187):147-149.
10. Provencher MT, Bhatia S, Ghodadra NS, et al. Recurrent shoulder instability: Current concepts for evaluation and management of glenoid bone loss. *J Bone Joint Surg Am* 2010;92:133-151 (suppl 2).
11. Bakshi NK, Patel I, Jacobson JA, Debski RE, Sekiya JK. Comparison of 3-dimensional computed tomography-based measurement of glenoid bone loss with arthroscopic defect size estimation in patients with anterior shoulder instability. *Arthroscopy* 2015;31:1880-1885.
12. Bryce CD, Davison AC, Lewis GS, Wang L, Flemming DJ, Armstrong AD. Two-dimensional glenoid version measurements vary with coronal and sagittal scapular rotation. *J Bone Joint Surg Am* 2010;92:692-699.
13. Bryce CD, Davison AC, Okita N, Lewis GS, Sharkey NA, Armstrong AD. A biomechanical study of posterior glenoid bone loss and humeral head translation. *J Shoulder Elbow Surg* 2010;19:994-1002.
14. Owens BD, Burns TC, Campbell SE, Svoboda SJ, Cameron KL. Simple method of glenoid bone loss calculation using ipsilateral magnetic resonance imaging. *Am J Sports Med* 2013;41:622-624.
15. Rerko MA, Pan X, Donaldson C, Jones GL, Bishop JY. Comparison of various imaging techniques to quantify glenoid bone loss in shoulder instability. *J Shoulder Elbow Surg* 2013;22:528-534.
16. Bois AJ, Fening SD, Polster J, Jones MH, Miniaci A. Quantifying glenoid bone loss in anterior shoulder instability: Reliability and accuracy of 2-dimensional and 3-dimensional computed tomography measurement techniques. *Am J Sports Med* 2012;40:2569-2577.
17. Churchill RS, Brems JJ, Kotschi H. Glenoid size, inclination, and version: An anatomic study. *J Shoulder Elbow Surg* 2001;10:327-332.
18. Friedman RJ, Hawthorne KB, Genez BM. The use of computerized tomography in the measurement of glenoid version. *J Bone Joint Surg Am* 1992;74:1032-1037.
19. Moroder P, Ernstbrunner L, Pomwenger W, et al. Anterior shoulder instability is associated with an underlying deficiency of the bony glenoid concavity. *Arthroscopy* 2015;31:1223-1231.
20. Cyprien JM, Vasey HM, Burdet A, Bonvin JC, Kritsikis N, Vuagnat P. Humeral retrotorsion and glenohumeral relationship in the normal shoulder and in recurrent anterior dislocation (scapulometry). *Clin Orthop Relat Res* 1983;(175):8-17.
21. Gottschalk MB, Ghasem A, Todd D, Daruwalla J, Xerogeanes J, Karas S. Posterior shoulder instability: Does glenoid retroversion predict recurrence and contralateral instability? *Arthroscopy* 2015;31:488-493.