

Arthroscopic Shoulder Stabilization With Suture Anchors: Technique, Technology, and Pitfalls

Brian J. Cole, MD, MBA; and Anthony A. Romeo, MD

Arthroscopic treatment of anterior shoulder instability has evolved significantly during the past decade. Currently, most techniques include the use of suture and suture anchors. A successful outcome is highly dependent on accurate patient selection. Preoperative evaluation, examination with the patient under anesthesia, and defining the pathoanatomy by a thorough arthroscopic examination determine the most effective treatment strategy. Technical skills include the surgeon's ability to accomplish anchor placement, suture passage, and arthroscopic knot tying. Various instruments and techniques are available to facilitate arthroscopic reconstruction. In properly selected patients and with good surgical technique, outcomes should approximate or exceed traditional open stabilization techniques.

Arthroscopic reconstruction has become an accepted method of treatment for anterior shoulder instability. Despite early reports indicating greater failure rates compared with traditional open stabilization techniques, arthroscopic methods have evolved through improved understanding of disorders associated with instability, more careful patient selection, and im-

proved technology.^{3,8,11,15,17-20,24,29} Obvious contraindications to arthroscopic capsulolabral repair of instability are bony insufficiency of the glenoid from acute fracture or chronic erosion, large Hill-Sachs lesion, capsular rupture within its midsubstance or at its insertion, and the presence of poor quality capsular tissue. If these patients are not included with patients with recurrent anterior shoulder instability, the outcome of arthroscopic repair is equivalent with the outcome of open repair.

The major advantages of arthroscopic repair versus open repair of instability are the possibility to identify and treat concomitant disease, lower morbidity and reduced pain, shorter surgical time, and improved cosmesis. Furthermore, some surgeons think that patients have an easier functional recovery, and ultimately better motion than with an open repair method.⁸

Associated Pathoanatomy

Below the equator of the glenoid, the labrum is normally tightly approximated to the glenoid articular rim, and any separation in this area is termed a Bankart lesion (Fig 1). The Bankart lesion is present in approximately 90% of all traumatic anterior shoulder dislocations.²⁵ Above the glenoid equator the labral anatomy may be variable, and loose attachment below the biceps tendon may be a normal variant (a sublabral foramen).^{10,12}

From *Rush University, Division of Sports Medicine, Section of Shoulder Surgery, Rush-Presbyterian-St Luke's Medical Center, Chicago, IL.

Reprint requests to Brian J. Cole, MD, MBA, 1725 West Harrison, Suite 1063, Chicago, IL 60614.

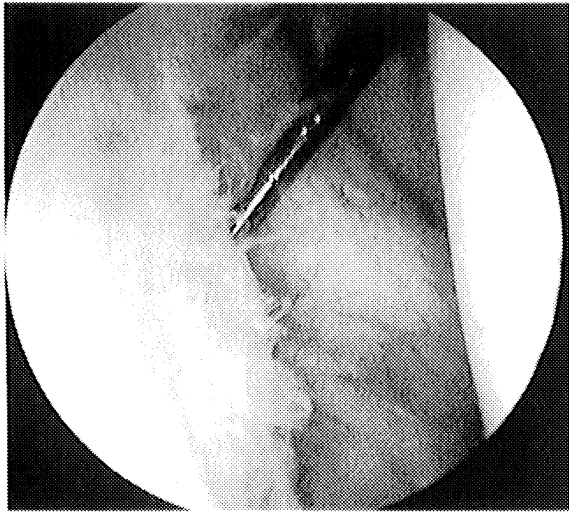


Fig 1. The classic Bankart lesion is an avulsion of the anteroinferior capsular labral complex from the glenoid rim as seen here from 2 o'clock to 6 o'clock in this right shoulder. (Reprinted with permission from Romeo A, Cohen B, Carreira: Traumatic anterior shoulder instability. *Oper Tech Sports Med* 8:188–196, 2000.)

Complete lesions of the superior labrum associated with destabilization of the biceps insertion may occur with shoulder instability. True superior labral injury is associated with failure of the origin fibers of the labrum, cartilage injury at the margin of the labral attachment, and extension of a tear into the biceps tendon.

In addition to the Bankart lesion, recurrent dislocations also can cause stretching of the glenohumeral capsule and ligaments. This plastic deformation occurs from repetitive loading.^{5,35} Although identification of this stretch injury or laxity of the ligaments may be difficult, failure to address this component of the instability when doing an arthroscopic repair contributes to failure of the procedure.

Actual macroscopic failure of the capsule at the humeral insertion is not common, but seems to constitute a relative contraindication to arthroscopic repair. In such cases, direct repair with capsule reinsertion seems to be more reliable through an open approach at this time, although arthroscopic techniques to treat this problem have been presented.^{36,37}

Insufficiency of the region of the capsule known as the rotator interval has received attention recently because some failures of arthroscopic techniques have been attributed to this disorder.^{9,14,16,22} This interval lies within the anterior and superior capsular region between the anterior border of the supraspinatus and the superior (cephalic) border of the subscapularis tendon. The major ligamentous components of the rotator interval are the superior and middle glenohumeral ligaments, and the extraarticular coracohumeral ligament.^{9,22} If a patient has a large inferior drawer (sulcus sign) when the arm is in adduction and external rotation, the rotator interval region of the capsule likely will be insufficient. This may represent either an injury, or a relative dysplasia of the ligaments of this region. In such cases, overlapping the capsule, either through an arthroscopic technique or an open technique, should repair this area.^{14,16}

Rotator cuff injury in younger patients usually is appreciated as a partial-thickness articular-sided tear of the supraspinatus. This probably represents a failure through eccentric loading of the tendon as a secondary injury attributable to the recurrent instability. Full-thickness tears of the rotator cuff in association with acute shoulder instability usually are seen in patients older than 40 years, and should be suspected when a patient continues to have weakness and pain more than 3 weeks after an anterior dislocation.²⁸ In such patients, preoperative physical examination and imaging studies will discern the configuration of the tear that usually can be addressed arthroscopically at the time of stabilization surgery.^{6,32}

Suture Anchor Rationale

The benchmark to which the success of arthroscopic repair must be compared is a failure rate after open stabilization of generally less than 10%.^{1,33} The difficulty in making comparisons between series are that various definitions of failure are used, but most commonly, failure is described as recurrent dislocation of the glenohumeral joint. Further-

more, reports of open repair show additional failures attributable to the inability of patients to return to participating in high level sports after surgical repair.^{1,34} Although there are no prospective randomized studies comparing arthroscopic and open repair, recent prospective reports of arthroscopic stabilization techniques have reported failure rates as low as the best open repair series, and also a high return to participation in sports.^{3,4,11,15,18,29,36} The authors prefer repair techniques that use suture anchors with or without arthroscopically-tied knots. It is thought that suture anchors successfully overcome the known limitations of metallic staples, transglenoid sutures, and single point fixation devices. This method first was described by Wolf³⁶ in 1993 when he reported using a metal anchor and tying knots with absorbable sutures. Suture anchor repair techniques allow for knots to be tied in the joint arthroscopically, avoiding the need for a posterior incision. Furthermore, recent technology has allowed for suture repair using anchors without knots, minimizing the need for arthroscopic knot tying. However, the ability to tie secure knots arthroscopically remains an essential skill for arthroscopic stabilization procedures.

Patient Selection

History

The history obtained from the patient is of great diagnostic value. For example, if the patient describes a sudden severe trauma sustained with the arm positioned in abduction and external rotation, and resulting in a dislocation, it is extremely likely that an avulsion of the anteroinferior glenoid labrum (Bankart lesion) has occurred. If, however, the patient reports minimal trauma causing a dislocation, such as reaching overhead, then capsular laxity is likely to be the major disorder. Recurrent multiple traumatic dislocations are likely to be associated with anterior glenoid rim erosion, a large Hill-Sachs lesion, and increased capsular laxity.

Some patients may complain only of pain with the arm in a position of apprehension (ab-

duction and external rotation), without a sense of instability. They still may have a capsulolabral injury.

Patient age and activity level are critical to predicting the risk for recurrence without surgical intervention. Those patients younger than 20 years or who participate in high-risk activities are at the highest risk for recurrence (approaching 90%–95%). Continued participation in collision sports or activities that require overhead use of the affected arm leads to recurrent episodes of instability in all age groups.^{2,3,34}

Physical Examination

Careful motor and sensory evaluation is directed at axillary nerve function. Weakness may indicate a rotator cuff tear in patients older than 40 years. Provocative testing for instability may be done when a documented dislocation has not occurred and a question about the direction of instability remains. Anterior and posterior apprehension tests are sensitive. The relocation maneuver will increase the sensitivity and specificity of the diagnosis of anterior instability, whether or not a complete dislocation has occurred.

Assessment of laxity of the joint may be difficult in an office setting because of muscle guarding when the patient is experiencing pain. Nevertheless, inferior laxity should be assessed. Although the degree of a normal sulcus sign is variable, a painful sulcus sign suggests inferior instability.

The presence of pain deep in the shoulder with provocative biceps testing or a grind or click during glenohumeral rotation and compression may suggest the presence of a superior labral injury (SLAP lesion).

Radiographic Evaluation

Plain radiographic evaluation is useful as an initial screening tool to identify significant glenoid or humeral bone loss. In general, at least two orthogonal views are essential, although the authors prefer three orthogonal views, including an anteroposterior (AP) view, a scapular Y view, and an axillary lateral view. Several special imaging techniques increase accuracy for

detecting bony Bankart and Hill-Sachs lesions. These include a West Point axillary view, an AP view with the shoulder in internal rotation, and a Stryker-Notch view.^{21,31}

Although magnetic resonance imaging (MRI) may not be required, it is useful for clarification of capsuloligamentous and bony injury. Gadolinium enhancement improves the sensitivity of MRI. If significant bony loss of the glenoid or humeral head is suspected, a computed tomography (CT) scan may provide additional quantitative information. Any glenoid rim deficiency of 25% or greater is likely to require formal reconstruction and in the authors' opinion, is a contradiction for arthroscopic stabilization.

Examination Under Anesthesia

Most often, the examination under anesthesia supports the diagnosis established through the patient's history and physical examination. Stability testing in the anterior, posterior, and inferior direction in different positions of abduction will help identify regions of labral or capsular disease. For example, increased inferior translation with the arm adducted in external rotation may indicate the need to address capsular laxity and the rotator interval.

Diagnostic Arthroscopy

A systematic evaluation of the glenohumeral joint will show concomitant disorders including anterior labral detachment, capsular injury, articular cartilage damage (glenoid and or a Hill-Sachs lesion), superior labral injury, and rotator cuff tears in decreasing order of frequency. Observing these structures in different positions of arm rotation while probing and grasping may help determine the quality and integrity of the anterior capsuloligamentous structures. When the shoulder is placed in a position of abduction and external rotation, the inferior glenohumeral ligament should be observed to tighten while the humeral head remains centered in the glenoid. An anterior force can be applied to the humerus causing the humeral head to move anteriorly on the glenoid. Although the humeral head may be

observed to move to the anterior edge of the glenoid when the arm is in adduction, there should be no appreciable anterior translation when the shoulder is in abduction and external rotation because of tightening of the anterior band of the inferior glenohumeral ligament complex. This is the arthroscopic drawer test.

The ability to easily pass the arthroscope from posterior to anterior and then into the axillary pouch is called the drive-through sign. The drive-through sign is present with capsular laxity.³⁰ The sign is sensitive for showing capsular laxity, but nonspecific when relating its presence to various pathologic shoulder conditions.

Surgical Indications

There is of particular interest in treating young athletes with an initial anterior glenohumeral dislocation with early arthroscopic stabilization. Advantages include the ability to clearly define the pathoanatomy of the traumatic event and the increased biologic potential for healing of the injured structures. Furthermore, there usually is good quality tissue and minimal collateral tissue damage in patients who otherwise have a high likelihood of recurrence without surgical treatment. The indication for early arthroscopic stabilization must be considered on a case by case basis. Typically, if the athlete is at risk for missing more than one season because of instability of the shoulder, early arthroscopic stabilization is recommended.

Patients with recurrent anterior instability despite attempts at physical therapy or a willingness to modify their activities, or patients who experience instability at rest or during their sleep, also are appropriate candidates for surgical intervention. Although athletes who participate in collision sports after arthroscopic stabilization conceptually may be at high risk for recurrent instability after surgical treatment, attention to the entire spectrum of pathoanatomy identified at surgery is likely to lead to a satisfactory result. Whether these patients are treated entirely by arthroscopic techniques depends on the technical ability to repair the labrum and the capacity to sufficiently

address associated capsular laxity and the rotator interval.

Surgical Reconstruction-Suture Anchors

General Principles

The surgical approach involves a combination of secure reattachment of the anteroinferior labrum and reestablishing the proper tension within the inferior glenohumeral ligament complex. Capsular laxity is addressed by superior shift of the capsule, with or without the labrum, depending on the disorder. If the capsulolabral suture repair does not seem to address all of the capsular laxity, some surgeons prefer to use radiofrequency probes to supplement the repair with thermal capsulorrhaphy. If there seems to be insufficiency of the rotator interval region with persistent inferior laxity, then this region also is plicated with sutures. Thermal treatment to shrink or reduce the rotator interval frequently is ineffective. Finally, associated superior labral injuries also are repaired at the time of the surgical procedure. In the rare cases with midcapsular rupture or avulsion of the humeral insertion, conversion to open reconstruction may be required.

Instrumentation

Various commercial instrumentation are available for arthroscopic stabilization procedures. Appropriately sized disposable cannulas are necessary to accommodate the instrumentation required for glenoid preparation, suture passage through soft tissue, and arthroscopic knot tying. Typically, 6-mm and 8-mm cannulas are used. Most commercially available cortical anchors have pull-out strengths that exceed the ultimate failure strength of the suture, knot and soft tissue interface. The limiting factor is the suture placement through the tissue, the quality of the tissue to be repaired, and the security of the arthroscopic knot. Once the anchor has been placed, several different types of devices allow the suture to be retrieved and placed through the capsule and ligaments. Some of these devices pierce the ligaments and labrum and then retrieve the suture, whereas others permit a suture loop to be placed through the tissue so that the

suture through the anchor can be shuttled back through the tissue and retrieved.

Surgeon preference for retrieving the suture in the joint or shuttling the suture determines which device is used for this step of the procedure. It often is helpful to have more than one method to pass the suture through the tissue that is to be repaired. Various knot pushers have been designed. Although some allow the individual suture limbs to be pushed away from each other, thus tensioning the knot, others simply are straight pushers that allow a sliding knot or a half-hitch knot to be slid down a post. A single hole knot pusher is relatively simple to use and has great use for tying all types of arthroscopic knots.

Anesthesia and Positioning

Interscalene regional anesthesia, general anesthesia, or a combination of both may be used to decrease narcotic requirements and to aid in early postoperative pain relief. The authors' preference in positioning is the beach chair position with interscalene regional anesthesia for anterior instability procedures. The beach chair position facilitates efficient set-up and conversion to an open approach is easier with the patient in this position compared with the lateral decubitus position. Alternatively, the lateral decubitus position with appropriately applied traction on the arm may be helpful when the repair requires extensive suture plication.

Examination under anesthesia with side-to-side comparisons is done to document range of motion and the degree and direction of humeral head translation. Typically, translation anteriorly over the glenoid rim with (2+) or without (3+) spontaneous reduction is considered abnormal. However, 2+ posterior translation usually is considered normal and must be taken in the context of other clinical factors including comparison with the posterior laxity of the opposite shoulder. The sulcus between the inferolateral border of the acromion and the greater tuberosity is measured in centimeters with an inferior displacement force in different positions of rotation to evaluate capsular laxity and the rotator interval.

Even if translation does not seem to be increased significantly, the patient still may have a Bankart lesion. Therefore, correlation with history and preoperative examination is important.

Arthroscopy

The shoulder is prepared and draped in a sterile manner and the bony landmarks are marked carefully to maintain orientation throughout the procedure. The subcutaneous tissue at the portal sites are infiltrated with 0.25% bupivacaine with epinephrine. A standard posterior portal is established within the soft spot located approximately 2 cm medial to the lateral acromion and 2 cm inferior to the scapular spine. Two anterior portals (superior and inferior) are established using an outside-in technique with a spinal needle to confirm appropriate orientation. These portals function as utility portals for instrument passage, glenoid preparation, suture management, and knot tying. It is important to widely separate these anterior can-

nulas so that access in the joint is facilitated. (Fig 2) Therefore, a 6-mm cannula first is placed in a vertical orientation so that it enters the joint just underneath the biceps tendon. The second cannula is 8 mm in diameter and is placed as low as possible, either just above the superior edge of the subscapularis, or through the subscapularis at approximately 1 to 2 cm below its superior edge. The anteroinferior cannula usually is placed 1 cm inferior and lateral to the palpable coracoid process, which corresponds to 2 to 3 cm below the anterosuperior cannula. This placement allows the first anchor to be placed at the 5 o'clock position on the glenoid (for a right shoulder).

A complete diagnostic arthroscopy is done with the arthroscope placed in the anterosuperior and standard posterior portals. Attention is dedicated to the rotator interval, superior labrum, rotator cuff, articular cartilage and to reciprocal tightening of the glenohumeral ligaments especially with the arm abducted and externally rotated. The labrum is evaluated

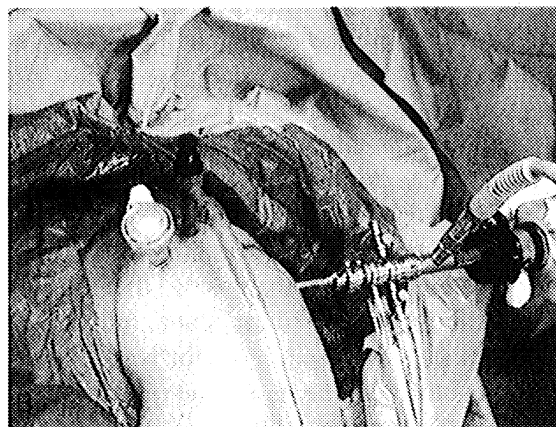
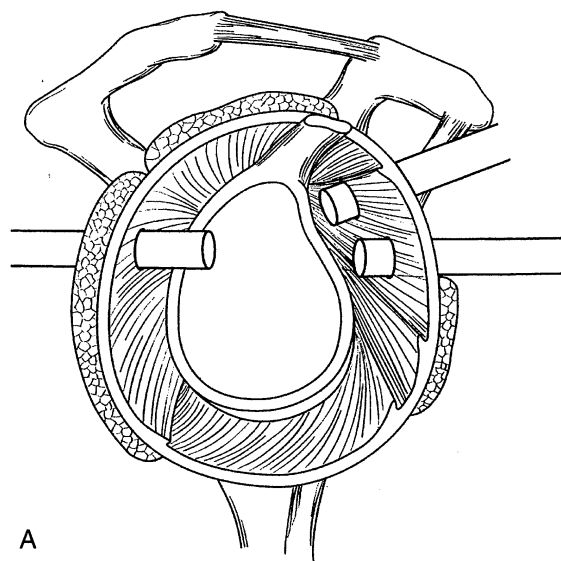


Fig 2A–B. (A) Schematic of portal placement showing the relationship of the two anterior portals relative to the subscapularis and biceps tendons. (Reprinted with permission from Cohen B, Cole B, Romeo A: Thermal capsulorrhaphy of the shoulder. *Oper Tech Orthop* 11:38–45, 2001). (B) Intraoperative photograph showing portal placement. Two anterior portals are established. An anterosuperior 6-mm gray cannula and an anteroinferior 8-mm clear purple cannula allow for easy passage of instrumentation and suture management. The anteroinferior cannula enters just proximal to the subscapularis tendon or just below the superior edge of the subscapularis tendon. An outside-in technique is used with an 18 gauge spinal needle to determine optimal placement.

circumferentially for signs of frank detachment or medial healing along the scapular neck. Detachment of the labrum with healing medially on the scapula may be difficult to recognize, but usually appears as a bare glenoid rim with capsular attachment occurring medially and is appreciated best from the anterosuperior portal. This condition must be recognized because the anatomic repair requires that the entire capsulolabral sleeve be mobilized and replaced back to its anatomic insertion at the margin of the glenoid rim.

Glenoid Preparation and Anchor Placement

The 30° arthroscope can be placed in the posterior viewing portal and in the anterosuperior portal whereas working instruments are placed in the anteroinferior portal. The capsulolabral complex is mobilized off the glenoid neck medial to the articular edge approximately 1 to 1.5 cm and inferiorly to the 6 o'clock position (right shoulder) using a periosteal elevator or knife rasp. Electrocautery

or a radiofrequency device also may be useful. It is important to mobilize the capsulolabral sleeve so that it can be shifted superiorly and laterally onto the glenoid rim. This often requires the capsulolabral sleeve to be released from the scapula until the muscle fibers of the subscapularis can be seen. Although a motorized hooded burr may be used to decorticate the anterior and inferior glenoid neck, a motorized shaver may be sufficient (Fig 3).

Anchors are placed on the articular rim through the anteroinferior cannula at an angle of approximately 45° to the frontal plane to avoid articular penetration and to minimize the risk of inadvertent medial placement along the scapular neck. Anchor placement is from inferior to superior with the first anchor placed at approximately the 5 o'clock position. Suture passage and knot tying is done before each subsequent anchor insertion. Anchor placement may be facilitated by a toothed or serrated guide that maintains the juxtaarticular anchor position and by predrilling if necessary. The advantage

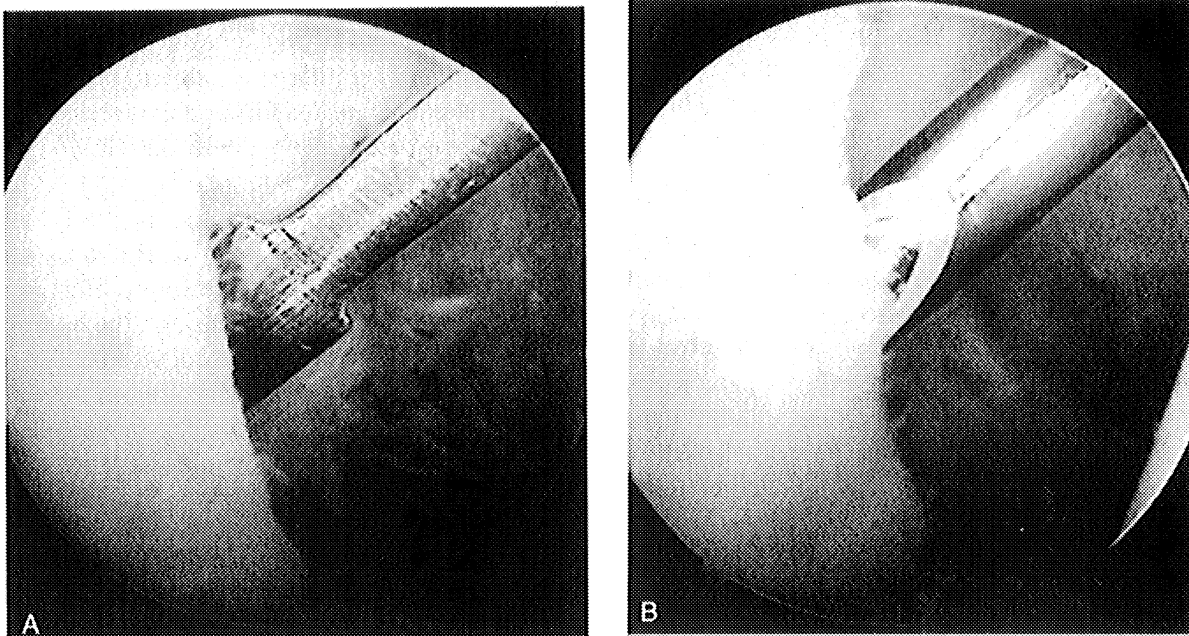


Fig 3A–B. (A) Intraarticular view showing a knife rasp used to mobilize the periosteal sleeve. (B) The rotary shaver or burr is used to decorticate the anterior and inferior glenoid neck to achieve a bleeding bed to optimize healing. The entire capsulolabral sleeve must be mobilized off the glenoid neck to allow for anatomic repair to the glenoid rim.

of a metal screw-in anchor is that it can be removed and revised. Furthermore, most of these anchors are self-taping and do not require predrilling, which eliminates a step required for push-in anchors and bioabsorbable anchors. Whichever type of anchor is selected, the authors have found that plastic or absorbable anchors usually allow easier knot tying with a sliding knot. Braided sutures slide more easily through a plastic or absorbable polymer anchor eyelet or a suture eyelet than through a metal eyelet because of reduced friction.

More recently, an anchor technology that allows for suture repair without knots has been developed (Mitek Products, Johnson & Johnson Company, Westwood, MA). This kind of design permits the suture to be captured in the end of the anchor once the suture has been passed through the tissue. It then is placed into a predrilled hole and impacted to a depth that pulls the capsulolabral tissue securely against the glenoid rim. With this device, all of the steps of knot tying are avoided.

After anchor placement, assessment of anchor security, suture slippage, and knot security is done. Most surgeons use Number 1 or Number 2 braided, nonabsorbable material or prolonged absorbable, braided suture because of its strength and handling properties. This allows for secure knots that do not slip.

Anterior Glenohumeral Reconstruction

The first anchor is critical in establishing proper capsular tension. After mobilization of the capsulolabral periosteal sleeve, the first anchor is placed at the articular margin at least as low as the 5 o'clock position. One limb of the suture from this anchor is retrieved through the superior cannula because it will be transported through the capsule with a device placed through the inferior cannula. Separating the two sutures is an important step in suture management and will help the surgeon avoid unloading the suture from the anchor. A crochet hook or suture retriever can be used routinely for managing the sutures (Fig 4A). It is important to transport the suture that comes out of the anchor on its inferior or medial surface to avoid the suture twist-

ing on itself next to the anchor eyelet. Avoiding a twist in the suture at the level of the anchor eyelet will permit the suture to slide and therefore allow for easier knot tying. A hook device or punch device (the authors prefer the Spectrum or Blitz device [Linvatec, Largo, FL]) is placed through the capsulolabral complex medial and inferior to the lowest anchor so that the entire inferior glenohumeral ligament is shifted superiorly and laterally onto the glenoid rim. Tension can be assessed by using a soft-tissue grasper placed through the superior portal while pulling on the suture-passing instrument. Because the labrum is included in this suture loop, it will be repaired when the capsule is shifted and secured with the arthroscopic knot. In general, the suture retrieval device is placed through the inferior glenohumeral ligament approximately 1 cm inferior and medial to the anchor (Fig 4B–C). Typically, some instruments allow for a suture retrieval device to penetrate through the capsule labral tissue and then extend a wire loop or suture grasper.

If a suture shuttle device or punch device (Caspari Punch, Linvatec) is used, then a shuttle relay (Linvatec) is placed through the device and retrieved out of the superior cannula. Alternatively a monofilament suture (0 or number 1 in size) can be placed through the suture shuttle device either as a loop, or as one strand (Fig 5). If it is retrieved as a loop, it is used to shuttle the suture limb from the anchor back through the capsule labral tissue. If it is passed as one limb, it is tied onto the suture limb then the suture limb is shuttled through the capsule labral tissue. The shuttle relay device is used in a similar manner. The suture is directed through the wire loop or to the suture grasper and then retrieved through the capsule labral tissue. When transferring the suture, it is important to observe the suture sliding out of the superior cannula and not through the anchor to avoid inadvertently unloading the suture from the anchor. Placing a hemostat on the suture limb remaining within the anteroinferior cannula and visualizing the suture limb during transfer is an effective way to manage the suture transfer and prevent unloading the suture from the anchor.

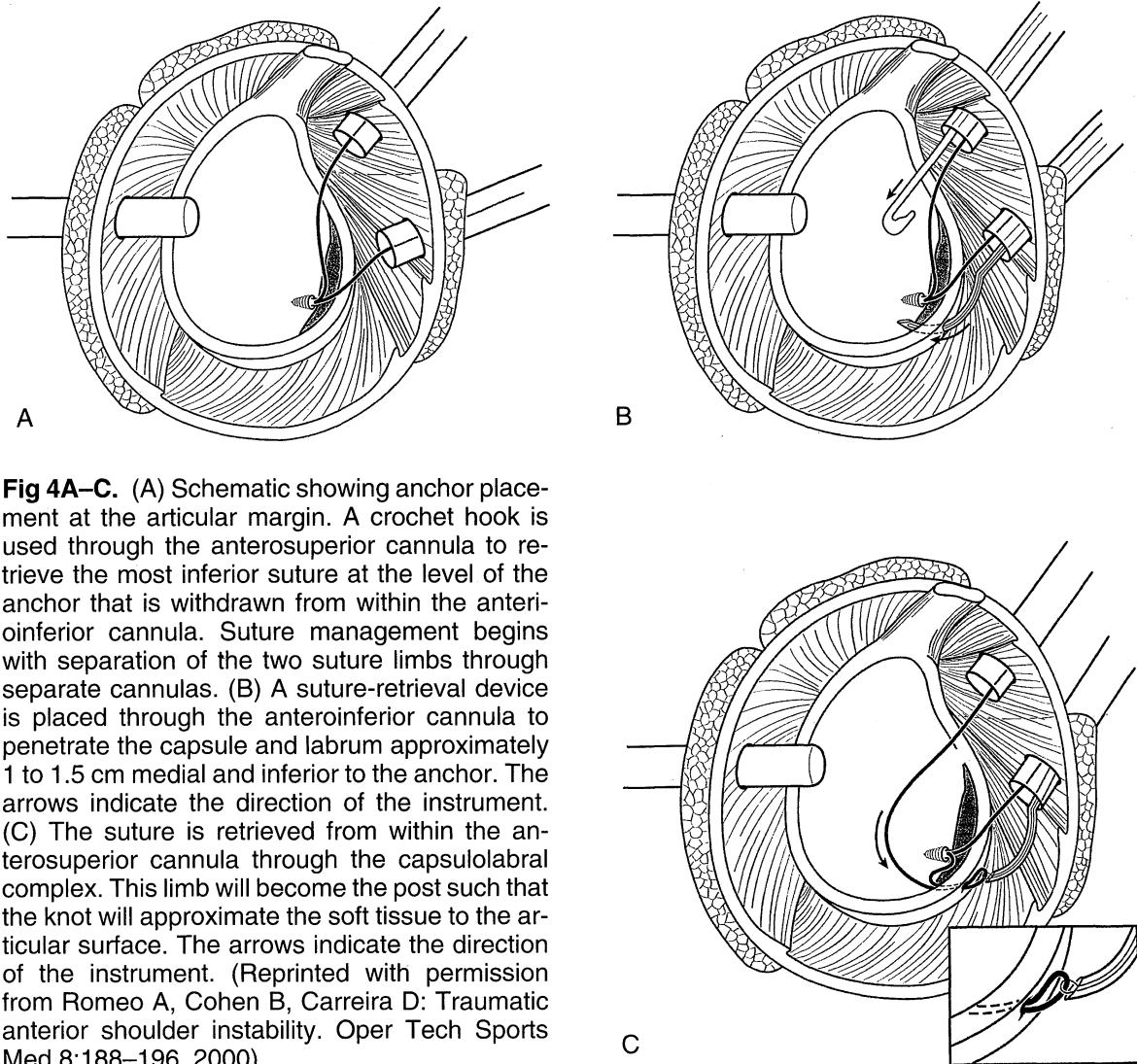


Fig 4A–C. (A) Schematic showing anchor placement at the articular margin. A crochet hook is used through the anterosuperior cannula to retrieve the most inferior suture at the level of the anchor that is withdrawn from within the anteroinferior cannula. Suture management begins with separation of the two suture limbs through separate cannulas. (B) A suture-retrieval device is placed through the anteroinferior cannula to penetrate the capsule and labrum approximately 1 to 1.5 cm medial and inferior to the anchor. The arrows indicate the direction of the instrument. (C) The suture is retrieved from within the anterosuperior cannula through the capsulolabral complex. This limb will become the post such that the knot will approximate the soft tissue to the articular surface. The arrows indicate the direction of the instrument. (Reprinted with permission from Romeo A, Cohen B, Carreira D: Traumatic anterior shoulder instability. *Oper Tech Sports Med* 8:188–196, 2000).

The suture limb that exits in the anterosuperior cannula is the suture that ultimately will pass through the soft tissue. Ideally, the surgeon will use this suture limb as the post suture, with the other limb used as the loop suture. By selecting the suture that passes through the soft tissue as the post suture, the knot will be tied onto the post suture then passed through the cannula to rest on top of the soft tissue and not on the articular surface.

The steps involved with knot tying begin with placement of the knot pusher on each individual limb and passing it down into the joint

to ensure that any twisting or tangling of the suture limbs is remedied before knot tying. Furthermore, passing the knot pusher on the suture limb will allow confirmation of the post suture limb versus the loop suture limb. It generally is easiest to tie a sliding knot first. The sliding knot can be placed securely onto the tissue tensioning the tissue in the appropriate repair position. The sliding knot may be a knot that does not lock (Duncan Loop, Fig 6) or a self-locking knot (Bunt-line hitch). Placing a knot pusher on the post limb to push the knot down the post while simultaneously pulling the knot

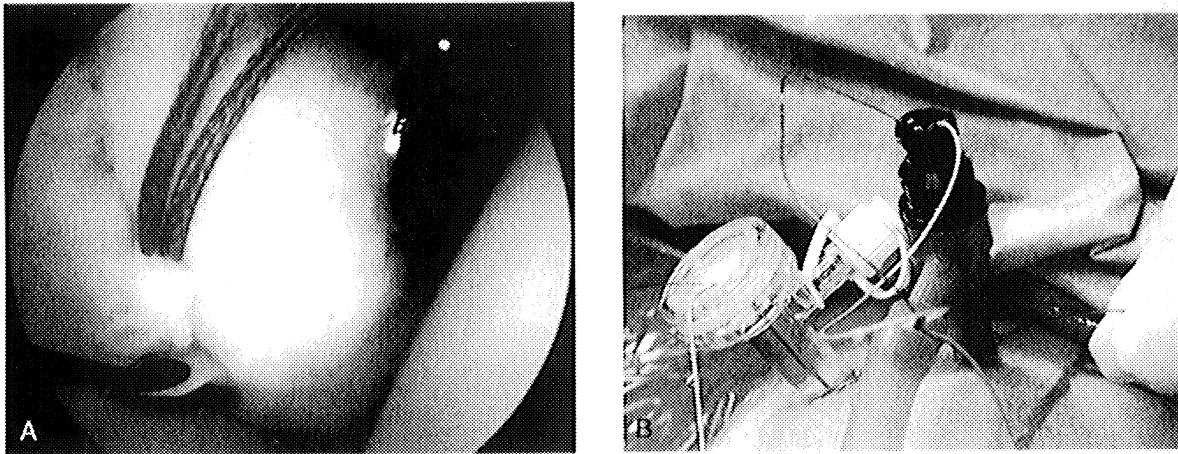


Fig 5A–B. (A) Alternatively, a suture hook (Linvatec) placed through the anteroinferior cannula is used to penetrate the anteroinferior labrum with the suture or shuttle advanced into the joint in preparation for retrieval of the limb from within the anterosuperior cannula. The suture is grasped from the suture hook using a grasper placed within the anterosuperior portal. (B) The suture from within the anterosuperior cannula is pulled through the labrum using a shuttle system or by tying a monofilament suture around the limb and pulling it from within the anterosuperior cannula out the anteroinferior cannula. The superior suture limb is pulled through the soft tissue into the anteroinferior cannula by pulling on the suture that remains within the anteroinferior cannula.

limb minimizes suture trauma and reduces the risk for suture fraying and failure. Subsequently, a minimum of three alternating half-hitch nonsliding loops are advanced down the post guided by the knot pusher. Although the first sliding knot is placed by pulling on the post and pushing on the knot with the knot pusher on the post, the subsequent half-hitch knots are pulled into the joint by placing the knot pusher on the loop suture just past the half-hitch so it pulls on the loop suture bringing the knot down into the joint. The knot is tightened by passing the knot pusher beyond the point of the knot, and applying tension to both suture limbs. This technique of past-pointing allows for knot security equal to knots tied with open techniques. Alternating the posts and the direction of each half-hitch maximizes knot security. The ends are cut leaving a 3-mm tail (Fig 7). These steps are repeated for each subsequent anchor (Fig 8).

The Rotator Interval

If, after repair of the inferior and middle glenohumeral ligament capsulolabral avulsion, the

shoulder still shows persistent inferior or inferoposterior translation, some surgeons will close the rotator interval.^{14,16} A curved Spectrum (Linvatec) suture hook is placed through the anterosuperior cannula or placed percutaneously through the portal without the cannula and advanced through the healthy tissue immediately adjacent to the supraspinatus tendon. The suture hook is advanced inferiorly through the tissue adjacent to the subscapularis tendon and a Number 1 monofilament is advanced through these two tissue regions.

At times, it is difficult to grasp sufficient tissue with one pass of the suture hook. An alternative method involves percutaneous placement of an inferiorly placed suture grasper (Penetrator, Arthrex, Naples, FL) to retrieve the suture after advancing the Spectrum suture hook through the superior tissue only. In either case, the suture ends are retrieved through the anterior portal after removing the cannula and secured using an arthroscopic sliding knot extraarticularly over the soft tissue anteriorly. Alternatively, the sutures are retrieved from within the subacromial space by viewing from

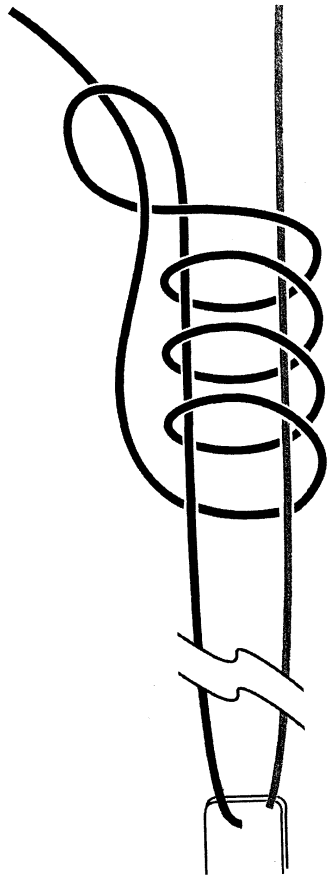


Fig 6. A sliding knot (Duncan loop) is formed around the suture post. (Reprinted with permission from Romeo A, Cohen B, Carreira: Traumatic anterior shoulder instability. Oper Tech Sports Med 8:188–196, 2000).

within the space posteriorly and retrieving from a standard anterior portal and securing with an arthroscopic knot. Additional sutures are added as needed. Care is taken to position the arm in external rotation and adduction during suture placement and tensioning.

Thermal Capsulorrhaphy

If, after the repair of the capsulolabral repair there seems to be persistent translation and capsular laxity, additional laxity can be reduced using the technique of thermal capsulorrhaphy^{7,23,26} (Fig 9). Although acceptance of this technique is increasing, peer reviewed literature advocating its routine use is limited. Thermal modification of collagen in capsular

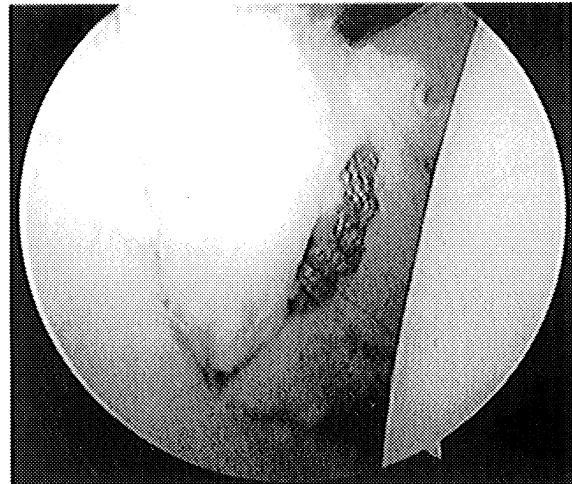


Fig 7. The final repair shows secure fixation with the capsulolabral complex attached on the glenoid rim.

tissue has been shown experimentally and in initial clinical experience, to reduce capsular laxity.⁷ The application of heat in a range of 65° to 75° C causes disruption of heat-sensitive intramolecular bonds in collagen leading to a transition from an extended helical crys-

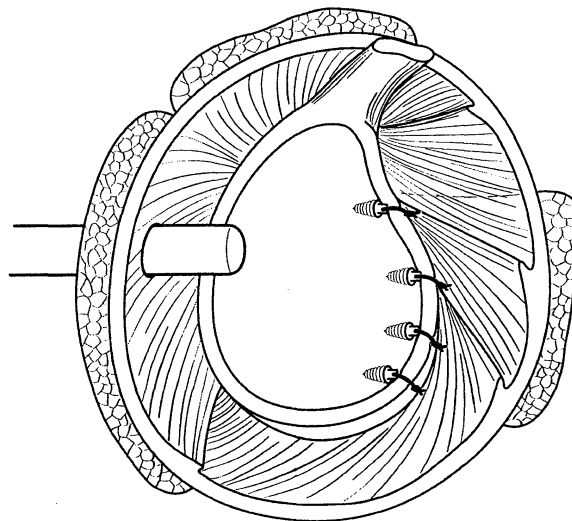


Fig 8. Completed Bankart requires a minimum of two to three anchors placed sequentially from inferior to superior. (Reprinted with permission from Romeo A, Cohen B, Carreira D: Traumatic anterior shoulder instability. Oper Tech Sports Med 8:188–196, 2000).

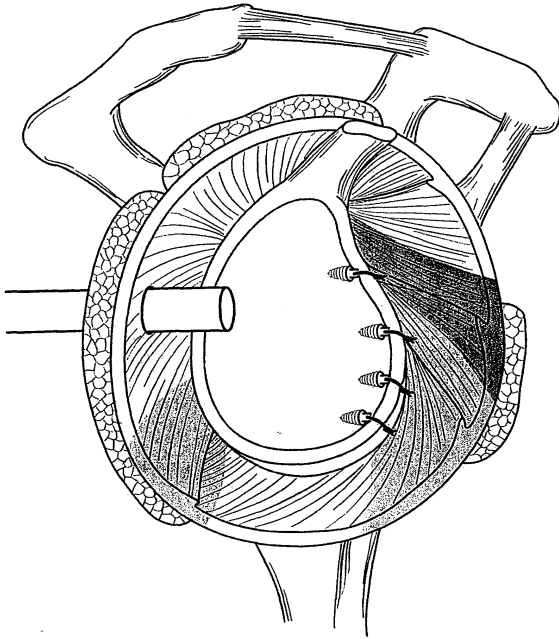


Fig 9. A monopolar radiofrequency device (Oratec Interventions, Menlo Park, CA) may be used to additionally reduce capsular volume after an arthroscopic Bankart repair. A grid technique is used to treat the capsule. Care is taken to avoid thermal treatment near the suture line to avoid weakening the surgical repair. Treatment of the capsule (gray shaded area) within the regions of the middle, inferior, and posterior glenohumeral ligaments may be required depending on the degree of capsular laxity. Thermal treatment of the axillary pouch is avoided entirely. (Reprinted with permission from Cohen B, Cole B, Romeo A: Thermal capsulorrhaphy of the shoulder. *Oper Tech Orthop* 11:38–45, 2001).

tallinelike state to a shortened random configuration. This results in shortening of the collagen molecules approximately 20% to 30% of the original length. The healing response includes inflammation with fibroblast infiltration, and then remodeling and restoration of histologic characteristics and biomechanical strength during a 6- to 12-week period. The degree of response, however, seems to vary among individuals.^{7,23,26}

If thermal energy is used, it is applied to a lax capsule after all anchors have been placed and knots have been tied. Shrinking before suture placement increases the level of difficulty

in assessing, approximating, and repairing the soft tissue to the glenoid rim. After suture repair, care is taken to avoid thermally treating near the suture line because of the risk of soft tissue weakening and failure. A monopolar radiofrequency device or a bipolar radiofrequency device can be used. To date, no prospective randomized comparisons of either device have been done. The technique of thermal treatment of the capsule remains empiric, but the authors prefer to treat the capsule in alternating regions creating a grid-like pattern. This maintains normal areas of the capsule that may contribute to healing after thermal injury to the capsule.²⁷

Postoperative Rehabilitation

Postoperative rehabilitation after arthroscopic repair is identical to that after open reconstruction. Sling immobilization generally is required for 4 to 6 weeks depending on the methods used and the instability pattern treated. Active and unrestricted range of motion of the hand, wrist, and elbow begins immediately after surgery. Similarly, deltoid isometrics and gentle pendulum exercises begin immediately. Active forward elevation is restricted to 120° after the first 2 to 3 weeks to minimize the load on the capsulolabral region. At this point, external rotation also may be permitted to 30° to 40° degrees depending on the extent of repair. At 4 to 6 weeks, rotation limits gradually are extended, and at 8 to 10 weeks, progressive resistive exercises begin. The patient is allowed to return to participating in sports between 18 and 36 weeks.

RESULTS

The authors have done this procedure (as outlined above) in more than 225 patients with traumatic, unidirectional, anterior shoulder instability. The first 45 patients have been analyzed thoroughly and have a minimum followup of 2 years. There were no reports of recurrent dislocation, and 96% of patients had good and excellent results. All athletes, including those who participated in contact sports (football, hockey),

were able to return to their sports although some did not compete at a level equal to their preinjury abilities. These results compare favorably with results reported for open anterior stabilization procedures.^{1,8,11,13,17,19}

Arthroscopic stabilization for glenohumeral instability has evolved rapidly during the past 15 to 20 years. The understanding of the pathoanatomy associated with glenohumeral instability and the technologic advances now make it possible to duplicate the results of open stabilization techniques. Multiple techniques are available to restore glenohumeral stability. Capsular tensioning must be evaluated critically at the time of repair. Arthroscopic techniques should provide a convincing intraoperative examination of stability. Judicious use of adjuvant thermal capsulorrhaphy may address residual capsular laxity that otherwise may lead to failure. Similarly, rotator interval closure, when indicated, may improve postoperative results.

Although there are no well-designed randomized prospective studies comparing patients who underwent arthroscopic stabilization with a control group, several recent uncontrolled prospective studies confirm the efficacy of this technique.^{13,17,19,20}

The authors strongly prefer the arthroscopic suture anchor technique because it most closely duplicates the traditional open Bankart repair. Patient selection still is critical to the ultimate success of this procedure as is appropriately addressing all disorders at the time of surgery. Postoperative rehabilitation is not significantly different from that after traditional open techniques. Premature return to activities that stress the reconstruction likely will result in early failure. Surgeons are encouraged to practice these techniques in a forum of continuing education before doing them in the operating room.

References

1. Altchek D, Warren R, Skyhar M, et al: Modification of the Bankart repair for multi-directional instability of the anterior and inferior types. *J Bone Joint Surg* 73A:105-112,1991.
2. Arciero R, St. Pierre P: Acute shoulder dislocation: Indications and techniques for operative management. *Clin Sports Med* 14:937-953, 1995.
3. Bacilla B, Field L, Savoie F: Arthroscopic Bankart repair in a high demand patient population. *Arthroscopy* 13:51-60, 1997.
4. Belzer J, Snyder J: Arthroscopic capsulorrhaphy for traumatic anterior shoulder instability using suture anchors and nonabsorbable suture. *Arthroscopy* 11:359-365, 1995.
5. Bigliani L, Pollock R, Soslowsky U, et al: Tensile properties of the inferior glenohumeral ligament. *J Orthop Res* 10:187-197, 1992.
6. Burkhart S: A stepwise approach to arthroscopic rotator cuff repair based on biomechanical principles. *Arthroscopy* 16:82-90, 2000.
7. Cohen B, Cole B, Romeo A: Thermal capsulorrhaphy of the shoulder. *Operative Tech Orthop* 11:38-45, 2001.
8. Cole B, L'Insalata J, Irrgang J, et al: Comparison of arthroscopic and open anterior shoulder stabilization: A two to six-year follow-up study. *J Bone Joint Surg* 82A:1108-1114, 2000.
9. Cole B, Rodeo S, O'Brien S, et al: The anatomy and histology of the rotator interval capsule of the shoulder. *Clin Orthop* 390:129-137, 2001.
10. Cole B, Warner J: Anatomy, Biomechanics, and Pathophysiology of Glenohumeral instability. In Iannotti J, Williams Jr GR (eds). *Disorders of the Shoulder: Diagnosis and Management*. Philadelphia, Lippincott Williams & Wilkins 207-232, 1999.
11. Cole BJ, Warner JP: Arthroscopic versus open Bankart repair for traumatic anterior shoulder instability. *Clin Sports Med* 1:19-48, 2000.
12. Cooper D, Arnoczky S, O'Brien S, et al: Anatomy, histology and vascularity of the glenoid labrum. *J Bone Joint Surg* 74A:46-52, 1992.
13. Field L, Savoie F, Griffith P: A comparison of open and arthroscopic Bankart repair. *J Shoulder Elbow Surg* 8:195, 1999. Abstract.
14. Field L, Warren R, O'Brien S, et al: Isolated closure of rotator interval defects for shoulder instability. *Am J Sports Med* 23:557-563, 1995.
15. Gartsman G, Roddey T, Hammerman SM: Arthroscopic treatment of anterior-inferior glenohumeral instability: Two to five-year follow-up. *J Bone Joint Surg* 82A:991-1003, 2000.
16. Gartsman G, Taverna E, Hammerman SM: Arthroscopic rotator interval repair in glenohumeral instability: Description of an operative approach. *Arthroscopy* 15:330-332, 1999.
17. Geiger D, Hurley J, Tovey J, et al: Results of arthroscopic versus open Bankart suture repair. *Clin Orthop* 337:111-117, 1997.
18. Grana W, Buckley P, Yates C: Arthroscopic Bankart suture repair. *Am J Sports Med* 21:348-353, 1993.
19. Green M, Christensen K: Arthroscopic versus open Bankart procedures: A comparison of early morbidity and complications. *Arthroscopy* 9:371-374, 1993.
20. Guancho C, Quick D, Sodergren K, et al: Arthroscopic versus open reconstruction of the shoulder with isolated Bankart lesions. *Am J Sports Med* 24:144-148, 1996.
21. Hall R, Isaac F, Booth C: Dislocations of the shoulder with special reference to accompanying small fractures. *J Bone Joint Surg* 41A:489-494, 1959.
22. Harryman D, Sidles J, Harris S, et al: The role of the rotator interval capsule in passive motion and stabil-

- ity of the shoulder. *J Bone Joint Surg* 74A:53–66, 1992.
23. Hayashi K, Thabit GI, Massa K, et al: The effect of thermal heating on the length and histologic properties of the glenohumeral joint capsule. *Am J Sports Med* 25:107–112, 1997.
 24. Higgins L, Warner J: Arthroscopic Bankart repair: Operative technique and surgical pitfalls. *Clin Sports Med* 19:49–62, 2000.
 25. Hinterman B, Gachter A: Arthroscopic findings after shoulder dislocation. *Am J Sports Med* 23:545–551, 1995.
 26. Lopez M, Hayashi K, Fanton G, et al: The effect of radiofrequency energy on the ultrastructure of joint capsular collagen. *Arthroscopy* 14:495–501, 1998.
 27. Lu Y, Hayashi K, Edwards R, et al: The effect of monopolar radio-frequency treatment pattern on joint capsular healing: In vitro and in vivo studies using an ovine model. *Am J Sports Med* 28:711–719, 2000.
 28. Neviasser R, Neviasser T, Neviasser J: Concurrent rupture of the rotator cuff and anterior dislocation of the shoulder in the older patient. *J Bone Joint Surg* 70A:1308–1311, 1988.
 29. O'Neill D: Arthroscopic Bankart repair of anterior detachments of the glenoid labrum. *J Bone Joint Surg* 81A:1357–1366, 1999.
 30. Pagnani M, Warren R: Arthroscopic shoulder stabilization. *Op Tech Sports Med* 1:276–284, 1993.
 31. Rokous J, Feagin J, Abbott H: Modified axillary roentgenogram: A useful adjunct in the diagnosis of recurrent instability of the shoulder. *Clin Orthop* 82:84–86, 1972.
 32. Romeo A, Cohen B, Cole B: Arthroscopic repair of full-thickness rotator cuff tears: Surgical technique and instrumentation. *Orthop Spec Ed* 7:1–6, 2001.
 33. Rowe C, Patel D, Southmayd W: The Bankart procedure: A long-term end-result study. *J Bone Joint Surg* 60A:1–16, 1978.
 34. Rowe C, Zarins B, Ciullo J: Recurrent anterior dislocation of the shoulder after surgical repair: Apparent causes of failure and treatment. *J Bone Joint Surg* 66A:159–168, 1984.
 35. Ticker J, Bigliani L, Soslowsky L, et al: Inferior glenohumeral ligament: Geometric and strain-rate dependent properties. *J Shoulder Elbow Surg* 5:269–279, 1996.
 36. Wolf E: Arthroscopic capsulolabral repair using suture anchors. *Orthop Clin North Am* 24:59–69, 1993.
 37. Wolf E, Cheng J, Dickerson K: Humeral avulsion of glenohumeral ligaments as a cause of anterior shoulder instability. *Arthroscopy* 11:600–607, 1995.