

# Biceps Tenodesis Is a Viable Option for Management of Proximal Biceps Injuries in Patients Less Than 25 Years of Age



Justin W. Griffin, M.D., Gregory L. Cvetanovich, M.D., Jae Kim, M.S., Timothy S. Leroux, M.D., Jonathan Riboh, M.D., Bernard R. Bach, M.D., Brian J. Cole, M.D., Gregory P. Nicholson, M.D., Nikhil N. Verma, M.D., and Anthony A. Romeo, M.D.

**Purpose:** To evaluate outcomes after biceps tenodesis performed in patients younger than 25 years, to evaluate reoperations and complications in this population, and to critically appraise return to preinjury level of play for this population. **Methods:** Forty-five consecutive patients younger than 25 years underwent subpectoral biceps tenodesis for biceps tendinopathy or biceps-labral complex injuries including SLAP tears. Biceps tenodesis was performed using an interference screw technique. Patients with a minimum 2-year follow-up were analyzed. Functional outcomes were assessed with the visual analog scale score, American Shoulder and Elbow Surgeons (ASES) score, ASES functional score, Simple Shoulder Test score, and range of motion. Activity level and return to sport were followed postoperatively. **Results:** Of the 45 patients younger than 25 years who underwent biceps tenodesis, 36 (80%) were available for follow-up at a minimum of 2 years, with a mean age of 19.8 years and mean follow-up period of 38.6 months. Of these 36 patients, 34 (94%) were athletes, with 20 patients playing at collegiate level. All clinical outcome scores improved, with the ASES score improving from 54.7 to 81.7, the ASES functional score improving from 17.5 to 25.1, and the Simple Shoulder Test score improving from 7.4 to 10.1 ( $P < .001$ ). At the time of follow-up, 4 patients (11%) had undergone revision surgery for other injuries. Of the 34 athletes, 25 (73%) returned to sports, with 19 returning at the same level and 6 returning at a lower level of play; 77% of overhead athletes returned to sports. **Conclusions:** When indicated, biceps tenodesis offers an alternative to SLAP repair in young patients. Biceps tenodesis in patients younger than 25 years yields satisfactory outcomes, with two-thirds of patients returning to sport and a low revision rate. **Level of Evidence:** Level IV, therapeutic case series.

See commentary on page 1042

The biceps-labral complex has long been recognized as a shoulder pain generator in young athletes.<sup>1-4</sup> Overhead throwing is a common causative

factor associated with SLAP tears and other biceps pathology.<sup>5-11</sup> Although controversial, operative treatment in young patients has historically consisted of

From the Department of Orthopaedic Surgery, Rush University Medical Center (J.W.G., J.K., T.S.L., J.R., B.R.B., B.J.C., G.P.N., N.N.V., A.A.R.), Chicago, Illinois; and Department of Orthopaedics, The Ohio State University Wexner Medical Center (G.L.C.), Columbus, Ohio, U.S.A.

The authors report the following potential conflicts of interest or sources of funding: J.W.G. receives support for travel to meetings from and is a paid speaker and consultant for Arthrex. T.S.L. receives support for travel to fellowship meetings. J.R. has consulted for Stryker Sports Medicine and Cytex Therapeutics, and has a sponsored research agreement with Sparta Biopharma. B.J.C. has consulted for Arthrex, Regentis, and Zimmer over the past 36 months; received IP royalties from Arthrex and DJ Orthopaedics; and owns stock in Carticept and Regentis. He has previously received research support from Medipost, Aesculap/B.Braun, Arthrex, Cytos, and the National Institutes of Health (NIAMS and NICHD), as well as other financial or material support from Smith and Nephew, Tornier, and Össur. G.P.N. receives support from Tornier and ArthroSurface. N.N.V. receives support from American

Shoulder and Elbow Surgeons, Arthroscopy Association Learning Center, Journal of Knee Surgery, SLACK, Minivasive, Orthospace, Smith & Nephew, Arthrex, Arthroscopy, Vindico Medical Orthopedics Hyperguide, Cymedica, Omeros, ArthroSurface, DJ Orthopaedics, Athletico, ConMed Linvatec, Miomed, and Mitek. A.A.R. receives support from Orthopedics Today and Arthrex. Full ICMJE author disclosure forms are available for this article online, as [supplementary material](#).

Received March 10, 2018; accepted October 31, 2018.

Address correspondence to Justin W. Griffin, M.D., Eastern Virginia Medical School, Jordan-Young Institute for Orthopaedic Surgery & Sports Medicine, 5716 Cleveland St, Ste 200, Virginia Beach, VA 23462, U.S.A. E-mail: [justinwilliamgriffin@gmail.com](mailto:justinwilliamgriffin@gmail.com)

© 2019 by the Arthroscopy Association of North America  
0749-8063/18323/\$36.00

<https://doi.org/10.1016/j.arthro.2018.10.151>

repair of the labrum and biceps anchor. Although excellent clinical outcomes with SLAP repair have been reported in some series, others have reported disappointing results, with 40% to 60% of patients dissatisfied and experiencing persistent shoulder pain.<sup>2,12-21</sup> An inconsistent ability to return to throwing has also been a major concern with SLAP repair in overhead athletes.

A recent systematic review of SLAP repair showed a return-to-play rate of 64% among all athletes, with overhead athletes experiencing even less optimal restoration of preinjury function.<sup>22</sup> On the basis of these relatively poor results, several authors have suggested primary biceps tenodesis (BT) may provide superior results to those of SLAP repair. Concerns over altered throwing or glenohumeral kinematics have been cited as reasons to avoid BT in young patients, but little is known about outcomes in this population.<sup>11,15,23</sup> A recent prospective series showed a higher return-to-play rate in patients treated with BT compared with SLAP repair.<sup>12</sup> In this same series, patients who underwent revision from SLAP repair to BT returned to their preinjury level of play. The mean age in this study, however, was much higher than the typical young overhead athlete, with an average age of 37 years.

Tenosynovitis of the long head of the biceps tendon can also cause chronic anterior shoulder pain owing to overuse.<sup>24</sup> This can occur along with impingement syndrome in young athletes, leading to decreased performance.<sup>25</sup> To date, outcomes of BT in young patients remain controversial. Several recent studies have evaluated outcomes in patients younger than 45 years.<sup>26,27</sup> The purposes of this study were to evaluate outcomes after BT performed in patients younger than 25 years, to evaluate reoperations and complications in this population, and to critically appraise return to preinjury level of play for this population. We hypothesized that BT would provide satisfactory outcomes in young patients.

## Methods

### Patient Selection

After institutional review board approval was obtained, patients undergoing BT by 4 fellowship-trained shoulder surgeons (G.P.N., N.N.V., B.R.B., A.A.R.) were reviewed. Diagnosis was performed with magnetic resonance imaging in all cases, coupled with physical examination of patients. Failure of nonsurgical management with persistent symptoms consistent with the diagnosis established the criteria for surgery with an inability to return to activities. The inclusion criteria were patients younger than 25 years and patients undergoing BT. The exclusion criteria included additional shoulder procedures outside of a BT alone including rotator cuff repair; a significant preoperative range-of-motion deficit, which was not the case in any

patients; and significant contralateral shoulder disease or surgery. A total of 45 patients met the inclusion and exclusion criteria.

The medical records of all patients meeting the inclusion and exclusion criteria were retrospectively reviewed. Demographic data including age, sex, body mass index, smoking status, and sport-specific activity were collected. Factors specific to the patients' shoulder complaints were also recorded. All documentation from follow-up visits was reviewed.

Nonoperative treatment included physical therapy in all cases and, when indicated, an attempted return-to-throwing program. The length of nonoperative treatment was variable, depending on the patient's sport and season timing. Imaging included magnetic resonance imaging evidence of biceps tendon inflammation on a non-arthrogram study, as well as evidence of proximal biceps synovitis, hypertrophy, and instability at the time of surgery. All patients had bicipital groove pain at the time of the clinical examination in the office. All patients underwent a mini-open subpectoral BT with tendon fixation with a tenodesis screw. No patient who underwent tenodesis had normal arthroscopic examination findings.

### Outcome Assessment

Functional outcomes were assessed with the visual analog scale score, American Shoulder and Elbow Surgeons (ASES) score, ASES functional score, and Simple Shoulder Test (SST) score. The study clinical examination included assessment of shoulder range of motion of the shoulder that underwent surgery. Reoperations and complications were recorded. Return to sport was evaluated, including the ability to return to the same level versus a lower level of competition.

### Statistical Analysis

Patients with a minimum 2-year follow-up postoperatively were analyzed for outcomes of BT. Demographic variables were analyzed with descriptive statistics. This included the mean  $\pm$  standard deviation for continuous variables and frequencies with percentages for categorical data. Data were tested and found to be normal in distribution; therefore, parametric tests were used. Paired *t* tests were used to compare preoperative and postoperative outcome scores. The  $\chi$ -square or Fisher exact test was used for categorical data as appropriate based on expected values. Bivariate regression was performed to determine associations between continuous variables. *P* = .05 was used for statistical significance.

## Results

### Demographic Characteristics

Between February 2011 and February 2013, 45 consecutive patients underwent BT for a diagnosis of

**Table 1.** Patient Demographic Characteristics

	Data
No. of patients	36
Sex	13 M and 23 F
Age, yr	19.7 ± 2.7
Body mass index	25.9 ± 5.4
Follow-up, mo	39.0 ± 9.6
Right arm	28 (78%)
Dominant arm underwent surgery	30 (83%)
Revision procedure	16 (44%)
Athlete	34 (94%)
Indication of biceps tendinitis	26 (72%)
Indication of SLAP tear	10 (28%)

NOTE. Data are presented as mean ± standard deviation or number of patients.

F, female; M, male.

biceps tendinopathy or biceps-labral complex injuries including SLAP tears and were analyzed with 2-year follow-up. Of these 45 patients, 36 (80%) were available for a minimum 2-year follow-up (mean, 39.0 ± 9.6 months postoperatively). Patient demographic characteristics are shown in Table 1. Most patients underwent surgery on the dominant arm (30 of 36, 83%). BT was performed as the primary procedure in 20 patients (56%) and as a revision procedure in 16 (44%) for failed SLAP repair. The indication for surgery was biceps tendinitis in 26 patients (72%) versus a SLAP tear in 10 patients (28%). In patients in whom biceps tendinitis was diagnosed, this was established through imaging, clinical examination findings, and subsequent arthroscopy.

Six patients underwent both fixation of a SLAP tear and BT. Aside from concomitant SLAP repair that was performed in 6 patients without a subset analysis performed, no additional procedures were performed with BT. A mixture of knotless and knotted repairs were performed among the previous SLAP repairs analyzed. No significant difference in demographic characteristics was found between primary and revision procedures. A trend toward a SLAP tear being a more common indication for BT surgery was noted in primary cases as opposed to revision cases (8 of 20 patients [40%] vs 2 of 16 patients [12%],  $P = .071$ ). No evidence of subscapularis tendon tears or subcoracoid impingement was found at the time of surgery.

Of the 36 included patients, 34 (94%) were athletes at least at the recreational level. Most patients played at the collegiate level (20 of 34, 59%) (Fig 1), with baseball and softball being the most common sports (Fig 2). Overhead sports (baseball, softball, and volleyball) were the primary sports for 23 patients (68%).

### Return to Sport After BT

Of the 34 athletes, 25 were able to return to sport (73%). Among these patients, 17 of 22 overhead athletes (77%) returned to the same level of competition,

with 6 returning at a lower level of play. The rates of return to sport did not vary based on overhead athletes versus non-overhead athletes ( $P = .660$ ). Overhead athletes and non-overhead athletes did not differ in the ability to return to the same level of competition (59% vs 44%,  $P = .693$ ). Overhead athletes and non-overhead athletes showed no difference in the percentage of patients undergoing surgery on the dominant arm (91% vs 73%,  $P = .300$ ). We also found no difference in return to sport between primary and revision cases (83% vs 62%,  $P = .229$ ).

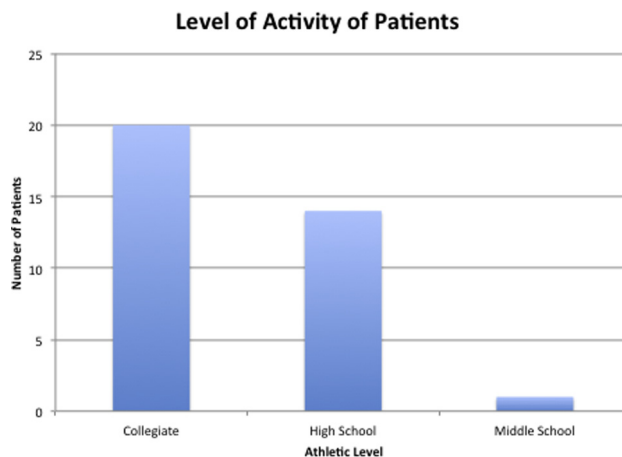
### Patient-Reported Outcomes

At a minimum 2-year follow-up, the visual analog scale score improved from 5.0 ± 1.2 to 2.0 ± 1.1 (mean difference, 27 ± 3.0; 95% confidence interval [CI], -3.8 to -2.2;  $P < .001$ ). All clinical outcome scores improved, with the ASES score improving from 54.7 ± 18.1 to 81.7 ± 19.7 (mean difference, 27.4; 95% CI, 20.1-34.7;  $P < .001$ ), the ASES functional score improving from 17.5 ± 6.2 to 25.1 ± 6.9 (mean difference, 7.7; 95% CI, 5.2-10.2;  $P < .001$ ), and the SST score improving from 7.4 ± 2.7 to 10.1 ± 3.1 (mean difference, 2.7; 95% CI, 1.7-3.7;  $P < .001$ ) (Table 2).

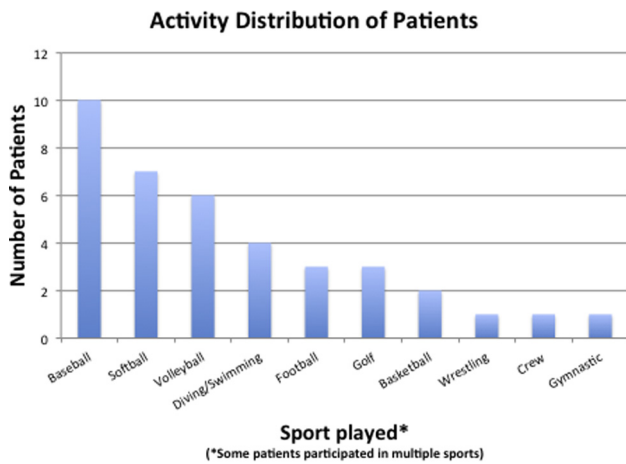
We found no differences in outcomes between primary and revision patients and no differences between overhead and non-overhead athletes. Patients with a higher body mass index had lower improvements in the SST score ( $P = .036$ ) and a trend toward lower ASES functional score improvements ( $P = .089$ ).

### Subsequent Surgery After BT

By final follow-up, 5 patients (14%) underwent 1 subsequent surgical procedure after BT. These 5 subsequent procedures were a revision BT, an arthroscopic Bankart repair (2 patients), a Latarjet procedure, and a rotator cuff repair. All of these patients had an additional injury requiring subsequent surgery unrelated to the prior tenodesis. This included the revision tenodesis procedure. Patients who underwent subsequent



**Fig 1.** Level of activity of patients.



**Fig 2.** Activity distribution of patients.

surgery after BT were less likely to return to sports (25% vs 81%,  $P = .043$ ). All patients undergoing subsequent surgery after BT were overhead athletes, although this was not statistically significant ( $P = .280$ ).

## Discussion

In young patients, BT can yield satisfactory outcomes, with two-thirds of patients returning to sport and a low revision rate. In this study, 94% of patients were athletes, differing from previously reported patients undergoing BT. In a previous series, Frank et al.<sup>28</sup> showed that the risk of revision surgery had a significant association with age younger than 20 years and throwing activity. Provencher et al.<sup>29</sup> reported age older than 36 years and smoking as factors associated with higher revision rates among patients undergoing SLAP repair.<sup>30</sup> Sayde et al.<sup>30</sup> reported a 63% return-to-play rate for overhead athletes in their series after SLAP repair. This is similar to our study in which we found an overall return-to-sport rate of 68%, with 74% of patients returning to the same level of competition. It is interesting to note that revision to a BT did not alter the rate of return to play compared with undergoing a BT as the primary surgical procedure.

Recently, Pogorzelski et al.<sup>27</sup> evaluated patients younger than 45 years undergoing subpectoral tenodesis, some of whom were involved in sports. Although this population was not quite as young as ours, satisfactory outcomes were found in this population. Recently, other studies in the same middle-aged population evaluated tenodesis in patients with tenosynovitis and biceps pulley lesions, with equally good results in these older patients.<sup>24,26</sup> No recent studies have analyzed outcomes in very young athletic patients undergoing tenodesis. Boileau et al.<sup>12</sup> performed a prospective evaluation of 25 patients undergoing SLAP repair and looked at their outcomes after BT. They found that among older (average age, 37 years) non-overhead athletes, the rate of return to the preinjury

level of play was 37.5% in the repair group versus 100% in the BT group. In the same series, several patients undergoing SLAP repair underwent revision to tenodesis later. Our study is different in the fact that it looked solely at patients younger than 25 years regarding outcomes after BT. Overall, our patients were younger and more athletic and some underwent prior procedures, but the functional outcome scores were quite good among the patients compared with the literature.<sup>1,26,27</sup>

Certainly, variability in results from prior SLAP studies may be a result of lack of reporting of repair constructs, number of anchors, and other variables including over-tensioning and hardware complications.<sup>22,31-34</sup> However, 1 recent systematic review reported the rate of return to play in baseball players as 22% to 64% after SLAP repair.<sup>22</sup> In our study, the rate of return to sport for overhead athletes was 77% after BT. Although the results trended toward better outcomes in overhead athletes after BT, this was not significant compared with non-overhead athletes. The rate of return to the same level of competition, however, was only 59%. We found a low revision rate for patients undergoing BT in the primary and revision settings. Although revision cases commonly have inferior results, there are often few alternative options available for failed SLAP repair in young athletes. At an average follow-up of nearly 3 years, BT in patients younger than 25 years yields reasonable clinical outcomes and return to sport. One cannot conclude from this study, however, that the results are superior to those of SLAP repair at this time because the population is heterogeneous and many patients underwent tenodesis for biceps tendinopathy alone.

Disappointing results of SLAP repair with respect to return to play have been reported in the literature.<sup>11,29,35</sup> Clinically, there has been some support for primary BT for the management of SLAP tears and biceps tendinopathy, although little agreement exists as to when to perform this operation in the primary setting. Previous studies have confirmed there is no difference in overhead kinematics after BT compared with SLAP repair.<sup>15</sup> The rate of return to the same level of play in this population, however, is uncertain. Our study suggests that, when indicated, BT is a safe option

**Table 2.** Patient-Reported Outcomes After Biceps Tenodesis

Patient-Reported Outcome	Preoperative	Follow-Up	<i>P</i> Value
ASES score	54.2 ± 18.1	81.6 ± 19.7	<.001
VAS pain score	5.0 ± 1.9	2.1 ± 2.1	<.001
ASES functional score	17.4 ± 6.2	25.1 ± 6.9	<.001
SST score	7.4 ± 2.8	10.1 ± 3.1	<.001

NOTE. Data are presented as mean ± standard deviation.

ASES, American Shoulder and Elbow Surgeons; SST, Simple Shoulder Test; VAS, visual analog scale.

for young patients with biceps-labral complex injuries with no deleterious effects.

This study reports on a large series of patients with 80% follow-up at a minimum of 2 years and a fairly uncommon procedure within a young unique athletic patient population with both validated outcome measures and range-of-motion measurements. Surgeons continue to ask the question as to whether BT, when indicated, can be performed safely in young patients. This study offers evidence that BT in young athletes can offer a satisfactory rate of return to sports without deleterious consequences.

### Limitations

This study has several limitations. The most notable limitation is the variability in the population studied. Given the low number of patients, the variability among indications for surgery cannot be controlled for. Certainly, there is no control group either, suggesting that perhaps some SLAP tears for which BT was performed may have been different types of tears. In other words, the decision toward BT was not randomized.

In addition, the number of surgeons included in the analysis could certainly have influenced the outcomes based on surgeon preferences and nuances in techniques. Some patients underwent a SLAP repair for an unstable superior labral segment at the time of surgery. We did not perform a subgroup analysis because in our power analysis, the numbers were not large enough to make this comparison. Finally, the inclusion of revision biceps patients is a limitation because these patients clearly underwent a failed SLAP repair, although it was helpful to have these patients as a comparison group to show the outcomes and it does appear to result in satisfactory outcomes in young patients, which is an important finding. Certainly, there is a possibility of a type II error given the small sample size.

### Conclusions

When indicated, BT offers a safe alternative to SLAP repair in young patients. BT in patients younger than 25 years yields satisfactory outcomes, with two-thirds of patients able to return to sports and a low revision rate.

### References

- Gottschalk MB, Karas SG, Ghattas TN, Burdette R. Subpectoral biceps tenodesis for the treatment of type II and IV superior labral anterior and posterior lesions. *Am J Sports Med* 2014;42:2128-2135.
- Gupta AK, Bruce B, Klosterman EL, McCormick F, Harris J, Romeo AA. Subpectoral biceps tenodesis for failed type II SLAP repair. *Orthopedics* 2013;36:e723-e728.
- Taylor SA, O'Brien SJ. Clinically relevant anatomy and biomechanics of the proximal biceps. *Clin Sports Med* 2016;35:1-18.
- Werner BC, Brockmeier SF, Gwathmey FW. Trends in long head biceps tenodesis. *Am J Sports Med* 2015;43:570-578.
- Ahmad CS, ElAttrache NS. Arthroscopic biceps tenodesis. *Orthop Clin North Am* 2003;34:499-506.
- Andrews JR, Carson WG Jr, McLeod WD. Glenoid labrum tears related to the long head of the biceps. *Am J Sports Med* 1985;13:337-341.
- Burkhart SS, Morgan CD, Kibler WB. The disabled throwing shoulder: Spectrum of pathology part I: Pathoanatomy and biomechanics. *Arthroscopy* 2003;19:404-420.
- Fedoriw WW, Ramkumar P, McCulloch PC, Lintner DM. Return to play after treatment of superior labral tears in professional baseball players. *Am J Sports Med* 2014;42:1155-1160.
- Keener JD, Brophy RH. Superior labral tears of the shoulder: Pathogenesis, evaluation, and treatment. *J Am Acad Orthop Surg* 2009;17:627-637.
- Neuman BJ, Boisvert CB, Reiter B, Lawson K, Ciccotti MG, Cohen SB. Results of arthroscopic repair of type II superior labral anterior posterior lesions in overhead athletes: Assessment of return to preinjury playing level and satisfaction. *Am J Sports Med* 2011;39:1883-1888.
- Strauss EJ, Salata MJ, Sershon RA, et al. Role of the superior labrum after biceps tenodesis in glenohumeral stability. *J Shoulder Elbow Surg* 2014;23:485-491.
- Boileau P, Parratte S, Chuinard C, Roussanne Y, Shia D, Bicknell R. Arthroscopic treatment of isolated type II SLAP lesions: Biceps tenodesis as an alternative to reinsertion. *Am J Sports Med* 2009;37:929-936.
- Brockmeier SF, Voos JE, Williams RJ III, et al. Outcomes after arthroscopic repair of type-II SLAP lesions. *J Bone Joint Surg Am* 2009;91:1595-1603.
- Burns JP, Tyorkin M, Snyder SJ. Arthroscopic repair of superior labral anterior-posterior lesions by the single-anchor double-suture technique. In: Cole BJ, Sekiya JK, eds. *Surgical techniques of the shoulder, elbow, and knee in sports medicine*. Ed 2. Philadelphia: Saunders, 2013;279-286.
- Chalmers PN, Trombley R, Cip J, et al. Postoperative restoration of upper extremity motion and neuromuscular control during the overhand pitch: Evaluation of tenodesis and repair for superior labral anterior-posterior tears. *Am J Sports Med* 2014;42:2825-2836.
- Cohen DB, Coleman S, Drakos MC, et al. Outcomes of isolated type II SLAP lesions treated with arthroscopic fixation using a bioabsorbable tack. *Arthroscopy* 2006;22:136-142.
- Denard PJ, Ladermann A, Parsley BK, Burkhart SS. Arthroscopic biceps tenodesis compared with repair of isolated type II SLAP lesions in patients older than 35 years. *Orthopedics* 2014;37:e292-e297.
- Ek ET, Shi LL, Tompson JD, Freehill MT, Warner JJ. Surgical treatment of isolated type II superior labrum anterior-posterior (SLAP) lesions: Repair versus biceps tenodesis. *J Shoulder Elbow Surg* 2014;23:1059-1065.
- Erickson J, Lavery K, Monica J, Gatt C, Dhawan A. Surgical treatment of symptomatic superior labrum anterior-posterior tears in patients older than 40 years: A systematic review. *Am J Sports Med* 2015;43:1274-1282.

20. Field LD, Savoie FH III. Arthroscopic suture repair of superior labral detachment lesions of the shoulder. *Am J Sports Med* 1993;21:783-790. discussion 790.
21. Friel NA, Karas V, Slabaugh MA, Cole BJ. Outcomes of type II superior labrum, anterior to posterior (SLAP) repair: Prospective evaluation at a minimum two-year follow-up. *J Shoulder Elbow Surg* 2010;19:859-867.
22. Gorantla K, Gill C, Wright RW. The outcome of type II SLAP repair: A systematic review. *Arthroscopy* 2010;26:537-545.
23. Elser F, Braun S, Dewing CB, Giphart JE, Millett PJ. Anatomy, function, injuries, and treatment of the long head of the biceps brachii tendon. *Arthroscopy* 2011;27:581-592.
24. Tahal DS, Katthagen JC, Vap AR, Horan MP, Millett PJ. Subpectoral biceps tenodesis for tenosynovitis of the long head of the biceps in active patients younger than 45 years old. *Arthroscopy* 2017;33:1124-1130.
25. Murthi AM, Vosburgh CL, Neviasser TJ. The incidence of pathologic changes of the long head of the biceps tendon. *J Shoulder Elbow Surg* 2000;9:382-385.
26. Vap AR, Katthagen JC, Tahal DS, et al. Isolated biceps reflection pulley tears treated with subpectoral biceps tenodesis: Minimum 2-year outcomes. *Arthroscopy* 2017;33:1788-1794.
27. Pogorzelski J, Horan MP, Hussain ZB, Vap A, Fritz EM, Millett PJ. Subpectoral biceps tenodesis for treatment of isolated type II SLAP lesions in a young and active population. *Arthroscopy* 2018;34:371-376.
28. Frank RM, Nho SJ, McGill KC, et al. Retrospective analysis of arthroscopic superior labrum anterior to posterior repair: prognostic factors associated with failure. *Adv Orthop* 2013;2013:125960.
29. Provencher MT, McCormick F, Dewing C, McIntire S, Solomon D. A prospective analysis of 179 type 2 superior labrum anterior and posterior repairs: Outcomes and factors associated with success and failure. *Am J Sports Med* 2013;41:880-886.
30. Sayde WM, Cohen SB, Ciccotti MG, Dodson CC. Return to play after type II superior labral anterior-posterior lesion repairs in athletes: A systematic review. *Clin Orthop Relat Res* 2012;470:1595-1600.
31. Creighton RA, Romeo AA, Brown FM Jr, Hayden JK, Verma NN. Revision arthroscopic shoulder instability repair. *Arthroscopy* 2007;23:703-709.
32. Fleisig GS, Andrews JR, Dillman CJ, Escamilla RF. Kinetics of baseball pitching with implications about injury mechanisms. *Am J Sports Med* 1995;23:233-239.
33. Kaar TK, Schenck RC Jr, Wirth MA, Rockwood CA Jr. Complications of metallic suture anchors in shoulder surgery: A report of 8 cases. *Arthroscopy* 2001;17:31-37.
34. McCormick F, Bhatia S, Chalmers P, Gupta A, Verma N, Romeo AA. The management of type II superior labral anterior to posterior injuries. *Orthop Clin North Am* 2014;45:121-128.
35. Provencher MT, LeClere LE, Romeo AA. Subpectoral biceps tenodesis. *Sports Med Arthrosc* 2008;16:170-176.