

THE JOURNAL OF BONE & JOINT SURGERY

JB&JS

*This is an enhanced PDF from The Journal of Bone and Joint Surgery
The PDF of the article you requested follows this cover page.*

Rapid Chondrolysis of the Knee After Anterior Cruciate Ligament Reconstruction: A Case Report

Mark A. Slabaugh, Nicole A. Friel and Brian J. Cole
J Bone Joint Surg Am. 2010;92:186-189. doi:10.2106/JBJS.I.00120

This information is current as of January 6, 2010

Reprints and Permissions

Click here to [order reprints or request permission](#) to use material from this article, or locate the article citation on jbjs.org and click on the [Reprints and Permissions] link.

Publisher Information

The Journal of Bone and Joint Surgery
20 Pickering Street, Needham, MA 02492-3157
www.jbjs.org

Rapid Chondrolysis of the Knee After Anterior Cruciate Ligament Reconstruction

A Case Report

By Mark A. Slabaugh, MD, Nicole A. Friel, BS, and Brian J. Cole, MD, MBA

Investigation performed at the Department of Orthopaedic Surgery, Rush University Medical Center, Chicago, Illinois

Chondrolysis is a devastating complication of surgery on any joint, resulting in the rapid and extensive destruction of the articular cartilage. Associated with this destruction is an equally large inflammatory response that causes adhesions in the lining of the involved joint. The inflammatory response manifests as arthrofibrosis and is typically seen within six months after the operation. Management of this unique complication is difficult because most patients are very young and have active lifestyles. Chondrolysis causes more immediate symptoms of pain and limited range of motion than does osteoarthritis, which often takes years to become symptomatic.

The exact cause of postoperative chondrolysis is unknown; however, several hypotheses have been entertained, such as the use of thermal treatment¹, occult infection with *Propionibacterium acnes*^{2,3}, idiopathic or iatrogenic osteochondral injury, high temperature of fluid during arthroscopic irrigation⁴, improperly placed implants, and the use of non-steroidal anti-inflammatory medications.

Recently, the use of intra-articular pain pumps for the administration of local anesthetics has come under scrutiny because of a possible association with early chondrolysis in the glenohumeral joint⁵⁻¹⁰. We are unaware, however, of any previously reported cases of chondrolysis in the knee associated with the use of an intra-articular pain pump. Here we report the case of a patient with chondrolysis of the knee; this case of our patient was clinically similar to several cases of patients with chondrolysis of the shoulder who had been referred for treatment at our institution. The patient and her parents were informed that data concerning the case would be submitted for publication, and they consented.

Case Report

A seventeen-year-old girl sustained anterior cruciate ligament and lateral meniscal tears during a tackling injury in a soccer game (Fig. 1). She underwent a routine anterior cruciate ligament reconstruction with use of quadruple ham-

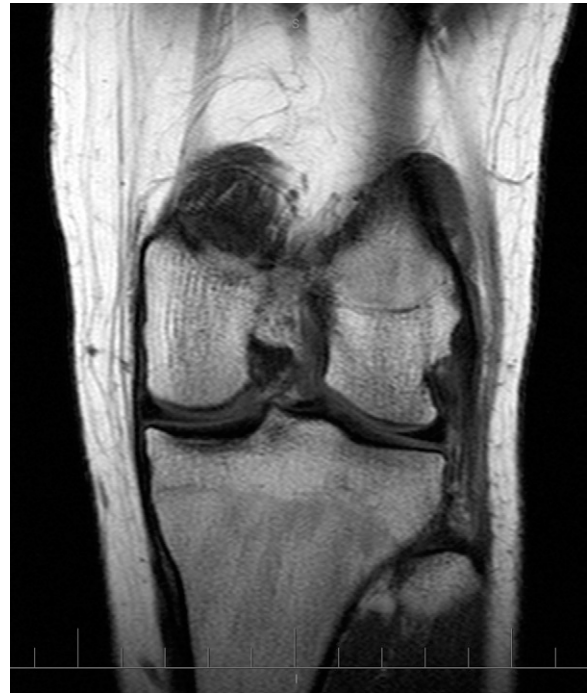

Fig. 1
T1-weighted magnetic resonance imaging scan acquired soon after the initial injury, demonstrating no evidence of cartilage damage.

string autograft, bioabsorbable fixation of the implants, and a lateral meniscal repair, after which a bupivacaine pain pump was placed into the suprapatellar pouch for forty-eight hours. The articular cartilage was noted to be pristine at the time of surgery, and no radiofrequency probes were used during the procedure. All other aspects of the procedure were routine with regard to irrigation pump and tourniquet use. During the immediate postoperative period, the patient had no

Disclosure: The authors did not receive any outside funding or grants in support of their research for or preparation of this work. One or more of the authors, or a member of his or her immediate family, received, in any one year, payments or other benefits in excess of \$10,000 or a commitment or agreement to provide such benefits from commercial entities (Arthrex, Genzyme, Zimmer, DePuy, Regentis).

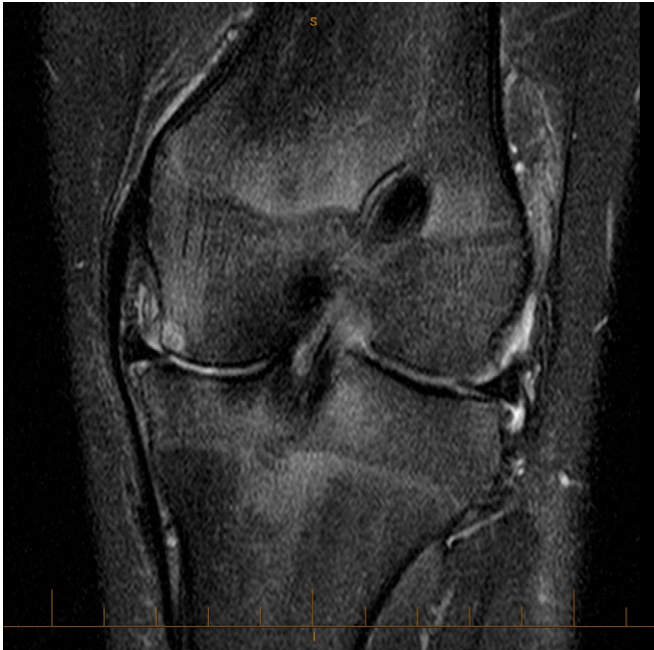

Fig. 2
T2-weighted magnetic resonance imaging scan acquired six months after surgery, demonstrating extensive tricompartamental chondrolysis.

swelling, hemarthrosis, or unexpected pain. Postoperatively, she had no complaints, but knee flexion was limited to 120° at eight weeks postoperatively. At that time, the patient underwent a manipulation of the knee under anesthesia (without the use of arthroscopy), and full flexion was obtained and maintained.

Approximately four months after the original surgery, the clinical course of the patient began to deteriorate, and she noticed crepitus in the medial aspect of the knee in association with swelling and pain in the knee. The results of examination at that time were suspicious for early degeneration of the knee, and magnetic resonance imaging confirmed the diagnosis of

extensive tricompartamental chondrolysis (Fig. 2). At that time, the primary surgeon performed a diagnostic arthroscopy, and it was confirmed that the patient had diffuse cartilage damage (Outerbridge grades 3 and 4)¹¹. She was then referred to the senior author (B.J.C.) for further treatment options. The examination performed by the senior author revealed that the anterior cruciate ligament was intact, with no evidence of a symptomatic meniscal tear. However, radiographic examination showed tricompartamental narrowing, greater on the medial side, with varus alignment of the limb. After the results of blood tests ruled out infection and rheumatologic conditions, a second-look arthroscopy confirmed the presence of extensive chondrolysis (Fig. 3).

Because of the severe cartilage changes (Fig. 4) and varus deformity, the patient then underwent a valgus-producing high tibial osteotomy, osteoarticular allografting of the medial femoral condyle with use of a 25 × 25-mm cylindrical graft placed adjacent to an 18 × 18-mm cylindrical graft, osteoarticular allografting of the lateral femoral condyle with use of a 25 × 25-mm cylindrical graft, and microfracture of the trochlea. The patella was left untouched. At twelve months after the operation, the results of the procedure were good. The knee range of motion was 0° to 123° of flexion, and there was no effusion. The knee was stable, and the patient had no pain when performing her daily activities, which included elliptical training and biking.

Discussion

We present a single case of chondrolysis in which the definitive cause is unknown. However, many likely known causes of chondrolysis can be ruled out. This patient did not have thermal treatment during the anterior cruciate ligament reconstruction, and occult infection was ruled out with normal results on blood tests. Chondrolysis arising from improperly placed implants, such as meniscal repair devices, is not likely because the chondrolysis was extensive and not localized to the area of meniscal repair.

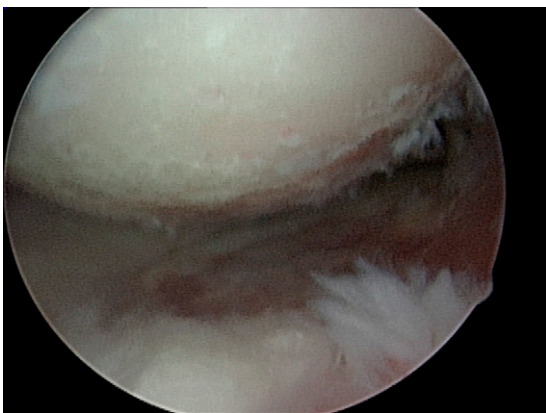


Fig. 3

Fig. 3 Arthroscopic photograph of the medial femoral compartment, showing extensive chondrolysis of the medial femoral condyle and medial tibial plateau. **Fig. 4** Chondrolysis of the medial femoral condyle is seen at the time of arthrotomy.

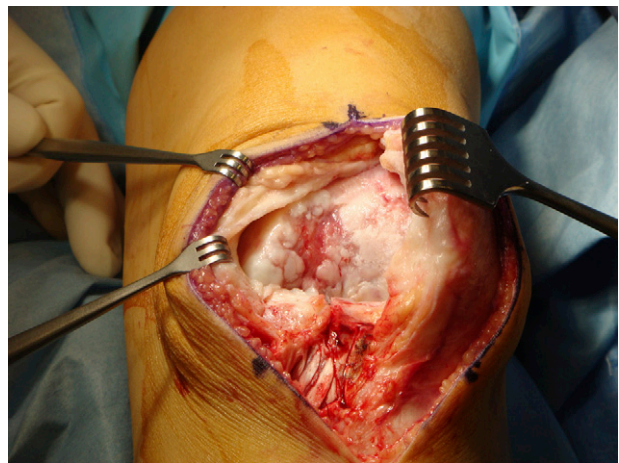


Fig. 4

The time frame from our patient's initial surgery to the onset of severe chondrolysis implicates an acute process. Articular cartilage degeneration from an iatrogenic injury during surgery is unlikely because the arthroscopic work was limited to the lateral compartment and because this type of degenerative change typically takes years to manifest¹². Chondrolysis often can be associated with chronic degeneration, which occurs as a result of the effects of total or subtotal meniscectomy or chronic instability in a cruciate-deficient knee¹³. However, given the short interval between injury and surgery as well as the successful initial repair of the torn meniscus and reconstruction of the anterior cruciate ligament, this is also an unlikely cause of the severe osteoarthritic changes.

It has been shown that rapid chondrolysis can occur when cartilage is exposed to toxic substances, such as methylmethacrylate and chlorhexidine¹⁴⁻¹⁶. Although the exact cause of the severe acute chondrolysis in this patient remains unknown, the postoperative intra-articular infusion of bupivacaine is a likely cause. The clinical course of our patient closely mirrors that of other patients who have been diagnosed with chondrolysis of the glenohumeral joint at our institution. Initially, these patients do well postoperatively but subsequently present with motion loss within a year after the initial surgery.

There are several case reports of the development of severe chondrolysis following the use of an intra-articular pain pump^{9,10,17}. In most documented cases, the chondrolysis has occurred in the glenohumeral joint. To our knowledge, there are no reports of chondrolysis in the knee as a result of the use of a postoperative pain pump. The lower rate of chondrolysis in the knee may be due to the large volume of that joint, which allows for more dilution of the local anesthetic as well as placement of a catheter in the suprapatellar pouch without resulting in impingement of the articular cartilage. Furthermore, the presence of a postoperative hematoma combined with the relatively easy egress of intra-articular fluids could dilute or reduce the concentration of the local anesthetic agent. In contrast, in the glenohumeral joint, the postoperative hematoma is typically small, the volume of the joint is less, the articular cartilage is thinner¹⁸, and the egress of fluid may be more limited.

The effect of bupivacaine on chondrocytes has been studied *in vitro*. Chu et al. demonstrated significant chondrotoxic effects on bovine chondrocyte cultures as well as osteochondral explants⁶. In further studies, they also showed a dose and time-dependent chondrotoxicity of bupivacaine in both bovine and human articular chondrocytes⁵. An intact articular cartilage surface provided partial protection from the cytotoxic effects of bupivacaine, suggesting that extra caution should be taken in patients with fissured or fibrillated articular cartilage surfaces.

Bupivacaine is not the only local anesthetic to have shown chondrotoxicity *in vitro*. Piper and Kim¹⁹ showed that both ropivacaine and bupivacaine were toxic both to intact human articular cartilage and to chondrocyte cul-

tures, although ropivacaine was significantly less toxic than bupivacaine. Karpie and Chu²⁰ have shown that lidocaine in both 1% and 2% solutions can decrease cell viability in a bovine model not only in damaged cartilage but also in cartilage with intact surfaces. In addition, they noted that different pH concentrations had no effect on cell viability, as the low pH of local anesthetics had been suggested as a potential cause of chondrolysis. Dragoo et al.²¹ showed that lidocaine or bupivacaine used with epinephrine was chondrotoxic, but that lidocaine alone caused minimal damage to the chondrocytes.

We have looked at the effects of intra-articular bupivacaine in a rabbit model at both short-term (one-week) and long-term (twelve-week) end points^{8,22}. We found chondrotoxicity after just one week, with decreased cartilage proteoglycan metabolism, decreased cell viability, and histologic changes of the cartilage and synovial membrane that were consistent with a significant pathologic response after infusion of bupivacaine as compared with the response seen after infusion of saline solution. Interestingly, the long-term study failed to detect permanent impairment of cartilage function but suggested a possible reparative response in the rabbit, with the ability of cartilage to recover from the chondrotoxic effects of the bupivacaine infusion. Further studies will need to be performed to elucidate the exact effect of local anesthetics on cartilage *in vitro* and *in vivo*.

It is not yet known whether a certain threshold concentration of bupivacaine is needed to induce cartilage degeneration. Single injections of local anesthetics have been used for years, with very few severe detrimental effects²³. The deleterious effects of bupivacaine may be due to the prolonged exposure of chondrocytes to that substance as a result of the use of continuous infusion protocols.

Postoperative administration of bupivacaine through a pain pump has been proven to be somewhat effective at controlling pain after orthopaedic surgery^{24,25}; hence, as this treatment continues to be used, more cases of chondrolysis may be encountered. The management of this complex problem is difficult, and our attention should be placed on prevention. Further studies are needed to elucidate the exact mechanism or cause of the chondrolysis that occurs after orthopaedic surgery. As is true with regard to chondrolysis of the shoulder²⁶⁻³⁰, exact treatment recommendations with regard to chondrolysis of the knee after orthopaedic surgery remain uncertain at this point. ■

Mark A. Slabaugh, MD
Nicole A. Friel, BS
Brian J. Cole, MD, MBA
Department of Orthopaedic Surgery,
Rush University Medical Center,
1725 West Harrison Street, Suite 1063, Chicago, IL 60612.
E-mail address: bcole@rushortho.com

References

1. Good CR, Shindle MK, Kelly BT, Wanich T, Warren RF. Glenohumeral chondrolysis after shoulder arthroscopy with thermal capsulorrhaphy. *Arthroscopy*. 2007;23:797.e1-5.
2. Delyle LG, Vittecoq O, Bourdel A, Duparc F, Michot C, Le Loet X. Chronic destructive oligoarthritis associated with *Propionibacterium acnes* in a female patient with acne vulgaris: septic-reactive arthritis? *Arthritis Rheum*. 2000;43:2843-7.
3. Levy PY, Fenollar F, Stein A, Borriore F, Cohen E, Lebaill B, Raout D. *Propionibacterium acnes* postoperative shoulder arthritis: an emerging clinical entity. *Clin Infect Dis*. 2008;46:1884-6.
4. Lu Y, Edwards RB 3rd, Nho S, Cole BJ, Markel MD. Lavage solution temperature influences depth of chondrocyte death and surface contouring during thermal chondroplasty with temperature-controlled monopolar radiofrequency energy. *Am J Sports Med*. 2002;30:667-73.
5. Chu CR, Izzo NJ, Coyle CH, Papas NE, Logar A. The in vitro effects of bupivacaine on articular chondrocytes. *J Bone Joint Surg Br*. 2008;90:814-20.
6. Chu CR, Izzo NJ, Papas NE, Fu FH. In vitro exposure to 0.5% bupivacaine is cytotoxic to bovine articular chondrocytes. *Arthroscopy*. 2006;22:693-9.
7. Greis PE, Legrand A, Burks RT. Bilateral shoulder chondrolysis following arthroscopy. A report of two cases. *J Bone Joint Surg Am*. 2008;90:1338-44.
8. Gomoll AH, Kang RW, Williams JM, Bach BR, Cole BJ. Chondrolysis after continuous intra-articular bupivacaine infusion: an experimental model investigating chondrotoxicity in the rabbit shoulder. *Arthroscopy*. 2006;22:813-9.
9. Hansen BP, Beck CL, Beck EP, Townsley RW. Postarthroscopic glenohumeral chondrolysis. *Am J Sports Med*. 2007;35:1628-34.
10. Bailie DS, Ellenbecker T. Severe chondrolysis after shoulder arthroscopy: a case series. *J Shoulder Elbow Surg*. 2009;18:742-7.
11. Outerbridge RE. The etiology of chondromalacia patellae. *J Bone Joint Surg Br*. 1961;43:752-7.
12. Mankin HJ. The response of articular cartilage to mechanical injury. *J Bone Joint Surg Am*. 1982;64:460-6.
13. Nelson F, Billingham RC, Pidoux I, Reiner A, Langworthy M, McDermott M, Malogne T, Sitler DF, Kilambi NR, Lenczner E, Poole AR. Early post-traumatic osteoarthritis-like changes in human articular cartilage following rupture of the anterior cruciate ligament. *Osteoarthritis Cartilage*. 2006;14:114-9.
14. Douw CM, Bulstra SK, Vandenbroucke J, Geesink RG, Vermeulen A. Clinical and pathological changes in the knee after accidental chlorhexidine irrigation during arthroscopy. Case reports and review of the literature. *J Bone Joint Surg Br*. 1998;80:437-40.
15. Leclair A, Gangi A, Lacaze F, Javier RM, Bonidan O, Kempf JF, Bonnomet F, Limbach FX, Kuntz JL, Dietmann JL, Sibilia J. Rapid chondrolysis after an intra-articular leak of bone cement in treatment of a benign acetabular subchondral cyst: an unusual complication of percutaneous injection of acrylic cement. *Skeletal Radiol*. 2000;29:275-8.
16. van Huyssteen AL, Bracey DJ. Chlorhexidine and chondrolysis in the knee. *J Bone Joint Surg Br*. 1999;81:995-6.
17. Petty DH, Jazrawi LM, Estrada LS, Andrews JR. Glenohumeral chondrolysis after shoulder arthroscopy: case reports and review of the literature. *Am J Sports Med*. 2004;32:509-15.
18. Fox JA, Cole BJ, Romeo AA, Meiningner AK, Glenn RE, Bicos J, Hayden JK, Dorow CB. Articular cartilage thickness of the humeral head: an anatomic study. *Orthopedics*. 2008;31:216.
19. Piper SL, Kim HT. Comparison of ropivacaine and bupivacaine toxicity in human articular chondrocytes. *J Bone Joint Surg Am*. 2008;90:986-91.
20. Karpie JC, Chu CR. Lidocaine exhibits dose- and time-dependent cytotoxic effects on bovine articular chondrocytes in vitro. *Am J Sports Med*. 2007;35:1621-7.
21. Dragoo JL, Korotkova T, Kanwar R, Wood B. The effect of local anesthetics administered via pain pump on chondrocyte viability. *Am J Sports Med*. 2008;36:1484-8.
22. Gomoll AH, Yanke AB, Kang RW, Chubinskaya S, Williams JM, Bach BR, Cole BJ. Long-term effects of bupivacaine on cartilage in a rabbit shoulder model. *Am J Sports Med*. 2009;37:72-7.
23. Bellamy N, Campbell J, Robinson V, Gee T, Bourne R, Wells G. Intraarticular corticosteroid for treatment of osteoarthritis of the knee. *Cochrane Database Syst Rev*. 2006;2:CD005328.
24. Alford JW, Fadale PD. Evaluation of postoperative bupivacaine infusion for pain management after anterior cruciate ligament reconstruction. *Arthroscopy*. 2003;19:855-61.
25. Hoenecke HR Jr, Pulido PA, Morris BA, Fronek J. The efficacy of continuous bupivacaine infiltration following anterior cruciate ligament reconstruction. *Arthroscopy*. 2002;18:854-8.
26. Cole BJ, Yanke A, Provencher MT. Nonarthroplasty alternatives for the treatment of glenohumeral arthritis. *J Shoulder Elbow Surg*. 2007;16(5 Suppl):S231-40.
27. McCarty LP 3rd, Cole BJ. Reconstruction of the glenohumeral joint using a lateral meniscal allograft to the glenoid and osteoarticular humeral head allograft after bipolar chondrolysis. *J Shoulder Elbow Surg*. 2007;16:e20-4.
28. McCarty LP 3rd, Cole BJ. Nonarthroplasty treatment of glenohumeral cartilage lesions. *Arthroscopy*. 2005;21:1131-42.
29. Romeo AA, Cole BJ, Mazzocca AD, Fox JA, Freeman KB, Joy E. Autologous chondrocyte repair of an articular defect in the humeral head. *Arthroscopy*. 2002;18:925-9.
30. Nicholson GP, Goldstein JL, Romeo AA, Cole BJ, Hayden JK, Twigg SL, McCarty LP, Deterline AJ. Lateral meniscus allograft biologic glenoid arthroplasty in total shoulder arthroplasty for young shoulders with degenerative joint disease. *J Shoulder Elbow Surg*. 2007;16(5 Suppl):S261-6.