

Articular Cartilage Thickness of the Humeral Head: An Anatomic Study

JEFF A. FOX, MD; BRIAN J. COLE, MD, MBA; ANTHONY A. ROMEO, MD; ALEXANDER K. MEININGER, MD; R. EDWARD GLENN JR, MD; JAMES BICOS, MD; JENNIFER K. HAYDEN, MSN; CHRISTINA B. DOROW, MD

abstract

This study determined the thickness of normal humeral head articular cartilage by anatomic cross section using computer-aided image analysis software. Sixteen adult cadaveric humeral heads were analyzed. Our findings reveal that the thickness of humeral articular cartilage is substantially thinner than articular cartilage found in the knee. The cartilage is thickest in the central portion of the head and becomes progressively thinner towards the periphery. Surgical techniques used to treat pathology in the glenohumeral joint, specifically thermal energy or mechanical debridement, may have deleterious effects on the relatively thin humeral articular cartilage.

Articular cartilage thickness has been extensively studied in the knee.¹⁻⁷ However, there is a paucity of data regarding the thickness of articular cartilage of the humeral head. Most characterizations of humeral head articular cartilage have been performed using radiographic imaging studies, specifically magnetic resonance imaging with and without the use of intraarticular contrast.⁸⁻¹⁰ The radiographic data obtained in two of these studies were compared to the corresponding data obtained by direct measurement of the articular surface. In both studies, only limited areas of the humeral head were analyzed, and direct measurements of the articular surface were performed by observers using loupe magnification. The difficulty in accurately imaging the highly spherical humeral head and the substantially thinner articular cartilage found on the hu-

meral head as compared to the knee were the reasons given for the inferior results. According to Eckstein², magnetic resonance imaging (MRI) of strongly curved surfaces can overestimate cartilage thickness without appropriate derivations. So-slovesky et al¹¹ used stereophotogrammetry to define the geometry of the glenohumeral articulation and reported on surface area and cartilage thickness of both the humeral head and the glenoid.

The purpose of this study was to determine the thickness of humeral head articular cartilage via anatomic measurements from multiple cross sections of cadaveric humeral heads using computer-aided image analysis software. From this data a topographical map of humeral head articular cartilage was developed. This information may serve as a standardization of normal articular cartilage thickness of the humeral head.

MATERIALS AND METHODS

Eighteen adult cadaveric humeri (8 left and 10 right) were obtained through the anatomic gift association at Rush University Medical Center. The age of the specimens ranged from 53 to 91 years. Overlying muscle and soft tissue were sharply dissected away with a scalpel and scissors with care taken to avoid injury to the articular surface. Two right humeral heads were eliminated: one head demonstrated evidence of degenerative changes, and the second head had developed subchondral cysts. Thus, 16 humeral heads were analyzed. Humeral heads were cut at the anatomical neck with a band saw. The heads were then placed in a plastic container and potted in Isocryl (an acrylic mold). The purpose of this was to create a stable block

Dr Fox is from Central States Orthopedic Specialists, The Central States Cartilage Restoration Center, Tulsa, Oklahoma; and Drs Cole, Romeo, Meininger, Glenn, Bicos, Dorow and Ms Hayden are from the Department of Orthopedic Surgery, Rush University Medical Center, Chicago, Illinois.

Drs Fox, Cole, Romeo, Meininger, Glenn, Bicos, and Dorow, and Ms Hayden have no relevant financial relationships to disclose.

Correspondence should be addressed to: Brian J. Cole, MD, MBA, Department of Orthopedics/Anatomy and Cell Biology, Rush University Medical Center, 1725 W Harrison Ave, Suite 1063, Chicago, IL 60612.

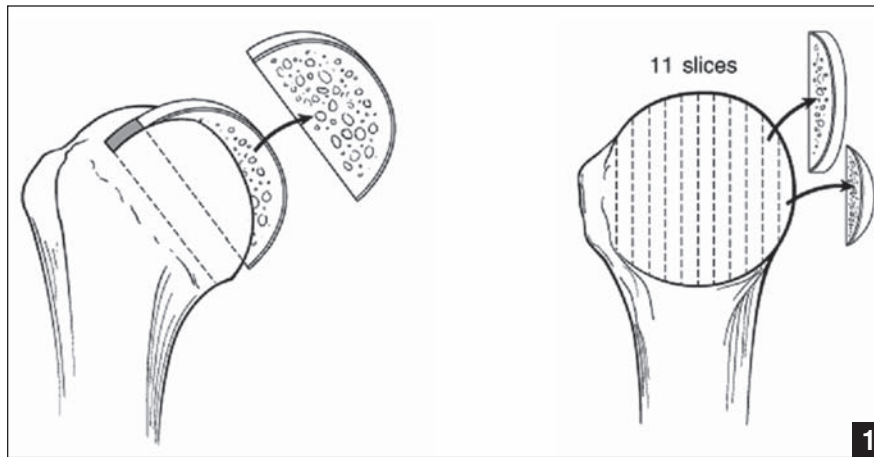


Figure 1: After removing the humeral head at the anatomic neck, the head was then sectioned in the sagittal plane at 3-mm increments.

in which the heads could each be sliced at a uniform width. Once dry, the Isocryl block was removed and the humeral heads were sectioned at 3-mm intervals in the sagittal plane with a band saw (Figure 1). Specimens were numbered according to anatomic location. The most peripheral sections of the humeral heads were discarded to avoid falsely elevated articular cartilage measurements due to the oblique nature of the cuts in these areas.

To enhance contrast and visibility of the articular cartilage, the specimens were briefly immersed in a solution comprised of 0.25% methylene blue in 1% acetic acid. Excess methylene blue was removed by rinsing the specimens in 95% ethyl alcohol followed by water to demarcate the articular cartilage from the underlying subchondral bone (Figure 2). Fixed distance digital photography was used to capture a digital image of each specimen. A transparent metric ruler was also imaged from the same preset distance for reference of measurement. The digital images were analyzed with a computer software program (Scion Image; Scion Corp, Frederick, Maryland) according to a previously validated technique¹² to allow for accurate measurement of the articular cartilage thickness. Scion Image is the PC version of National Institutes of Health (NIH) Image, a public domain

imaging processing and analysis program designed to run on Macintosh computers. The program was developed at the NIH and is available for download at <http://rsb.info.nih.gov/nih-image/>. Measurement features were calibrated using the metric ruler image to discern that 7.787 pixels=1 mm.

Using the apex of each section as the center of reference, the sections were analyzed at 22.5° intervals, producing 7 points along each section from which the articular cartilage thickness was measured (Figure 3). Measurement tools (accurate to the 1/100th of a millimeter) were used in a click-and-drag fashion by a single investigator to measure the articular cartilage thickness. From the raw data a topographical map of the humeral head articular cartilage was generated. The map was used to divide the humeral head articular surface into 9 sectors labeled A-I (Figure 4). The mean articular cartilage thickness was calculated for each sector. Each sector was then compared to every other sector (A to B, A to C, A to D, etc.). A commercially available computer program was utilized for statistical analysis (SPSS version 11.5; SPSS Inc, Chicago, Illinois). Friedman tests were performed to detect differences in articular cartilage thickness between the sectors of the humeral head. Statistical significance was defined as $P < .05$.



Figure 2: Representative humeral head section after staining the articular surface with Methylene blue.

RESULTS

An average of 11 sagittal sections was obtained from each humeral head (range, 9-12 sections). A total of 1144 data points were collected from the 16 specimens. The average thickness of the articular cartilage measured 0.89 mm (range, 0.13-2.09 mm, SD 0.29 mm). Articular cartilage was thickest in the central third of the humeral head (Sectors D, E, and F) and decreased peripherally (Table 1). The mean thickness of the anatomic center of the humeral head (90° from axis of the central cross section) was 1.21 mm (range, 0.90-1.80 mm, SD 0.25 mm) (Figure 5). The central sector of the humeral head (Sector E) was the thickest sector with a mean articular cartilage thickness of 1.11 mm (range, 0.94-1.42 mm, SD 0.12 mm). The central sector was significantly thicker than all other sectors of the humeral head with the exception of the central-inferior sector F ($P = .20$). The articular thickness of anterior third of the

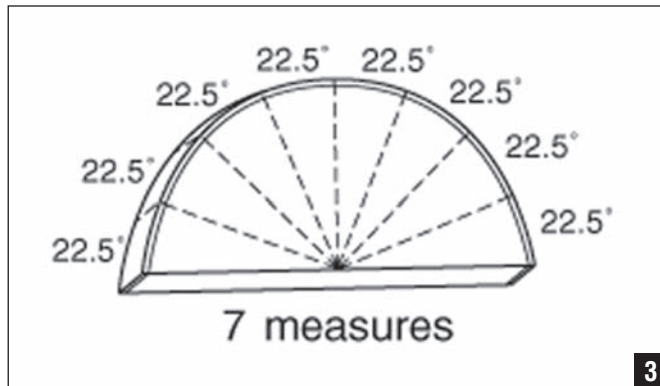


Figure 3: Each specimen was numbered according to location along the humeral head. Seven articular cartilage thickness measurements were collected from each specimen.

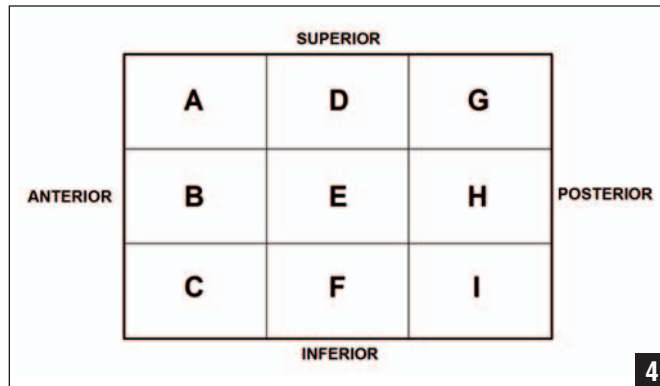


Figure 4: Diagram of humeral head sectors.

humeral head was not significantly different when compared to the corresponding posterior third of the humeral head with the exception of the superior sectors (Sector G was significantly thicker than Sector A; $P=.03$). There was no significant difference noted when the superior sectors were compared to the corresponding inferior sectors.

DISCUSSION

To our knowledge this is the first investigation in the English literature to define the articular cartilage thickness of the humeral head at multiple locations via anatomic measurements using computer-aided image analysis software. The image analysis software used in the present study has been validated previously in a veterinary report comparing MRI and histomorphologic measurements of articular cartilage thickness revealing strong correlations without significant differences ($P \leq .001$).¹² Scion Image has also been used in prior studies within the orthopedic literature to measure joint space narrowing of the wrist and digits,¹³ the effect of impaction bone grafting on prosthetic fit in the proximal humerus,¹⁴ the impact of Ho:YAG laser bone ablation of the lumbar spine,¹⁵ and the determination of an optimal femoral donor site in autologous osteochondral transplantation.¹⁶ Other versions of computer imaging software have also been used to determine shoulder

Table				
Articular Cartilage Thickness Measurements of the Humeral Head				
Sector	Minimum Thickness (mm)	Maximum Thickness (mm)	Mean Thickness (mm)	Standard Deviation (mm)
A	0.44	0.97	0.77	0.15
B	0.62	1.03	0.82	0.13
C	0.54	1.12	0.77	0.15
D	0.77	1.26	0.98	.015
E	0.94	1.42	1.11	0.12
F	0.74	1.53	1.01	0.22
G	0.62	1.07	0.86	0.15
H	0.57	1.24	0.89	0.16
I	0.50	1.30	0.82	0.20

capsular thickness¹⁷ and patellar articular cartilage thickness.² The accuracy of the image analysis software used in the present study has also been published previously in a study analyzing prostate cancer histologic sections.¹⁸

Our results indicate that the thickness of the adult humeral head articular cartilage ranges from 0.28 to 2.09 mm, with the average thickness of the articular cartilage measuring 0.89 mm. The measurements obtained in the present study suggest that the articular cartilage thickness of the humeral head is thinner than what

has been previously reported. Soslowsky et al¹¹ analyzed 28 humeral heads with an average age of 72 years using a complex stereophotogrammetry method and determined the mean articular cartilage thickness to be 1.44 ± 0.3 mm.

Graichen et al⁸ compared quantitative MRI measurements to A-mode ultrasound measurements of humeral head articular cartilage in eight humeral heads with a relatively young average age of 50.6 years. The mean articular cartilage thickness as determined by quantitative MRI was 1.2 ± 0.09 mm, and the mean

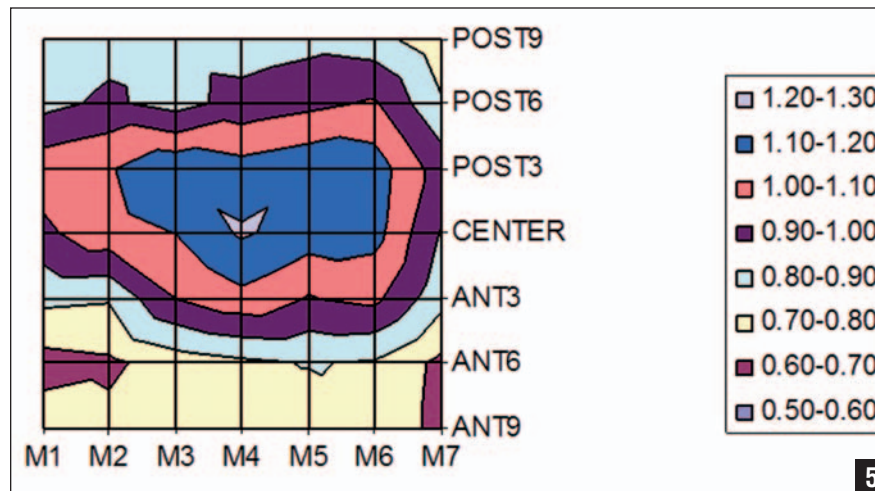


Figure 5: Topographical map of the humeral head articular surface.

thickness as determined by A-mode ultrasound was 1.4 ± 0.12 mm. No significant difference was found between the two methods. A difference in the current study compared to the previous studies relates to the processing of the humeral heads for articular cartilage visualization. In the study by Soslowski et al,¹¹ the humeral heads were initially measured in the intact state followed by repeat measurements obtained after dissolution of the articular cartilage with a sodium hypochlorite solution. The articular cartilage thickness was then determined as the difference in thickness between the two measurements. No processing of the humeral heads was reported in the study by Graichen.⁸ In the current study, the humeral heads were potted in an acrylic mold to enhance sectioning of the heads, and the articular surfaces were stained with Methylene blue and subsequently washed with 95% ethyl alcohol to enhance the demarcation of the articular cartilage-subchondral bone interface. Another potential reason for the differences noted in this study was the use of embalmed specimens as opposed to fresh-frozen specimens. The age of the humeral heads used in the present study were older than the humeral heads used in the study by Graichen⁸ but similar in age to the humeral heads used by Soslowski.¹¹ This was not felt to be a factor in the different

results obtained in the present study.

The information provided by this anatomic study lends insight into several aspects of shoulder surgery. First, the articular cartilage thickness of the humeral head is substantially thinner than the articular cartilage thickness seen in the normal human femoral condyle (3-4 mm).⁴ With the increasing use of thermal radiofrequency devices in arthroscopic surgery, it is important to know the thickness of the articular cartilage being treated directly or indirectly. Thermal chondroplasty is a commonly used treatment for chondromalacia during arthroscopic procedures. Hogan et al¹⁹ described the progressive loss of articular cartilage from the medial femoral condyle of an individual treated with thermal chondroplasty for modified Outerbridge Grade III chondromalacia. Studies have shown that both monopolar and bipolar radiofrequency energy applied to human articular cartilage leads to chondrocyte death, with bipolar radiofrequency energy causing significantly more chondrocyte death than monopolar radiofrequency.^{20,21} The depth of chondrocyte injury is proportional to the time exposed to radiofrequency energy²¹ and the strength of energy delivered.²² At a bipolar radiofrequency setting of 133 to 147 kHz (1000-1100C), a treatment time of only 10 seconds was found to produce

chondrocyte death to a depth of 1.5 mm. The articular cartilage used in the referenced study was procured from the human knee. Knowing that the thickest regions of articular cartilage on the humeral head averages 1.11 mm, a similar treatment used on the humeral head articular surface would easily penetrate the entire articular surface. In fact, a treatment time of 15 seconds produced chondrocyte death to a depth of >2 mm, which is deeper than any articular cartilage measurement obtained in this study.

The adverse effects of thermal capsulorrhaphy for the treatment of shoulder instability have been well documented.²³⁻²⁷ When performing an arthroscopic thermal capsulorrhaphy, some of the thermal energy delivered to the capsule can be absorbed by the neighboring humeral articular cartilage or local temperatures may rise to critical levels if flow is inadequate. The potential exists for enough energy to be absorbed by the humeral articular surface to cause chondrocyte death and matrix degeneration. A case report in the literature describes a full thickness loss of humeral articular cartilage that was believed to be the result of a thermal shrinkage procedure of the anterior glenohumeral joint capsule.²⁸ Similar cases have been presented by Petty et al.²⁹

Finally, the use of osteochondral grafts for the treatment of isolated Grade IV articular defects has been well reported in the knee.³⁰⁻³³ In contrast, osteochondral allograft transplantation in the shoulder has not been extensively studied. The use of allografts for humeral head defects has been reported for the treatment of osteochondritis dessicans³⁴ and glenohumeral dislocation.^{35,36} The information provided by this baseline anatomic study may help direct future investigations in this area.

A limitation of the study is the use of a relatively small number of specimens. In addition, the use of embalmed specimens and the post-dissection processing of the humeral heads used to enhance articular cartilage visualization as previously dis-

cussed may potentially have led to desiccation of the specimens yielding results that differed from previous studies.^{8,11} However, our results highlight the differences in thickness of the articular cartilage of the humeral head compared to the articular cartilage thickness of the knee.

CONCLUSION

Articular cartilage thickness of the humeral head is substantially thinner than the articular cartilage found in the knee. The cartilage is thickest in the central portion of the humeral head and becomes progressively thinner at the periphery. No significant difference in cartilage thickness is seen between corresponding superior and inferior points on the humeral head. No significant difference in cartilage thickness is seen between corresponding anterior and posterior points on the humeral head except superiorly where the posterior portion of the head is significantly thicker than the anterior portion of the head. The information presented in this study provides an understanding of humeral head articular anatomy and should alert the orthopedist to exercise caution if thermal energy is used for the treatment of conditions about the glenohumeral joint to avoid injury to the articular surface.

REFERENCES

1. Adam C, Eckstein F, Milz S, Schulte E, Becker C, Putz R. The distribution of cartilage thickness in the knee-joints of old-aged individuals -- measurement by A-mode ultrasound. *Clin Biomech (Bristol, Avon)*. 1998; 13(1):1-10.
2. Eckstein F, Adam C, Sittek H, et al. Non-invasive determination of cartilage thickness throughout joint surfaces using magnetic resonance imaging. *J Biomech*. 1997; 30(3):285-289.
3. Eckstein F, Gavazzeni A, Sittek H, et al. Determination of knee joint cartilage thickness using three-dimensional magnetic resonance chondro-crassometry (3D MR-CCM). *Magn Reson Med*. 1996; 36(2):256-265.
4. Hall FM, Wyshak G. Thickness of articular cartilage in the normal knee. *J Bone Joint Surg Am*. 1980; 62(3):408-413.
5. Kladny B, Martus P, Schiwy-Bochat KH, Weseloh G, Swoboda B. Measurement of

- cartilage thickness in the human knee-joint by magnetic resonance imaging using a three-dimensional gradient-echo sequence. *Int Orthop*. 1999; 23(5):264-267.
6. Kshirsagar AA, Watson PJ, Tyler JA, Hall LD. Measurement of localized cartilage volume and thickness of human knee joints by computer analysis of three-dimensional magnetic resonance images. *Invest Radiol*. 1998; 33(5):289-299.
7. Wayne JS, Brodrick CW, Mukherjee N. Measurement of articular cartilage thickness in the articulated knee. *Ann Biomed Eng*. 1998; 26(1):96-102.
8. Graichen H, Jakob J, von Eisenhart-Rothe R, Englmeier KH, Reiser M, Eckstein F. Validation of cartilage volume and thickness measurements in the human shoulder with quantitative magnetic resonance imaging. *Osteoarthritis Cartilage*. 2003; 11(7):475-482.
9. Hodler J, Loreda RA, Longo C, Trudell D, Yu JS, Resnick D. Assessment of articular cartilage thickness of the humeral head: MR-anatomic correlation in cadavers. *AJR Am J Roentgenol*. 1995; 165(3):615-620.
10. Yeh LR, Kwak S, Kim YS, et al. Evaluation of articular cartilage thickness of the humeral head and the glenoid fossa by MR arthrography: anatomic correlation in cadavers. *Skeletal Radiol*. 1998; 27(9):500-504.
11. Soslowsky LJ, Flatow EL, Bigliani LU, Mow VC. Articular geometry of the glenohumeral joint. *Clin Orthop Relat Res*. 1992; (285):181-190.
12. Murray RC, Branch MV, Tranquille C, Woods S. Validation of magnetic resonance imaging for measurement of equine articular cartilage and subchondral bone thickness. *Am J Vet Res*. 2005; 66(11):1999-2005.
13. Sharp JT, Gardner JC, Bennett EM. Computer-based methods for measuring joint space and estimating erosion volume in the finger and wrist joints of patients with rheumatoid arthritis. *Arthritis Rheum*. 2000; 43(6):1378-1386.
14. Hacker SA, Boorman RS, Lippitt SB, Matsen FA III. Impaction grafting improves the fit of uncemented humeral arthroplasty. *J Shoulder Elbow Surg*. 2003; 12(5):431-435.
15. Hafez MI, Coombs RR, Zhou S, McCarthy ID. Ablation of bone, cartilage, and facet joint capsule using Ho:YAG laser. *J Clin Laser Med Surg*. 2002; 20(5):251-255.
16. Terukina M, Fujioka H, Yoshiya S, et al. Analysis of the thickness and curvature of articular cartilage of the femoral condyle. *Arthroscopy*. 2003; 19(9):969-973.
17. Ciccone WJ II, Hunt TJ, Lieber R, Pedowitz R, Esch J, Tasto JP. Multi-quadrant digital analysis of shoulder capsular thickness. *Arthroscopy*. 2000; 16(5):457-461.
18. Noguchi M, Stamey TA, McNeal JE, Yemoto

- CE. Assessment of morphometric measurements of prostate carcinoma volume. *Cancer*. 2000; 89(5):1056-1064.
19. Hogan CJ, Diduch DR. Progressive articular cartilage loss following radiofrequency treatment of a partial-thickness lesion. *Arthroscopy*. 2001; 17(6):E24.
20. Edwards RB III, Lu Y, Nho S, Cole BJ, Markel MD. Thermal chondroplasty of chondromalacic human cartilage. An ex vivo comparison of bipolar and monopolar radiofrequency devices. *Am J Sports Med*. 2002; 30(1):90-97.
21. Lu Y, Edwards RB III, Nho S, Heiner JP, Cole BJ, Markel MD. Thermal chondroplasty with bipolar and monopolar radiofrequency energy: effect of treatment time on chondrocyte death and surface contouring. *Arthroscopy*. 2002; 18(7):779-788.
22. Lu Y, Edwards RB III, Kalscheur VL, Nho S, Cole BJ, Markel MD. Effect of bipolar radiofrequency energy on human articular cartilage. Comparison of confocal laser microscopy and light microscopy. *Arthroscopy*. 2001; 17(2):117-123.
23. Abrams JS. Thermal capsulorrhaphy for instability of the shoulder: concerns and applications of the heat probe. *Instr Course Lect*. 2001; (50):29-36.
24. Barber FA, Uribe JW, Weber SC. Current applications for arthroscopic thermal surgery. *Arthroscopy*. 2002; 18(2 suppl 1):40-50.
25. D'Alessandro DF, Bradley JP, Fleischli JE, Connor PM. Prospective evaluation of thermal capsulorrhaphy for shoulder instability: indications and results, two- to five-year follow-up. *Am J Sports Med*. 2004; 32(1):21-33.
26. Miniaci A, McBirnie J. Thermal capsular shrinkage for treatment of multidirectional instability of the shoulder. *J Bone Joint Surg Am*. 2003; 85(12):2283-2287.
27. Wong KL, Williams GR. Complications of thermal capsulorrhaphy of the shoulder. *J Bone Joint Surg*. 2001;83-A(Suppl 2 Pt 2):151-155.
28. Romeo AA, Cole BJ, Mazzocca AD, Fox JA, Freeman KB, Joy E. Autologous chondrocyte repair of an articular defect in the humeral head. *Arthroscopy*. 2002; 18(8):925-929.
29. Petty DH, Jazrawi LM, Estrada LS, Andrews JR. Glenohumeral chondrolysis after shoulder arthroscopy: case reports and review of the literature. *Am J Sports Med*. 2004; 32(2):509-515.
30. Cain EL, Clancy WG. Treatment algorithm for osteochondral injuries of the knee. *Clin Sports Med*. 2001; 20(2):321-42.
31. Chu CR, Convery FR, Akeson WH, Meyers M, Amiel D. Articular cartilage transplantation. Clinical results in the knee. *Clin Orthop Relat Res*. 1999; (360):159-168.
32. Hangody L, Fules P. Autologous osteochon-

■ Feature Article

- dral mosaicplasty for the treatment of full-thickness defects of weight-bearing joints: ten years of experimental and clinical experience. *J Bone Joint Surg Am.* 2003; 85(suppl 2):25-32.
33. Mandelbaum BR, Browne JE, Fu F, et al. Articular cartilage lesions of the knee. *Am J Sports Med.* 1998; 26(6):853-861.
 34. Johnson DL, Warner JJ. Osteochondritis dissecans of the humeral head: treatment with a matched osteochondral allograft. *J Shoulder Elbow Surg.* 1997; 6(2):160-163.
 35. Gerber C, Lambert SM. Allograft reconstruction of segmental defects of the humeral head for the treatment of chronic locked posterior dislocation of the shoulder. *J Bone Joint Surg Am.* 1996; 78(3):376-382.
 36. Yagishita K, Thomas BJ. Use of allograft for large Hill-Sachs lesion associated with anterior glenohumeral dislocation. A case report. *Injury.* 2002; 33(9):791-794.