

Lateral meniscus allograft biologic glenoid arthroplasty in total shoulder arthroplasty for young shoulders with degenerative joint disease

Gregory P. Nicholson, MD, Jordan L. Goldstein, MD, Anthony A. Romeo, MD, Brian J. Cole, MD, Jennifer K. Hayden, RN, Stacy L. Twigg, PA-C, L. Pearce McCarty, MD, and Alvin J. Dettlerline, MD, Chicago, IL

To avoid potential polyethylene problems in younger shoulders with degenerative joint disease (DJD) requiring arthroplasty, lateral meniscus allograft (LMA) was used as a biologic resurfacing of the glenoid. We report preliminary, short-term results of this technique in a younger, higher-demand population. The shoulders of 20 men and 10 women, with an average age of 42 years (range, 18 to 52 years), underwent total shoulder arthroplasty with a LMA. A metallic prosthesis was used on the humerus. Etiology of the DJD was osteoarthritis in 16, postinstability surgery in 8, traumatic in 4, and failed open reduction with internal fixation in 2. Twenty-two (73%) had previous shoulder surgery. Preoperative average scores were American Shoulder and Elbow Surgeons (ASES), 38; Simple Shoulder Test (SST), 3.3; and Visual Analogue Scale (VAS), 6.4. The average active forward elevation was 96° and external rotation was 26°. Average follow-up was 18 months (range, 12 to 48 months). Postoperative average scores were ASES, 69; SST, 7.8; and VAS, 2.3. Active forward elevation was 139° and external rotation was 53°. All were significant improvements ($P < .02$). Most (94%) would have the surgery again. Radiologic evaluation at 1 year revealed an average joint space of 1.8 mm on anteroposterior views and 1.6 mm on axillary views. Five complications (17%) occurred within the first postoperative year, all of which required reoperation. Pain resulted in 2 conversions to a polyethylene glenoid. Polyethylene glenoids in young shoulders risk early failure. For young, high-demand shoulders with DJD requiring arthroplasty, the

LMA shows promise. Most problems presented within the first year. Although not perfect, it provided significant pain relief, range-of-motion gains, and patient satisfaction without the risk of poly wear or loosening. Longer-term follow-up will be required to determine ultimate durability. (*J Shoulder Elbow Surg* 2007;16:261S-266S.)

In younger patients with arthrosis of the shoulder, palliative and reconstructive options are available before implant arthroplasty; however, some clinical conditions of the glenohumeral joint require arthroplasty in a younger age group. The potential problems with polyethylene on the glenoid side will become a reality in the younger age group.^{14,15} This is due to their longer life span, the higher activity level, and greater demands placed on the shoulder in patients younger than 50 years old.

Hemiarthroplasty is an option that avoids polyethylene wear and potential osteolysis or aseptic glenoid loosening. Hemiarthroplasty has been an option when glenoid cartilage wear is minimal and the glenoid has a congruent surface.^{7,13,16} If the surface is not congruent, hemiarthroplasty can create progressive erosion of cartilage and bone on the glenoid surface.^{3,6-8} This is associated with pain, motion loss, and declining function. In the younger age population, hemiarthroplasty has exhibited loss of joint space within 3 years.¹⁰

In patients with bipolar disease (both the humerus and glenoid involved), total shoulder arthroplasty (TSA) has been an excellent operation for pain relief and functional improvement. Compared with hemiarthroplasty, TSA has been superior in the areas of pain relief and active range of motion.^{3,6,8,12} In patients younger than 50 years of age, however, TSA has shown high glenoid loosening rates and declining survival after 5 to 8 years. At longer follow-up, more than 50% were graded unsatisfactory.^{14,15} Thus, biologic interpositional arthroplasty on the glenoid has been used to avoid the problems with polyethylene in younger, higher-demand populations.

From Midwest Orthopaedics at Rush, Rush University Medical Center.

Reprint requests: Gregory P. Nicholson, MD, Midwest Orthopaedics at Rush, 1725 W Harrison, Suite 1063, Chicago, IL 60612. (E-mail: Orthonick@comcast.net).

Copyright © 2007 by Journal of Shoulder and Elbow Surgery Board of Trustees.

1058-2746/2007/\$32.00

doi:10.1016/j.jse.2007.03.003

Interposition arthroplasty is not a new concept in the shoulder. Soft-tissue interposition on the glenoid side has been described using anterior capsule, fascia lata, tendo Achilles allograft,^{4,9} and recently, lateral meniscus allograft.^{1,2,11} Burkhead et al⁹ have reported pain relief and the ability to perform work force activity without the risk of polyethylene wear with interposition glenoid arthroplasty. The early results with anterior capsule and fascia lata were inferior to those with allograft tendo Achilles. Even with the thicker tendo Achilles allograft, the authors reported glenoid erosion that averaged 7.2 mm and stabilized at approximately 5 years postoperatively. The average joint space on the true anteroposterior (AP) view averaged 1.3 mm.⁹ Yamaguchi et al,^{1,2} first reported the use of lateral meniscal allograft as the interposition material. In a small series of 7 patients, all were satisfied with pain relief at 1 to 5 years of follow-up. The average American Shoulder and Elbow Surgeons (ASES) score at the latest follow-up was 72.^{1,2} The lateral meniscus may have theoretic advantages because of the shape, load-bearing characteristics, and thus durability compared with other interposition materials.

To avoid the potential problems with polyethylene in a population of patients aged younger than 52 years undergoing TSA, we used lateral meniscus allograft (LMA) as a biologic resurfacing of the glenoid. This article reports the short-term results of this technique in a young, active, higher-demand population.

MATERIALS AND METHODS

Thirty patients (20 men, 10 women), with an average age was 42 years (range, 18 to 52 years) underwent shoulder lateral meniscal allograft (LMA) transplantation. All patients completed a preoperative evaluation that included Visual Analog Pain score (VAS), ASES, Simple Shoulder Test (SST), and the Medical Outcomes Short Form-10 (SF-10). Active and passive range of motion was recorded, and true AP, axillary, and outlet view radiographs were taken.

All patients had an advanced imaging study to more clearly evaluate the osteology of the glenoid and glenohumeral joint pathology. Many patients were referred to our institution with either a computed tomography (CT) scan or magnetic resonance imaging (MRI) having already been performed. If they did not have an advanced imaging study, depending upon the clinical situation and surgeon's preference, a CT scan or MRI was obtained preoperatively. The glenoid wear pattern seen was primarily centralized wear, with usually more posterior joint space loss than anterior loss. Five shoulders had biconcave glenoid contour, 4 had moderate posterior wear, and 3 had mild posterior wear. The humeral head was felt to exhibit posterior subluxation in 9, which exceeded 50% in 2, was 25% to 50% in 4, and less than 25% in 3.

The preoperative mean ASES score was 34.8 (range, 8 to 67). The mean preoperative SST was 3.3 (range, 0 to

10), and the mean preoperative VAS for pain was 6.4 (range, 10 to 3). Mean preoperative active range-of-motion parameters were active forward elevation (AFE), 96° (range, 40° to 170°), and active external rotation (AER), 26° (range, -15° to 50°).

Indications for the surgery were progressive degenerative joint disease (DJD), with bipolar involvement of the humerus and glenoid. The diagnosis or etiology of the arthrosis of the glenohumeral joint was osteoarthritis in 16, arthrosis postinstability surgery in 8, posttraumatic in 4, and a failed open reduction with internal fixation in 2. Twenty-two (73%) of the 30 had previous shoulder surgery: 11 had 1 previous surgery, 5 had 2 surgeries, 3 had 3 surgeries, and 3 had 4 previous surgeries. All patients had good glenoid bone stock, an intact rotator cuff, and a functioning deltoid. Excluded from this series were any patients with previous glenoid implants. No revisions or conversions from hemiarthroplasty to TSA with LMA were included. Only 3 patients were involved with Workers' Compensation claims.

Operative technique

All of the procedures were performed by 1 of the 3 senior authors (GPN, AAR, BJC). All procedures were TSA with metallic hemiarthroplasty of the humerus and LMA transplantation to the glenoid. All procedures were performed through the deltopectoral interval. Humeral side preparation with appropriate soft-tissue releases were performed first. A straight-on approach to the glenoid was accomplished. In standard TSA with polyethylene glenoid component implantation, the labrum is excised. With the LMA technique, we sought to preserve the labrum. It can act as an excellent attachment point for suture fixation of the interposition allograft.

Concentric reaming of the glenoid was performed. By using a smaller sized reamer to begin with, we avoided damaging the labrum. The reaming created a concentric surface, created punctate bleeding for LMA adhesion and healing, and reoriented any glenoid version abnormalities that may have developed. Depending upon the specifics of the chosen implant brand, the goal was to ream the glenoid with the reamer that would correspond to the chosen humeral head implant.

Nonabsorbable sutures were placed through the labrum around the circumference in 6 to 7 points of fixation. If suture anchors were necessary, they were placed in the glenoid rim to add fixation to a weak spot. Transosseous sutures were also used, especially anteriorly if needed. Sutures across the surface of the allograft were avoided. A male lateral meniscus younger than 30 years old was requested to maximize the size of material for coverage of the glenoid surface. There was always an uncovered central area of glenoid. The anterior horns were always placed facing anteriorly, placing the largest, thickest aspect of the LMA posteriorly. This was where the glenoid wear and possible humeral head subluxation almost always was present.

Once the sutures were placed, they were then passed through the periphery of the LMA in the corresponding locations (Figure 1). We preferred to place the horns of the LMA facing anteriorly. The horns were sutured together for stability during peripheral fixation. The meniscus was then

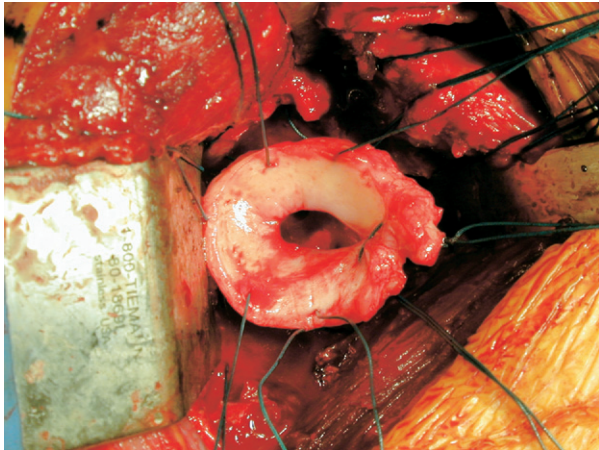


Figure 1 A lateral meniscus allograft (LMA) just before implantation in a right shoulder. Note the 2 horns stabilized together by a suture and the horns facing anteriorly. Note also the around-the-clock arrangement of the sutures in the peripheral edge of the LMA. These sutures have already been placed through the labrum.

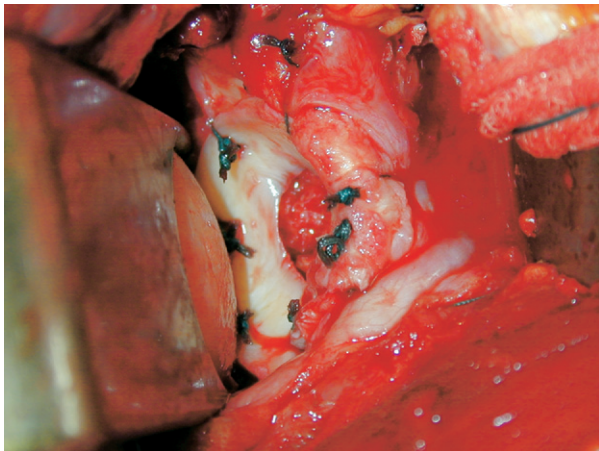


Figure 2 A lateral meniscus allograft (LMA) implanted upon a right glenoid. Note the sutures tied peripherally. The anterior horns have been definitively closed. The LMA interposition resurfaces the glenoid.

sutured down to the glenoid surface (Figure 2). After definitive fixation to the glenoid, the final suturing of the 2 horns was adjusted as needed for stability and sizing. The humerus was carefully dislocated forward and the hemiarthroplasty on the humeral side was performed. Stemmed implants were placed in 26 of the 30 procedures, and 4 had a full coverage resurfacing implant. The shoulder was reduced and the subscapularis repaired. Six patients required subscapularis lengthening. All patients had a long head of biceps tenodesis.

Aftercare

Aftercare did differ between surgeons. One author immobilized the shoulder in a sling with a derotation wedge

attached. This positioned the shoulder in a neutral rotation and placed the humeral head centrally upon the LMA on the glenoid. This immobilization lasted 2 weeks, then the wedge was removed and the sling wear continued for a total of 4 weeks postoperatively. Pendulum exercises were begun at 2 weeks, and active assisted motion and isometrics were begun at 4 weeks.

The other 2 authors in the study group immobilized the shoulders in a simple sling. Pendulum exercises and passive range of motion was begun immediately postoperatively. By 8 weeks, all patients were performing gentle stretching, and active range of motion and resistive strengthening exercises.

Follow-up was obtained at 3, 6, and 12 months and then yearly. The average follow-up was 18 months (range, 12 to 48 months). The patients were evaluated postoperatively by physical examination measuring both active and passive range of motion. True AP and axillary radiographs of the shoulder were also obtained with a 4-mm BB marker affixed to the skin on the lateral deltoid at the level of the glenohumeral joint. This acted as a known size reference to evaluate joint space on the AP and axillary projections. The glenohumeral joint space in millimeters was recorded using the 4-mm BB as the reference.

All patients completed the same shoulder survey, which included VAS, ASES, SST, and SF-10. Finally, the patients' return to work status and overall satisfaction with the procedure were recorded. The data were analyzed by a statistical software package. The Wilcoxon signed ranks test was used to compare preoperative and postoperative parameters.

RESULTS

All postoperative outcome parameters had statistically significant improvements from preoperative values ($P < .02$). The mean scores were ASES, 69 ± 31 (range, 25 to 100); SST, 7.8 ± 4.5 (range 2 to 12), and VAS pain score, 2.3 ± 4.1 (range, 7 to 0). The AFE increased to 139° (range, 80° to 180°) and the AER increased to 53° (range, 30° to 78°). With regard to satisfaction, 94% would have the surgery again.

Twenty-six of the 30 patients were improved from preoperative status; however, 4 patients were not improved from the procedure. This was due to infection in 1, LMA tearing with removal in 1, and progressive pain and glenoid wear with LMA displacement in 2.

No difference in the results was noted with regard to gender, preoperative diagnosis, number of previous surgeries, or the degree of glenoid wear or subluxation. There was a trend for an adverse occurrence correlated with the aftercare. In the patients that were immobilized in the derotation wedge for 2 weeks, and then begun on slow, progressive range-of-motion exercises, no early LMA failures occurred requiring revision. The early active and passive range-of-motion patients in a sling did have 3 early LMA failures requiring reoperation.

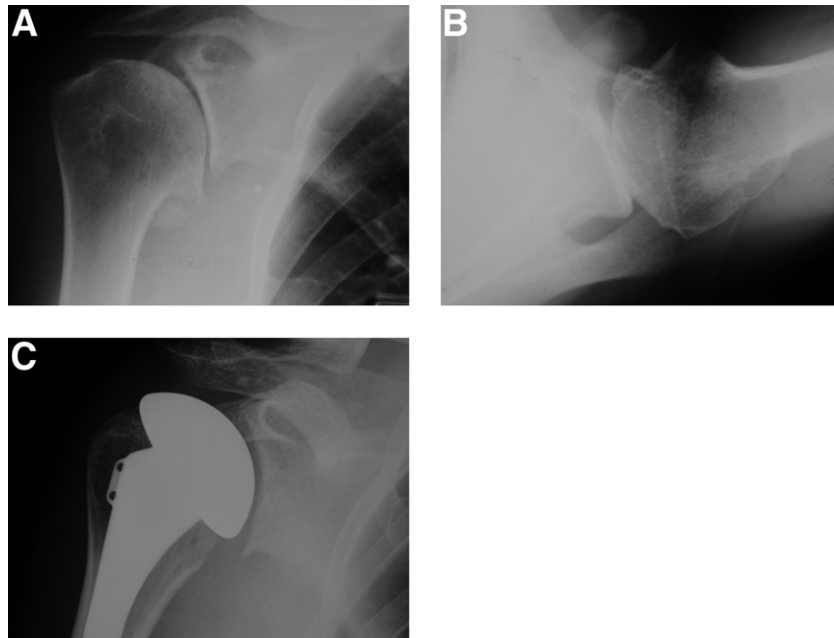


Figure 3 **A**, A true anteroposterior (AP) view of a right shoulder with advanced shoulder degenerative joint disease. There is loss of joint space and marginal osteophytes. **B**, An axillary view of the same shoulder reveals bone-on-bone contact and very mild posterior subluxation of the humeral head on the degenerative glenoid. **C**, A true AP radiograph of a right shoulder 1 year after total shoulder arthroplasty with a lateral meniscus allograft. The joint space has been maintained and is symmetric.

Radiographic analysis at 1 year revealed the average joint space was 1.8 mm on the AP projection and 1.6 mm (range, 0 to 4 mm) on the axillary view (Figure 3, A-C). The postoperative radiographs were usually performed within 7 to 14 days after surgery. In none of the postoperative radiographs was the joint space less than 1 mm. The average joint space was 2.4 mm on AP and 2.2 mm on the axillary view (range, 1 to 6 mm). This did not constitute a significant loss space with the number of patients and values recorded at 1 year. In this short-term study, no patient has exhibited posterior humeral head subluxation, and no glenoid bone erosion has occurred.

Complications

Reoperation was required for 5 complications (17%), all of which occurred within the first year of surgery. Two patients who experienced early pain and loss of motion. The shoulder dysfunction was not due to infection, and the joint space was 0 mm. They were revised to a polyethylene glenoid component. The LMA did not have glenoid coverage at reoperation. A third patient experienced similar symptoms and clinical course. He had an early injury to the shoulder while pushing down on the arm before 6 weeks postoperatively. The LMA had displaced and was excised. A glenoid component was not im-

planted. One deep infection required incision and drainage and removal of all implants.

The other complication occurred after 6 months. At 6 months, there was no pain, 160° of AFE and 60° of AER. At 9 months, the patient presented with a deep venous thrombosis of unknown etiology in the nonoperative upper extremity. The patient was taking Coumadin (Bristol-Myers Squibb, Princeton, NJ). The patient was now also complaining of pain and loss of motion in the previously well-functioning shoulder. No infection was evident. AP radiographs showed mild joint space loss; the joint space was 2 mm. Therapy for gentle stretching and range of motion was initiated. By 11 months, however, the AFE was 90° and the AER was 20° with pain. An arthroscopic capsular release and débridement was performed. At the time of surgery, the LMA was not a distinct structure, and the ragged rim of tissue was débrided. There was, however, no exposed bone on the glenoid surface. The patient has mild-to-moderate pain, AFE to 130°, and AER to 40° 3 years postarthroplasty, 2 years postrelease.

DISCUSSION

This is a short-term report on a difficult patient population. This is a younger population with high

activity levels and still in the work force. All patients in this series had bipolar disease of the shoulder, meaning that the glenoid and humeral surfaces were significantly involved. The arthroplasty options were determined to be hemiarthroplasty, TSA with a polyethylene glenoid component, or TSA with biologic glenoid arthroplasty.^{2,11} All patients had an intact rotator cuff, functioning deltoid, and good glenoid bone stock.

TSA and hemiarthroplasty have shown the ability to relieve pain in the younger patient population. It is obviously the issue of longevity in the young patient that affects the treatment choice. With longer-term follow-up in patients younger than 50 years of age, Sperling et al^{14,15} reported a 68% rate of radiographic glenoid erosions in hemiarthroplasty. This did affect pain and outcome scores. Those with TSA and polyethylene glenoids had up to a 59% glenoid lucency rate. Both treatment options in younger patients had an unsatisfactory rating of more than 50% after 5 years.^{14,15} In a recent study, these authors evaluated hemiarthroplasty for osteoarthritis at a minimum of 5 years. The average age of this study group was 39 years old. They found that age was a significant variable: the older the patient, the less chance of revision. The younger patients were at risk, and 9 of 51 required revision to TSA due to painful glenoid erosion. By Neer criteria, 21 of 51 were unsatisfactory.¹³ This report shows the potential problems with hemiarthroplasty alone in a young, active population.

Wirth et al,¹⁶ in a recent minimum 5-year follow-up study, showed that hemiarthroplasty can provide stable results. The status of the glenoid did require intraoperative decision-making for TSA versus hemiarthroplasty. The amount of preoperative glenoid bone erosion and subluxation did affect outcome results. The improvement in the outcome parameters seemed durable, and glenoid bone erosion averaged only 2 mm at 5 years. The average age of this study population, however, was 63 years old, much older than our current study.¹⁶ As was seen with previous studies in younger patient populations, with either hemiarthroplasty or TSA, there are risks of glenoid side wear issues compromising the result. Our study is obviously a short-term evaluation. However, there is very little in the peer-reviewed literature with regard to alternative (biologic) bearing surfaces for the glenoid in young patients requiring arthroplasty for shoulder DJD.

If an uninvolved glenoid surface or a minimally involved glenoid surface is encountered, we agree that hemiarthroplasty is the best option in some patients. With a concentric glenoid surface, it has shown consistent early results.^{7,13,16} However when those same patients were followed up for a longer time, the results were compromised by progressive glenoid side wear.^{7,13} Even with concentric glenoids with cartilage remaining, longer follow-up has shown pro-

gressive joint space loss,¹⁰ bone erosion,^{7,12,13} and diminution of the result. In our series, there were no cases of minimally involved glenoid surfaces, and arthroplasty of both sides of the joint was thus appropriate. To avoid the potential complications of polyethylene wear, component loosening, cement fragmentation, and bone loss in younger patients, we used the LMA glenoid resurfacing in TSA. A detailed discussion of the options and concerns was undertaken with all patients in the series before surgery.

Interposition arthroplasty of the glenoid has used differing materials. Most reports have been preliminary reports on the technical details¹ or included a small number of patients.⁴ Burkhead et al^{4,9} raised the awareness of biologic resurfacing of the glenoid in younger patients with a promising early series using local capsular interposition. Fascia lata and tendo Achilles have been advocated as appropriate interposition material.^{4,9} A longer-term evaluation by Burkhead et al⁹ showed promising durability of the biologic interposition technique.

The LMA was discussed by Yamaguchi et al^{1,2,11} as a possible choice for glenoid biologic resurfacing. It makes intuitive sense in that it is a load-bearing and load-sharing structure. A study on contact area and pressure on the glenoid showed that the LMA interposition increased the area of contact and decreased force transmission from the humeral head to the native glenoid surface.⁵ The LMA is similar in size and shape to the glenoid surface. The LMA has thus been used in the younger, active population for biologic resurfacing in TSA; however, this has not been reported on in larger series.

In this series, the LMA glenoid biologic resurfacing in TSA provided significant pain relief, range-of-motion improvement, and patient satisfaction. It was not a perfect solution. The complication rate and reoperation rate was a sobering 17%, all of which occurred within the first year. This is a higher reoperation rate than we experience with TSA or hemiarthroplasty alone. However, the satisfaction rate and outcome score in young patients requiring arthroplasty, as can be seen from the studies presented, is not optimal. The biologic interposition is a technique to attempt to improve on those results. Three of the 5 complications were directly related to the LMA either displacing or to possible tearing. It may be that these 3 cases were related to aftercare. Early active and passive motion was instituted in those 3 patients. In the surgeon group that immobilized the shoulder for 2 to 3 weeks in a derotation wedge, no cases of early LMA failure occurred. The aftercare for all LMA cases in our practice has incorporated a delay in starting motion of 2 to 3 weeks to allow for early adhesion of the LMA to the reamed glenoid bone surface.

Beyond the early failure of the interposition, is the issue of longevity. Does the LMA material hold up and

provide and maintain a joint space? Radiographs revealed that a narrowing of the joint space occurs over time, but at 1 year, on average, there was 1.6 mm of joint space. This seemed to remain stable and did not have a detrimental affect on function and pain, as was reported by Parsons.¹⁰ Longer-term follow-up radiographs correlated with pain and function will be needed to evaluate stability or progression of joint space with the LMA technique.

The technique used included reaming the glenoid surface to create concentricity and a punctate bleeding surface. This preserved the labrum for LMA attachment along with using supplementary transosseous sutures or anchors as needed. A male LMA aged younger than 30 years was requested. Variables that are unknown at this time are the effect of rewarming on the LMA material properties, effect of age of the allograft from harvest, possible antigenic responses, and the healing potential of the allograft to host bone and peripheral tissue. We also do not know the optimal fixation technique or positioning of the allograft upon the glenoid. As report in this series, there may be early material issues that can be avoided with aftercare restrictions.

CONCLUSION

In this series of younger shoulders with progressive shoulder DJD, most having had some form of prior shoulder surgery, the LMA was used to biologically resurface the glenoid. Most patients were in the workforce and had high functional demands. Most problems presented within the first year postoperatively. Even with these early complications and unresolved issues, the LMA in the younger, highly active patient population requiring TSA shows promise. Although not perfect, it provided significant pain relief, range-of-motion gains, and patient satisfaction without the risk of polyethylene wear or loosening. Longer-term follow-up will be required to determine if these results will be durable over time.

REFERENCES

- Ball C, Galatz L, Yamaguchi K. Meniscal allograft interposition arthroplasty for the arthritic shoulder. Description of a new surgical technique. *Tech Shoulder Elbow Surg* 2001;2:247-54.
- Baumgarten KM, Lashgari CJ, Yamaguchi K. Glenoid resurfacing in shoulder arthroplasty: Indications and contraindications. *Instr Course Lect* 2004;53:3-11.
- Bryant D, Litchfield R, Sandow M, Gartsman GM, Guyatt G, Kirkley A. A comparison of pain, strength, range of motion, and functional outcome after hemiarthroplasty and total shoulder arthroplasty in patients with osteoarthritis of the shoulder. *J Bone Joint Surg Am* 2005;87:1947-56.
- Burkhead WZ Jr, Hutton KS. Biologic resurfacing of the glenoid with hemiarthroplasty of the shoulder. *J Shoulder Elbow Surg* 1995;4:263-70.
- Creighton RA, Cole BJ, Nicholson GP, Romeo AA, Lorenz EP. Effect of lateral meniscus allograft on shoulder articular contact areas and pressures. *J Shoulder Elbow Surg* 2007 in press.
- Gartsman GM, Roddey TS, Hammerman SM. Shoulder arthroplasty with or without resurfacing of the glenoid in patients who have osteoarthritis. *J Bone Joint Surg Am* 2000;82:26-34.
- Levine VN, Djurasovic M, Glasson JM, Pollock RG, Flatow EL, Bigliani LU. Hemiarthroplasty for glenohumeral osteoarthritis: results correlated to degree of glenoid wear. *J Shoulder Elbow Surg* 1997;6:449-54.
- Lo IK, Litchfield RB, Griffin S, Faber k, Patterson SD, Kirkley A. Quality-of-life outcome following hemiarthroplasty or total shoulder arthroplasty in patients with osteoarthritis. A prospective, randomized trial. *J Bone Joint Surg Am* 2005;87:2178-85.
- Nowinski RJ. Newark OH, Burkhead WZ Jr. Hemiarthroplasty with biologic glenoid resurfacing: 5-13 year outcomes. In: Boileau P, editor. *Shoulder arthroscopy & arthroplasty. Current concepts*. Montpellier, France: Sauramps Medical; 2004. p. 354-60.
- Parsons IM, Millett PJ, Warner JJP. Glenoid wear after shoulder hemiarthroplasty: quantitative radiographic analysis. *Clin Orthop* 2004;421:120-5.
- Pearl ML, Romeo AA, Wirth MA, Yamaguchi K, Nicholson GP, Creighton RA. Decision making in contemporary shoulder arthroplasty. *Instr Course Lect* 2005;54:69-85.
- Pfahler M, Jena F, Neyton L, Sirveaux F, Mole D. Hemiarthroplasty versus total shoulder prosthesis: Results of cemented glenoid components. *J Shoulder Elbow Surg* 2006;15:154-63.
- Rispoli DM, Sperling JW, Athwal GS, Schleck CD, Cofield RH. Humeral head replacement for the treatment of osteoarthritis. *J Bone Joint Surg Am* 2006;88:2637-44.
- Sperling JW, Cofield RH, Rowland CM. Neer hemiarthroplasty and Neer total shoulder arthroplasty in patients fifty years old or less: long term results. *J Bone Joint Surg Am* 1998;80:464-73.
- Sperling JW, Cofield RH, Rowland CM. Minimum fifteen-year follow-up of Neer hemiarthroplasty and total shoulder arthroplasty in patients fifty years or younger. *J Shoulder Elbow Surg* 2004;13:604-13.
- Wirth MA, Tapscott RS, Southworth C, Rockwood CA Jr. Treatment of glenohumeral arthritis with a hemiarthroplasty: a minimum five-year follow-up outcome study. *J Bone Joint Surg Am* 2006;88:964-73.