

Indian J Orthop. 2013 Mar-Apr; 47(2): 143–149.
doi: [10.4103/0019-5413.108892](https://doi.org/10.4103/0019-5413.108892)

PMCID: PMC3654463

Arthroscopic management of recalcitrant stiffness following rotator cuff repair: A retrospective analysis

Sanjeev Bhatia, Richard C Mather, III,¹ Andrew R Hsu, Amon T Ferry,² Anthony A Romeo, Gregory P Nicholson, Brian J Cole, and Nikhil N Verma

Division of Sports Medicine, Department of Orthopaedic Surgery, Rush University Medical Center, Chicago, IL, USA

¹Division of Sports Medicine, Department of Orthopaedics, Durham, NC, USA

²Division of Sports Medicine, Department of Valley Orthopaedics, Phoenix, AZ, USA

Address for correspondence: Dr. Nikhil Verma, 1611 West Harrison Street, Suite 203, Chicago, IL 60612, USA. E-mail: nverma@rushortho.com

Copyright : © Indian Journal of Orthopaedics

This is an open-access article distributed under the terms of the Creative Commons Attribution-Noncommercial-Share Alike 3.0 Unported, which permits unrestricted use, distribution, and reproduction in any medium, provided the original work is properly cited.

Abstract

Background:

Rotator cuff repair surgery is one of the most commonly performed procedures in the world but limited literature exists for guidance of optimal management of post-operative arthrofibrosis following cuff repair. The purpose of this study is to report the results of arthroscopic capsular release, lysis of adhesions, manipulation under anesthesia, and aggressive physical therapy in patients with recalcitrant postoperative stiffness after rotator cuff repair.

Materials and Methods:

Twenty-nine patients who had recalcitrant arthrofibrosis following either an arthroscopic (62%), open (28%), or mini-open (10%) rotator cuff repair were included in study. The average age at the time of index cuff repair surgery was 49.8 years (range 24–70 years). Sixteen patients (55%) were involved in worker's compensation claims. The mean time from the date of index operation to lysis of adhesions was 9.7 months (range 4.2–36.2 months), and the mean time from lysis of adhesion to most recent follow-up 18.2 months (range 4.1–43.7 months). Post-operative evaluation was performed using American Shoulder and Elbow Surgeons Score (ASES), Visual Analog Score (VAS), Single Assessment Numeric Evaluation (SANE), and Simple Shoulder Test (SST) on 18 (62%), while range of motion (ROM), dynamometer strength testing, and Constant-Murley Scoring were performed on 13 (45%). Statistical analysis was performed using a Student's *t*-test.

Results:

Prior to arthroscopic lysis of adhesions, mean forward active elevation (FE) was 103.8°, (range 60–145° (SD 26.3) and external rotation at the side (ERS) was 25.3°, (range 5–70° SD 15.1°). Post-operatively, at the most recent follow-up, FE was significantly improved to 158.3°, (range 110–180° SD 22.3°), and ERS improved to 58.9°, (range 15–90° SD 18.6°) in both cases. Involvement in a worker's compensation claim resulted in a lower ASES, VAS, and SANE score, but there was no statistically significant difference in motion.

Conclusion:

Arthroscopic capsular release, lysis of adhesions, and manipulation under anesthesia is a safe, reliable method of treating persistent stiffness following rotator cuff repair.

Keywords: Arthroscopic lysis, stiffness, rotator cuff repair

INTRODUCTION

Rotator cuff pathology is the most common cause of shoulder pain in patients over the age of 50 with an incidence of roughly 3.7 per 100 000 and a mean age of 47.5 years in men and 57.2 years in females.¹ Results of both open and arthroscopic rotator cuff repairs are generally good leading to predictable pain relief, increased function, and patient satisfaction.²⁻⁵ Factors that are commonly associated with a poorer outcome following rotator cuff repair include age, gender, smoking status, and tear size.⁶ Additionally, it has been suggested that tendon repair integrity⁷ and workman's compensation status⁸ may also affect the surgical outcome. Post-operative arthrofibrosis of the shoulder is a known complication of both open and arthroscopic surgery and is believed to most commonly result from an intra-articular inflammatory process that leads to thickening and fibrosis of the joint capsule.^{9,10} Risk factors for stiffness following rotator cuff repair (RCR) have been suggested and include diabetes, pre-operative decreased range of motion (ROM), involvement of the subacromial bursa, and arthroscopic findings consistent with adhesive capsulitis.^{11,12} In addition, both technical factors such as inadequate release, over tensioning, and rotator interval closure, as well as an inadequate post-operative protocol have been cited as variables contributing to the development of arthrofibrosis.¹³

The treatment of postoperative arthrofibrosis can be difficult as healing of the rotator cuff requires protected motion and includes both nonoperative and operative modalities. When compared with idiopathic arthrofibrosis, nonoperative treatments such as physical therapy,¹³⁻¹⁵ intra-articular injections,^{13,15} or brisement^{15,16} may not be as successful in treating post-operative stiffness. Surgical treatment in the form of an arthroscopic capsular release in addition to a manipulation under anesthesia has been found to be successful in regaining a functional ROM^{3,15,17,18} for multiple etiologies.^{19,20}

It is our belief that manipulation under anesthesia and arthroscopic capsular release followed by an intense therapy protocol is a safe and effective method to treat post-operative stiffness that is refractory to nonoperative measures. Arthroscopic management of shoulder stiffness is preferred because it allows optimal visualization and release of the glenohumeral joint and subacromial space without the added trauma to extra-articular structures, thus allowing immediate full active and passive range of motion (ROM). The purpose of this study is to report our technique and results of patients undergoing arthroscopic capsular release for the treatment of shoulder stiffness following either arthroscopic, mini-open, or open RCR surgery. Our hypothesis is that arthroscopic management of stiffness following RCR would result in significantly improved ROM and improvement in validated outcome measures.

MATERIALS AND METHODS

A retrospective review of all patients at our institution who underwent arthroscopic lysis of adhesions, capsular release, and manipulation under anesthesia for the treatment of arthrofibrosis following either an arthroscopic, open, or mini-open RCR were identified from July 2004 to April 2007. Typically in our practice, patients must demonstrate suitable PROM prior to undergoing the index RCR surgery; thus, the shoulder stiffness that developed mostly occurred post-operatively. Inclusion criteria were that patients required surgical treatment of shoulder stiffness following a RCR with a minimum of 3-month followup during which time nonoperative measures were exhausted. Nonoperative measures typically consisted of aggressive physical therapy, oral corticosteroids (4 day tapering Methylprednisolone regimen – Medrol Dosepak - beginning at 24 mg and ending at 4 mg), and in all cases, intra-articular steroid injections. We excluded two patients who required additional surgical procedures other than capsular release. One

excluded patient was found to have diffused bipolar glenohumeral chondromalacia at the time of arthroscopic capsular release and was ultimately treated with a total shoulder arthroplasty. The other excluded patient underwent a glenohumeral fusion after sustaining a chronic anterior glenohumeral dislocation. Of note, the only glenohumeral dislocation and failed RCR in this series occurred in this patient. Any patient requiring an additional capsular release was included, but considered a failure.

The study group consisted of 29 patients: 18 arthroscopic (62%), 8 open (28%), and 3 mini-open (10%) repairs. The average age at the time of index operation was 49.8 (range 24–70, SD 11), 18 patients (62.1%) were male, the dominant extremity was involved in 20 (69.0%), and 16 (55%) were involved in workman's compensation claims. The average number of months from the date of index operation to lysis of adhesions was 9.7 months (range 4.2–36.2, SD 6.9), and from lysis of adhesion to most recent followup 18.2 months (range 4.1–43.7, SD 13) [Table 1].

Data were obtained retrospectively by chart review, phone interviews, and followup examination when available. Full approval from our institutional review board was achieved prior to embarking on the study. Consent was obtained from all individuals who participated in the study follow-up examination and phone surveys. The patients completed validated, clinical outcome scores including Constant-Murley score, Single Assessment Numeric Evaluation (SANE), American Shoulder and Elbow Surgeons Score (ASES),²¹ Simple Shoulder Test (SST),²² and Visual Analog Pain scale (VAS). Thirteen patients (45%) returned for a final followup examination during which shoulder ROM and dynamometer strength measurements were measured by an independent examiner. Forward elevation in the scapular plane and external rotation with the arm at the side were measured with a goniometer. The shoulder strength was measured using a manual muscle dynamometer (Lafayette Manual Muscle Test System, Lafayette Instrument Company, Lafayette, IN) in forward elevation and external rotation. In patients not available for final independent follow-up, ROM data from their most recent clinical follow-up were recorded. Three patients refused to be included in the study due to ongoing litigation of their worker's compensation claim. Eight patients were lost to the followup. The operative report was reviewed in all cases to determine status of the cuff repair at the time of capsular release.

Statistical analysis

Descriptive analysis consisted of frequencies and percentages for discrete data and means and standard deviations for continuous data. Statistical analysis (GraphPad Inc., La Jolla, CA) was done using a Student's *t*-test to compare pre-operative ROM with corresponding post-operative measurements on the same patient. *P*-value of less than 0.05 was considered to be statistically significant. In scenarios in which pre-operative and post-operative assessments were not available for the same patient, *P*-values were not calculated but descriptive statistics have been provided for comparison with other reports in the literature.

Operative procedure

All patients underwent extensive nonoperative treatment including home and supervised physical therapy emphasizing PROM exercises for at least 3 months prior to operative capsular release. Indications for operative treatment of post-operative stiffness in these patients were greater than 3 months of failed nonoperative treatment and a deficit of at least 30° in either abduction or external rotation when compared to the contralateral shoulder.

An arthroscopic capsular release was performed in each case by one of the four senior surgeons under regional anesthesia. After being anesthetized, the patient was placed in the lateral or beach-chair position. An examination under anesthesia was then performed to assess pre-operative PROM of the operative and contralateral shoulder in forward elevation and external rotation at the side with care to stabilize the scapula. The posterior portal was then established and a 30° arthroscope was introduced into the glenohumeral joint. Initially, the standard anterosuperior portal was established as the working

portal using a 7-mm cannula just lateral to the coracoid entering the glenohumeral joint in a triangle bordered by the glenoid rim, the upper border of the subscapularis and the biceps tendon [Figure 1a].

Routine diagnostic arthroscopy was then performed from the posterior portal with care to note any evidence of a thickened fibrotic capsule anteriorly. After confirming the diagnosis, an anterior capsular release was completed starting at the rotator interval using either a motorized 4.0 shaver (Arthrex, Naples, FL) [Figure 1b] or a radiofrequency device (RF) [Figure 1c]. We used a 3.0-mm 90° Arthrowand (Arthrocare, Sunnyvale, CA) as our preferred RF tool. Care was taken to completely release the interval in order to allow for increased mobility, thereby facilitating further capsular release inferiorly. The anterior capsule was then released along the glenoid rim in a similar fashion with care to protect the labrum and subscapularis tendon. An arthroscopic biter was used in some portions to protect nearby structures [Figure 1d]. The release was then carried around the anteroinferior glenoid rim to the 6 o'clock position with care to direct the device away from the axillary nerve [Figure 1e].

Following anterior release, the arthroscope was then placed in the anterior portal and the posterior capsule was evaluated. The posterior capsule tends to be thinner and more compliant, but if deemed necessary, can also be released. In these instances, the RF was placed in the posterior portal and a posterior capsular release was performed beginning in the posterosuperior recess and extending to the previously released anterior capsule. With the capsule released circumferentially, the arthroscope was removed. With the scapula stabilized, the shoulder was then manipulated, first in forward flexion with care to direct the force along the humerus to avoid trauma to the elbow, and then in both external and internal rotation in 90° of abduction. Post-operative motion was then examined to determine if the extent of release was sufficient. In most cases, further release was not necessary. Subacromial decompression was also not performed to release adhesions between the rotator cuff and acromion.

In the post anaesthesia care unit (PACU), while the regional block was in effect, the patient was shown his or her PROM. This was primarily done to ensure that the patient understood that full ROM was attainable. A discussion about the necessity of aggressive PT had this time.

Postoperative protocol

Physiotherapy was started on the first post-operative day with emphasis on aggressive active and PROM in addition to scapular stabilization and cuff strengthening. Although some patients performed therapy at a peripheral center, the prescribed therapy regimen was fairly uniform for all patients. Continuous passive motion devices were utilized for 4 weeks postoperatively and sling immobilization was immediately discouraged.

RESULTS

The mean duration of follow-up of 18.2 months, (range 4.1–43.7 months, SD 13.1 months) for all patients involved in this study ($n = 29$). This group of patients demonstrated a statistically significant increase ($P < 0.0001$) in shoulder motion in forward elevation and external rotation following arthroscopic capsular release [Table 2a and Figure 2]. Preoperatively, mean forward elevation (FE) was 103.8°, (range 60°–145° SD 26.3°) and external rotation at the side (ERS) was 25.3°, (range 5°–70° SD 15.1°). Post-operatively, at the most recent followup, mean FE significantly improved to 158.3°, (range 110°–180° SD 22.3°, $P < 0.0001$), and ERS improved to 58.9° (range 15°–90° SD 18.6°, $P < 0.0001$).

We also compared shoulder scores (ASES, CM, VAS, SANE, and SST). Postoperative mean scores were as follows: ASES was 75.5, (range 36.7–100, SD 23.5), CM was 68.9, (range 30.9–80.9, SD 16.0), VAS was 2.5, (range 0–9, SD 2.9), and SANE was 80.3 (range 50–100, SD 18.7). There were insufficient pre-operative shoulder scores to permit a direct comparison. Additionally, we analyzed the results based on the technique of index RCR (open, mini-open, or all arthroscopic) and found no statistically significant difference with regards to postoperative motion or validated shoulder scores ($P > 0.05$).

Thirteen patients were available for an independent follow-up appointment at a mean of 24.6 months, (range 8.7 – 40.3 months, SD 10.0) at which time we obtained subjective shoulder scores and a physical examination consisting of ROM and dynamometer strength testing. For this group, pre-operative motion measured 104.6° of FE, (range 75 – 140, SD 25.5) and 25.0° of ERS, (range 5 – 40, SD 11.7). Postoperatively their motion measured a mean of 157.0° of FE, (range 110–180, SD 28.3) and 60.0° of ERS, (range 15 – 90, SD 23.0), [Table 2b]. These results were also statistically significant ($P \leq 0.0001$). Sixteen of the 29 patients were treated under a worker's compensation claim [Table 3]. There was no statistically significant difference in final ROM across these groups ($P > 0.05$, Figure 3a). There was, however, a statistically significant difference between the post-operative VAS ($P < 0.05$), ASES ($P < 0.01$), and SANE ($P < 0.001$) scores [Figure 3b].

There was one failure that required a revision arthroscopic capsular release, lysis of adhesions, and manipulation under anesthesia due to recurrent stiffness 17 months after first capsular release. There was one post-operative dislocation but no deep infections or nerve injuries.

DISCUSSION

Arthroscopic capsular release has been shown to be a safe and reliable method for restoring shoulder motion for treatment of idiopathic, surgical, or post-traumatic stiffness.^{19,20} The principal results of this study demonstrate that forward elevation and external rotation of the shoulder at the side can be significantly improved—although with varied results—in patients with recalcitrant postoperative stiffness after RCR following arthroscopic capsular release, lysis of adhesions, manipulation under anesthesia, and aggressive physical therapy. Previous studies have largely included small subsets of patients in each of these etiologic categories.¹⁹ To the best of our knowledge, our study represents one of the largest cohort of patients treated with arthroscopic capsular release for shoulder stiffness following a rotator-cuff repair.^{9,11,23,24}

In our clinical experience with shoulder stiffness, we have found that loss of shoulder motion, when compared to the contralateral, shoulder, occasionally occurs following RCR, particularly in patients less compliant with post-operative rehabilitation. If identified early in the post-operative period, treatment with aggressive PROM can be successful in restoring satisfactory motion. This form of treatment, however, is less likely to be beneficial when the patient is 12 weeks or more out from surgery; thus, we believe that persistent post-operative stiffness refractory to conservative management for 3 months would be an indication for an arthroscopic capsular release and manipulation under anesthesia. Arthroscopic capsular release may have the advantage of decreased morbidity and uncomplicated rehabilitation.²³ Patients can safely be accelerated in an aggressive active and PROM therapy protocols. Further study is necessary to elicit the risk factors associated with failed non-operative treatment and the timing of surgery to optimize treatment of this problem.

Warner *et al.* in 1997 previously published a series of 18 patients with postoperative shoulder stiffness that was treated with arthroscopic release in 16 of the 18 patients.¹² This series included patients that had been treated with several different surgical procedures but only four patients had undergone a RCR. He reported an increase in CM scores and a significant increase in all directions of motion and concluded that arthroscopic capsular release is a reliable method for restoring motion with minimal morbidity. He also noted that nonoperative treatment of post-operative stiffness, including manipulation under anesthesia, is generally ineffective.

Several studies have reported the results of arthroscopic capsular release for treatment of shoulder stiffness based on multiple different etiologies (idiopathic, post-injury, and post-surgical).^{15,18–20} These results were similar to those found by Warner in that these patients did have significant increases in motion and function following arthroscopic capsular release. However, when the groups were further

analyzed, the patients with idiopathic stiffness did better than those with postoperative stiffness. Each study, however, had relatively few patients who had postoperative stiffness after RCR.

One unique aspect of this study is the relatively large percentage of worker's compensation patients. Historically, it has been suggested that this patient population is less likely to have a good outcome and return to a pre-injury level of function.^{8,25} Previous studies reporting the outcome of RCR in patients involved with worker's compensation claims have shown significantly worse outcome in those patients involved in worker's compensation claims.^{8,25} It has also been suggested that the worker's compensation patients have certain demographic characteristics such as lower education level, smoking, and heavy manual labor that places them at risk for failure.²⁶ In our study, we did not find a significant difference in post-operative motion for those patients involved in worker's compensation claims. We did, however, find a significant difference in the shoulder scores that consisted solely of subjective reports, the VAS, ASES, and SANE. This suggests that although increasing the functional ROM, the primary goal of the operation, was similar to patients not involved with a worker's compensation claim, those in the worker's compensation group did complain of more pain and perceived their outcome worse than the nonworker's compensation group. These differences reflect many challenges; one is faced with treating a patient with a work-related injury, and suggests that an arthroscopic capsular release in this group can be successful in restoring a functional ROM. Nonetheless, one should be cautious when counseling the patient preoperatively as their perceived outcome may not be as good as those not involved in a worker's compensation claim.

There are several weaknesses of our study. First, this is a retrospective case series with no control group and only 13 patients available for independent examination at a follow-up examination. We believe that this was lower than expected rate of final follow-up and was related to the fact that 55% of our patients had worker's compensation injuries and were either unable to be contacted or refused followup interviews due to ongoing legal issues. Additionally, as a large referral center, 13 of the patients in this study were referred in for treatment and many returned to their home physician for postoperative followup. In fact, five of the eight patients lost to followup were originally treated at an outside institution. Although we examined the clinical outcomes of patients based on technique of the index procedure, there were only three patients in the mini-open group and eight patients in the open group leaving these groups underpowered. Moreover, the sample group involved patients who had undergone arthroscopic, mini-open, and open cuff repair procedures. Given the relatively low incidence of postoperative arthrofibrosis requiring surgical release, to achieve a suitably sized cohort it was necessary to group both open and arthroscopic cuff repair patients as well as along with workers compensation patients. Lastly, limited ROM measurements were collected. Internal rotation is often notably decreased with postoperative stiffness and future studies—ideally performed at multiple centers—should have more comprehensive ROM measurements.

In this study, we report the results of patients treated with an arthroscopic capsular release, lysis of adhesions, and manipulation under anesthesia for the treatment of shoulder stiffness following RCR. This combination of procedures represents a safe and reliable means to regain shoulder motion, specifically FE and ERS, after the onset of post-operative shoulder arthrofibrosis that is recalcitrant to conservative measures. Furthermore, no significant differences in outcome existed based on whether the index surgery was performed open, mini-open, or arthroscopic. Worker's compensation status resulted in lower validated outcome measures, but no difference in ROM.

Footnotes

Source of Support: No grants or outside funding was utilized in this project

Conflict of Interest: One or more of the authors has declared a potential conflict of interest: Dr Romeo has received research or institutional support, miscellaneous funding, royalties, a consultant or employee of Arthrex; Dr Verma has received research or institutional support and is a consultant or employee of Smith and Nephew; Dr Cole has received

research or institutional support and royalties and is a consultant or employee of Arthrex, has received research or institutional support and miscellaneous funding and is a consultant or employee of Genzyme, and has received research or institutional support and is a consultant or employee of Zimmer; Dr Nicholson has received research or institutional support from EBI, has received royalties and stock options and is a consultant or employee of Zimmer, and has received royalties from Innomed. NNV, SJN, BJC, GPN, AAR have received institutional support from Arthrex, Inc; DJ Orthopaedics; Ossur; Smith and Nephew; Miomed; Athletico; Linvatec

REFERENCES

1. Clayton RA, Court-Brown CM. The epidemiology of musculoskeletal tendinous and ligamentous injuries. *Injury*. 2008;39:1338–44. [PubMed: 19036362]
2. Burkhart SS, Lo IK. Arthroscopic rotator cuff repair. *J Am Acad Orthop Surg*. 2006;14:333–46. [PubMed: 16757673]
3. Wolf EM, Pennington WT, Agrawal V. Arthroscopic rotator cuff repair: 4- to 10-year results. *Arthroscopy*. 2004;20:5–12. [PubMed: 14716273]
4. Anderson K, Boothby M, Aschenbrenner D, van Holsbeeck M. Outcome and structural integrity after arthroscopic rotator cuff repair using 2 rows of fixation: minimum 2-year follow-up. *Am J Sports Med*. 2006;34:1899–905. [PubMed: 16870821]
5. Baysal D, Balyk R, Otto D, Luciak-Corea C, Beaupre L. Functional outcome and health-related quality of life after surgical repair of full-thickness rotator cuff tear using a mini-open technique. *Am J Sports Med*. 2005;33:1346–55. [PubMed: 16002486]
6. Bartolozzi A, Andreychik D, Ahmad S. Determinants of outcome in the treatment of rotator cuff disease. *Clin Orthop Relat Res*. 1994;308:90–7. [PubMed: 7955708]
7. Klepps S, Bishop J, Lin J, Cahlon O, Strauss A, Hayes P, et al. Prospective evaluation of the effect of rotator cuff integrity on the outcome of open rotator cuff repairs. *Am J Sports Med*. 2004;32:1716–22. [PubMed: 15494338]
8. Misamore GW, Ziegler DW, Rushton JL., 2nd Repair of the rotator cuff. A comparison of results in two populations of patients. *J Bone Joint Surg Am*. 1995;77:1335–9. [PubMed: 7673282]
9. Brislin KJ, Field LD, Savoie FH., 3rd Complications after arthroscopic rotator cuff repair. *Arthroscopy*. 2007;23:124–8. [PubMed: 17276218]
10. Weber SC, Abrams JS, Nottage WM. Complications associated with arthroscopic shoulder surgery. *Arthroscopy*. 2002;18(2 Suppl 1):88–95. [PubMed: 11828349]
11. Tauro JC. Stiffness and rotator cuff tears: incidence, arthroscopic findings, and treatment results. *Arthroscopy*. 2006;22:581–6. [PubMed: 16762694]
12. Trenerry K, Walton JR, Murrell GA. Prevention of shoulder stiffness after rotator cuff repair. *Clin Orthop Relat Res*. 2005;430:94–9. [PubMed: 15662309]
13. Bhargav D, Murrell GA. Shoulder stiffness: management. *Aust Fam Physician*. 2004;33:149–52. [PubMed: 15054981]
14. Goldberg BA, Scarlat MM, Harryman DT., 2nd Management of the stiff shoulder. *J Orthop Sci*. 1999;4:462–71. [PubMed: 10664431]
15. Gerber C, Espinosa N, Perren TG. Arthroscopic treatment of shoulder stiffness. *Clin Orthop Relat Res*. 2001;390:119–28. [PubMed: 11550857]
16. Chen AL, Shapiro JA, Ahn AK, Zuckerman JD, Cuomo F. Rotator cuff repair in patients with type I diabetes mellitus. *J Shoulder Elbow Surg*. 2003;12:416–21. [PubMed: 14564259]

17. Warner JJ, Allen AA, Marks PH, Wong P. Arthroscopic release of postoperative capsular contracture of the shoulder. *J Bone Joint Surg Am.* 1997;79:1151-8. [PubMed: 9278074]
18. Beaufils P, Prevot N, Boyer T, Allard M, Dorfmann H, Frank A, et al. Arthroscopic release of the glenohumeral joint in shoulder stiffness: A review of 26 cases. French Society for Arthroscopy. *Arthroscopy.* 1999;15:49-55. [PubMed: 10024033]
19. Nicholson GP. Arthroscopic capsular release for stiff shoulders: effect of etiology on outcomes. *Arthroscopy.* 2003;19:40-9. [PubMed: 12522401]
20. Holloway GB, Schenk T, Williams GR, Ramsey ML, Iannotti JP. Arthroscopic capsular release for the treatment of refractory postoperative or post-fracture shoulder stiffness. *J Bone Joint Surg Am.* 2001;83-A:1682-7. [PubMed: 11701791]
21. Michener LA, McClure PW, Sennett BJ. American Shoulder and Elbow Surgeons Standardized Shoulder Assessment Form, patient self-report section: reliability, validity, and responsiveness. *J Shoulder Elbow Surg.* 2002;11:587-94. [PubMed: 12469084]
22. Lippitt SB, Harryman DT, Matsen FAI. A Practical tool for evaluating function: The simple shoulder test. In: Matsen FAI, Fu FH, Hawkins RJ, editors. *The Shoulder: A Balance of mobility and stability.* Rosemont, IL: The American Academy of Orthopaedic Surgeons; 1993. pp. 545-59.
23. Denard PJ, Ladermann A, Burkhart SS. Prevention and management of stiffness after arthroscopic rotator cuff repair: Systematic review and implications for rotator cuff healing. *Arthroscopy.* 2011;27:842-8. [PubMed: 21624680]
24. Huberty DP, Schoolfield JD, Brady PC, Vadala AP, Arrigoni P, Burkhart SS. Incidence and treatment of postoperative stiffness following arthroscopic rotator cuff repair. *Arthroscopy.* 2009;25:880-90. [PubMed: 19664508]
25. Henn RF, 3rd, Kang L, Tashjian RZ, Green A. Patients with workers' compensation claims have worse outcomes after rotator cuff repair. *J Bone Joint Surg Am.* 2008;90:2105-13. [PubMed: 18829907]
26. Balyk R, Luciak-Corea C, Otto D, Baysal D, Beaupre L. Do outcomes differ after rotator cuff repair for patients receiving workers' compensation? *Clin Orthop Relat Res.* 2008;466:3025-33. [PMCID: PMC2628237] [PubMed: 18784971]

Figures and Tables

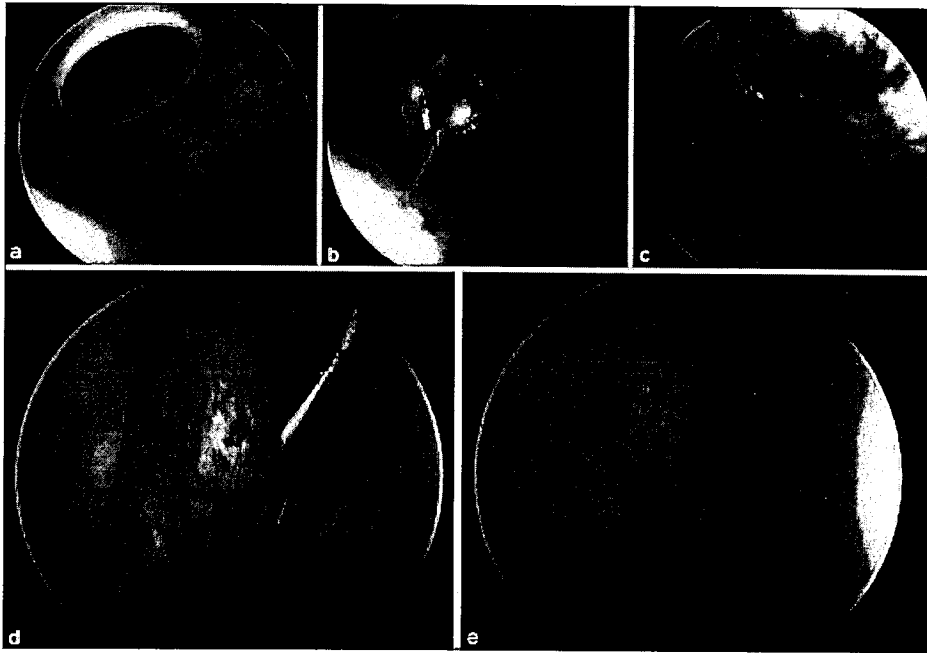
Table 1

Demographic category	Characteristic
Mean age at surgery	49.8 ± 11 years (range 24 – 70 years)
Gender	Male (62.0%) Female (37.9%)
Dominant side involvement	Yes (69.0%) No (31.0%)
Comorbidities	Diabetes Mellitus (17.2%) Hypothyroidism (3.5%)
Social history	Current/recent tobacco user (31.0%)
Workman's Compensation involvement	Yes (55.2%) No (44.8%)
Index rotator cuff repair (RCR) approach	Arthroscopic (62.1%) Mini-open (10.3%) Open (27.6%)
Manipulation under anesthesia prior to lysis of adhesions	Yes (31.0%) No (69.0%)
Time between RCR and lysis of adhesions procedure	9.7 ± 5.1 months (range 4.2 – 24.3 months)

RGR = Rotator cuff repair

Demographic characteristics of the stiffness cohort (*n* = 29)

Figure 1



Arthroscopic view of left shoulder in beach chair position. Following diagnostic arthroscopy (a), an arthroscopic shaver (b) and RF tool (c) was used to take down the anterior capsule. Capsular release was continued with the aid of an arthroscopic biter (d) from the 12 o'clock to 6 o'clock position (e). Following anterior capsular release, the camera was placed in the anterior portal and a posterior capsular release was performed in similar fashion from the posterosuperior recess down to the 6 o'clock position. The scope was then removed and a manipulation under anesthesia was performed intraoperatively after all arthroscopic releases were completed

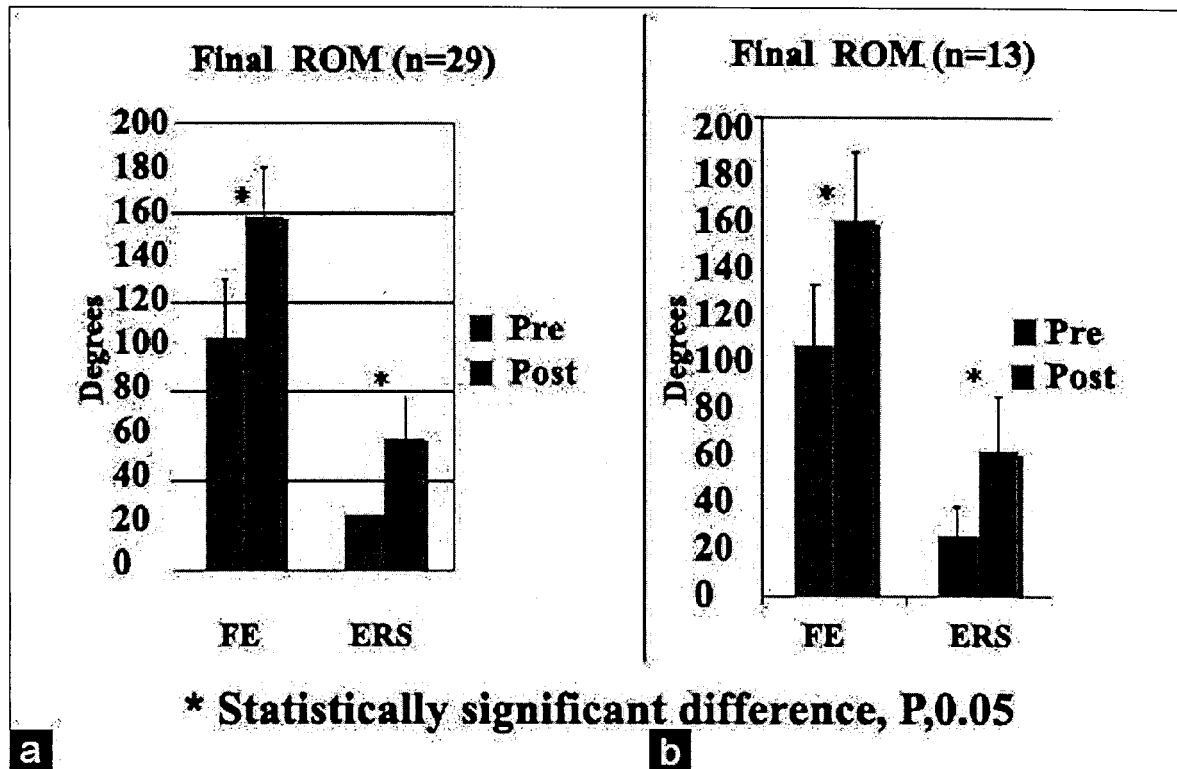
Table 2a

Outcome	Preoperative	Postoperative	P value*
Forward flexion ROM (°)	103.8 ± 26.3	158.3 ± 22.3	<0.0001
External rotation ROM (°)	25.3 ± 15.1	58.9 ± 18.6	<0.0001
Visual Analog Pain score (0-10)	—	2.5 ± 2.9	—
ASES score (0-100)	—	75.5 ± 23.5	—
SST score (0-12)	—	7.8 ± 3.2	—
SANE score (0-100)	—	80.3 ± 18.7	—
Constant-Murley score (0-100)	—	68.9 ± 16	—

*Using Student's *t*-test (GraphPad Inc, La Jolla, CA), (Mean follow-up in this cohort: 18.2 ± 13.1 months)

Outcomes after arthroscopic lysis of adhesions in all patients ($n = 29$)

Figure 2



Bar diagram showing (a) Outcomes after arthroscopic capsular release in all patients ($n = 29$). Mean follow-up in this cohort: 18.2 ± 13.1 months. (b) Outcomes after arthroscopic lysis of adhesions in patients available for final followup ($n = 13$). Mean follow-up in this cohort: 24.6 ± 10.0 months

Table 2b

Outcome	Preoperative	Postoperative	P value*
Forward flexion ROM (°)	104.6 ± 25.5	157.0 ± 28.3	<0.0001
External rotation ROM (°)	25.0 ± 11.7	60.0 ± 23.0	0.0001
Visual Analog Pain score (0-10)	—	2.5 ± 2.9	—
ASES score (0-100)	—	75.5 ± 23.5	—
SST score (0-12)	—	7.8 ± 3.2	—
SANE score (0-100)	—	80.3 ± 18.7	—
Constant-Murley score (0-100)	—	68.9 ± 16	—

*Using Student's t test (GraphPad Inc, La Jolla, CA), (Mean follow-up in this cohort: 24.6 ± 10.0 months).

Outcomes after arthroscopic lysis of adhesions in patients available for an independent final followup examination ($n = 13$)

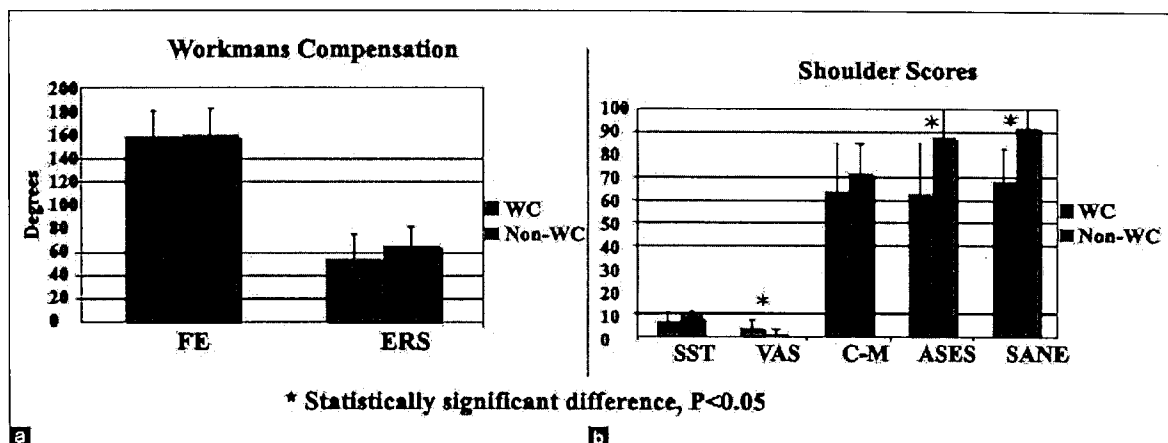
Table 3

Outcome	Worker's Compensation	Non-workers' Compensation	P-value*
Forward flexion ROM (°)	158.7 ± 22.1	159.2 ± 23.8	0.955
External rotation ROM (°)	54.7 ± 19.9	65.4 ± 16.2	0.142
Visual Analog Pain score (0-10)	4.0 ± 2.8	1.0 ± 2.1	0.021
ASES score (0-100)	63.0 ± 21.2	88.0 ± 18.3	0.019
SST score (0-12)	6.9 ± 3.8	8.8 ± 2.3	0.224
SANE score (0-100)	68.3 ± 14.4	92.2 ± 14.6	0.003
Constant-Murley score (0-100)	64.0 ± 21.2	72.1 ± 12.5	0.401
Followup period (months)	21.4 ± 14.5	27.3 ± 9.9	0.228

*Using Student's t-test (GraphPad Inc, La Jolla, CA)

Effect of worker's compensation status after arthroscopic capsular release

Figure 3



Bar diagram of postoperative outcomes following lysis of adhesions procedure in Workers' Compensation and Non-workers' Compensation patients. Statistically significant differences are indicated with an asterisk. (a) Postoperative range of motion in forward elevation (FE) and external rotation at the side (ERS) (b) Postoperative shoulder scores

Articles from Indian Journal of Orthopaedics are provided here courtesy of Medknow Publications