

# Biceps Tenodesis: An Evolution of Treatment

Brandon J. Erickson, MD, Akshay Jain, BS, Gregory L. Cvetanovich, MD, Gregory P. Nicholson, MD, Brian J. Cole, MD, Anthony A. Romeo, MD, and Nikhil N. Verma, MD

## Abstract

The long head of the biceps (LHB) tendon is a potential generator of pain within the shoulder. Tenodesis of the LHB is a treatment option for several pathologic shoulder conditions.

We conducted a study to determine trends in LHB tenodesis at a subspecialty-focused shoulder orthopedic practice. We hypothesized that the rate of LHB tenodesis would increase significantly over time and that there would be no significant change in the age of patients who underwent LHB tenodesis.

Records of 4 fellowship-trained sports or shoulder/elbow orthopedic surgeons were used to identify total number of common arthroscopic shoulder surgeries performed between 2004 and 2014. Number of LHB tenodesis cases, combined or isolated, was recorded. Linear regression was used for

analysis with significance set at  $P < .05$ .

Of the 7640 patients who underwent arthroscopic shoulder procedures between 2004 and 2014, 2125 had LHB tenodesis. Mean (SD) age of the subgroup was 49.33 (13.2) years, and mean (SD) number of LHB tenodesis cases per year was 193.2 (130.5). Over time, mean number of LHB tenodesis cases increased significantly ( $P = .0024$ ), mean age of patients who had these procedures did not change significantly ( $P = .934$ ), and percentage of LHB tenodesis cases increased significantly relative to percentage of all arthroscopic shoulder procedures ( $P = .0099$ ).

The number of LHB tenodesis cases is increasing without a significant change in patient age.

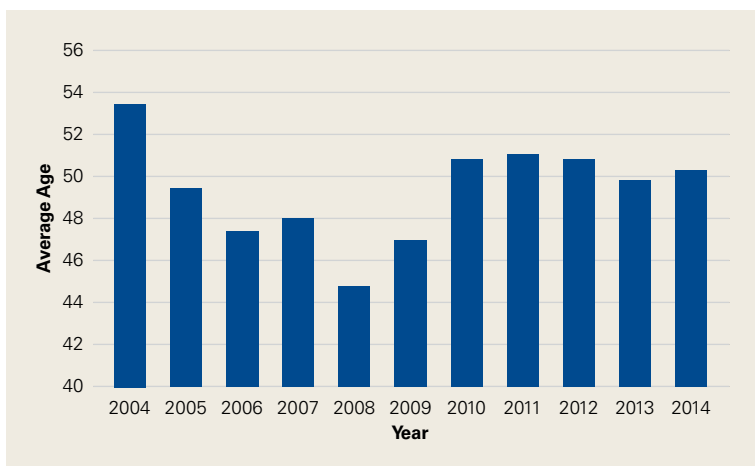
Although the exact function of the long head of the biceps (LHB) tendon is not completely understood, it is accepted that the LHB tendon can be a significant source of pain within the shoulder.<sup>1-4</sup> Patients with symptoms related to biceps pathology often present with anterior shoulder pain that worsens with flexion and supination of the affected elbow and wrist.<sup>5</sup> Although the sensitivity and specificity of physical examination maneuvers have been called into question, special tests have been developed to aid in the diagnosis of tendonitis of the LHB. These tests include the Speed, Yergason, bear hug, and uppercut tests as well as the O'Brien test (cross-body adduction).<sup>6,7</sup> Recent studies have found LHB pathology in 45% of patients who undergo rotator cuff repair and in 63% of patients with a subscapularis tear.<sup>8,9</sup>

Pathology of the LHB tendon, including superior labrum anterior to posterior (SLAP) tears, can be

## Take-Home Points

- The LHB tendon has been shown to be a significant pain generator in the shoulder.
- At our institution, the number of LHB tenodeses significantly increased from 2004 to 2014.
- The age of patients who underwent a LHB tenodesis did not change significantly over the study period.
- Furthermore, the percentage of shoulder procedures that involved a LHB tenodesis significantly increased over the study period.
- Biceps tenodesis has become a more common procedure to treat shoulder pathology.

**Authors' Disclosure Statement:** The authors report no actual or potential conflict of interest in relation to this article.



**Figure 1.** Mean age of patients who underwent long head of biceps tenodesis at our institution did not change significantly between 2004 and 2014 ( $P = .934$ ).

treated in many ways.<sup>5,10,11</sup> Options include SLAP repair, biceps tenodesis, débridement, and biceps tenotomy.<sup>11,12</sup> Results of SLAP repairs have been less than optimal, but biceps tenodesis has been effective, and avoids the issue of cramping as can be seen with biceps tenotomy and débridement.<sup>10,12,13</sup> Surgical methods for biceps tenodesis include open subpectoral and all-arthroscopic.<sup>11,12</sup> Both methods have had good, reliable outcomes, but the all-arthroscopic technique is relatively new.<sup>11,12,14</sup>

We conducted a study to determine LHB tenodesis trends, including patient age at time of surgery. We used surgical data from fellowship-trained sports or shoulder/elbow orthopedic surgeons at a busy subspecialty-based shoulder orthopedic practice. We hypothesized that the rate of LHB tenodesis would increase significantly over time and that there would be no significant change in the age of patients who underwent LHB tenodesis.

## Methods

Our Institutional Review Board exempted this study. To determine the number of LHB tenodesis procedures performed at our institution, overall and in comparison with other common arthroscopic shoulder procedures, we queried the surgical database of 4 fellowship-trained orthopedic surgeons (shoulder/elbow, Drs. Nicholson and Cole; sports, Drs. Romeo and Verma) for the period January 1, 2004 to December 31, 2014. We used *Current Procedural Terminology (CPT)* code 23430 to determine the number of LHB tenodesis cases, as the surgeons primarily perform an open subpectoral biceps tenodesis. Patient age

at time of surgery and the date of surgery were recorded. All patients who underwent LHB tenodesis between January 1, 2004 and December 31, 2014 were included. Number of procedures performed each year by each surgeon was recorded, as were concomitant procedures performed at the same time as the LHB tenodesis. To get the denominator (and reference point) for the number of arthroscopic shoulder surgeries performed by these 4 surgeons during the study period, and thereby determine the rate of LHB tenodesis, we selected the most common shoulder arthroscopy *CPT* codes used in our practice: 23430, 29806, 29807, 29822, 29823, 29825, 29826, and 29827. For a patient who underwent multiple procedures on the same day (multiple *CPT* codes entered on the same day), only one code was counted for that day. If 23430 was among the codes, it was included, and the case was placed in the numerator; if 23430 was not among the codes, the case was placed in the denominator.

The Arthroscopy Association of North America provides descriptions for the *CPT* codes: 23430 (tenodesis of long tendon of biceps), 29806 (arthroscopy, shoulder, surgical; capsulorrhaphy), 29807 (arthroscopy, shoulder, surgical; repair of SLAP lesion), 29822 (arthroscopy, shoulder, surgical; débridement, limited), 29823 (arthroscopy, shoulder, surgical; débridement, extensive), 29825 (arthroscopy, shoulder, surgical; with lysis and resection of adhesions, with or without manipulation), 29826 (arthroscopy, shoulder, surgical; decompression of subacromial space with partial acromioplasty, with or without coracoacromial release), and 29827 (arthroscopy, shoulder, surgical; with rotator cuff repair).

For analysis, we divided the data into total number of arthroscopic shoulder procedures performed by each surgeon each year and number of LHB tenodesis procedures performed by each surgeon each year. Total number of patients who had an arthroscopic procedure was used to create a denominator, and number of LHB tenodesis procedures showed the percentage of arthroscopic shoulder surgery patients who underwent LHB tenodesis. (All patients who undergo biceps tenodesis also have, at the least, diagnostic shoulder arthroscopy with or without tenotomy; if the tendon is ruptured, tenotomy is unnecessary.)

Descriptive statistics were calculated as means (SDs) for continuous variables and as frequencies with percentages for categorical variables.

Linear regression analysis was used to determine whether the number of LHB tenodesis procedures changed during the study period and whether patient age changed over time. Significance was set at  $P < .05$ .

### Results

Of the 7640 patients who underwent arthroscopic shoulder procedures between 2004 and 2014, 2125 had LHB tenodesis (CPT code 23430). Mean (SD) age of the subgroup was 49.33 (13.2) years, and mean (SD) number of LHB tenodesis cases per year was 193.2 (130.5). Over time, mean age of patients who had these procedures did not change significantly ( $P = .934$ ) (Figure 1), mean number of LHB tenodesis cases increased significantly ( $P = .0024$ ) (Figure 2A), and percentage of LHB tenodesis cases increased significantly relative to percentage of all arthroscopic shoulder procedures ( $P = .0099$ ) (Figure 2B). The concomitant procedures performed with LHB tenodesis during the study period are listed in the Table.

### Discussion

Tenodesis has become a common treatment option for several pathologic shoulder conditions involving the LHB tendon.<sup>5</sup> We set out to determine trends in LHB tenodesis at a subspecialty-focused shoulder orthopedic practice and hypothesized that the rate of LHB tenodesis would increase significantly over time and that there would be no significant change in the age of patients who underwent LHB tenodesis. Our hypotheses were confirmed: The number of LHB tenodesis cases increased significantly without a significant change in patient age.

Treatment options for LHB pathology and SLAP tears include simple tenotomy, débridement, open biceps tenodesis, and arthroscopic tenodesis.<sup>11,12,15</sup> Several fixation options have been used in open subpectoral biceps tenodesis. In this technique, which was used by all the surgeons in this study, the biceps tendon is fixed such that the musculotendinous junction of the biceps rests at the inferior border of the pectoralis major in the bicipital groove.<sup>16-19</sup> Studies have found good, reliable outcomes with both the open and the arthroscopic surgical techniques.<sup>12,18</sup> Comparing the LHB tenodesis trends in the present study with the SLAP repair trends we found at our institution in a previous study,<sup>20</sup> we discovered that overall number of LHB tenodesis cases and percentage of LHB tenodesis cases relative to percentage of all arthroscopic

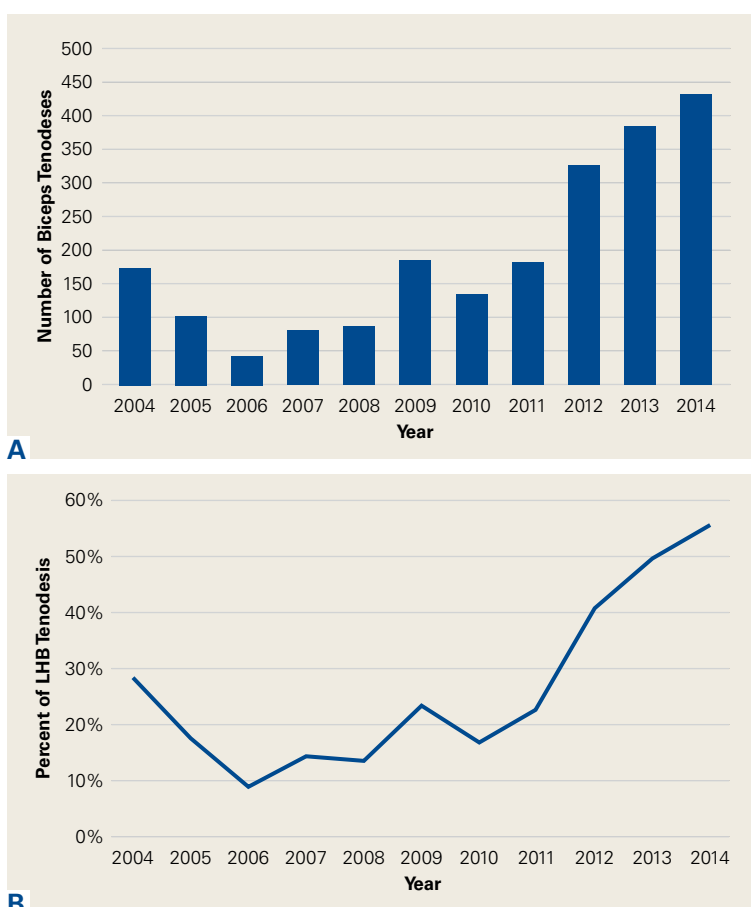


Figure 2. (A) Number of long head of biceps (LHB) tenodesis procedures performed by year; overall number increased significantly over time ( $P = .0024$ ). (B) Percentage of arthroscopic shoulder procedures that involved isolated or concomitant LHB tenodesis increased significantly over time ( $P = .0099$ ).

shoulder procedures increased significantly more than for SLAP repairs.

Recent evidence has called into question the results of SLAP repairs and suggested biceps tenodesis may be a better treatment option for SLAP tears.<sup>10,13,21</sup> Studies have found excellent outcomes with open subpectoral biceps tenodesis in the treatment of SLAP tears, and others have found better restoration of pitchers' thoracic rotation with open subpectoral biceps tenodesis than with SLAP repair.<sup>13,14</sup> Similarly, comparison studies have largely favored biceps tenodesis over SLAP repair, particularly in patients older than 35 years to 40 years.<sup>22</sup> Given these results, it is not surprising that, querying the American Board of Orthopaedic Surgeons (ABOS) part II database for isolated SLAP lesions treated between 2002 and 2011, Patterson and colleagues<sup>23</sup> found the percentage of SLAP repairs decreased from 69.3% to 44.8% ( $P < .0001$ ), whereas the percentage of biceps tenod-

Table. **Concomitant Procedures Performed at the Same Time as Long Head of Biceps Tenodesis by Year**

Year	CPT Code <sup>a</sup>						
	29806	29807	29822	29823	29825	29826	29827
2004	3	10	4	28	6	98	43
2005	4	7	8	28	7	112	48
2006	4	5	5	13	4	92	39
2007	4	5	4	9	4	64	27
2008	3	5	4	10	3	64	27
2009	7	4	0	14	6	25	26
2010	2	1	0	5	3	16	17
2011	2	2	9	10	2	12	13
2012	8	6	7	111	13	135	78
2013	16	2	50	82	23	198	110
2014	17	9	70	90	16	229	163

Abbreviations: CPT, Current Procedural Terminology; SLAP, superior labrum anterior to posterior.

<sup>a</sup>29806 (arthroscopy, shoulder, surgical; capsulorrhaphy); 29807 (arthroscopy, shoulder, surgical; repair of SLAP lesion); 29822 (arthroscopy, shoulder, surgical; débridement, limited); 29823 (arthroscopy, shoulder, surgical; débridement, extensive); 29825 (arthroscopy, shoulder, surgical; with lysis and resection of adhesions, with or without manipulation); 29826 (arthroscopy, shoulder, surgical; decompression of subacromial space with partial acromioplasty, with or without coracoacromial release); 29827 (arthroscopy, shoulder, surgical; with rotator cuff repair).

esis procedures increased from 1.9% to 18.8% ( $P < .0001$ ), indicating the realization of improved outcomes with LHB tenodesis in the treatment of SLAP tears. On the other hand, in the ABOS part II database for the period 2003 to 2008, Weber and colleagues<sup>24</sup> found that, despite a decrease in the percentage of SLAP repairs, total number of SLAP repairs increased from 9.4% to 10.1% ( $P = .0163$ ). According to our study results, the number of SLAP repairs is decreasing over time, whereas the number of LHB tenodesis procedures is continuing to rise. The practice patterns seen in our study correlate with those in previous studies of the treatment of SLAP tears: good results in tenodesis groups and poor results in SLAP repair groups.<sup>10,13</sup>

Werner and colleagues<sup>25</sup> recently used the large PearlDiver database, which includes information from both private payers and Medicare, to determine overall LHB tenodesis trends in the United States for the period 2008 to 2011. Over those years, the incidence of LHB tenodesis increased 1.7-fold, and the rate of arthroscopic LHB tenodesis increased significantly more than the rate of open LHB tenodesis. These results are similar to ours in that the number of LHB tenodesis cases increased significantly over time. However, as the

overwhelming majority of patients in our practice undergo open biceps tenodesis, the faster rate of growth in the arthroscopic cohort relative to the open cohort cannot be assessed. Additional randomized studies comparing biceps tenodesis, both open and arthroscopic, with SLAP repair are needed to properly determine the superiority of LHB tenodesis over SLAP repair.

One strength of this database study was the number of patients: more than 7000, 2125 of whom underwent biceps tenodesis performed by 1 of 4 fellowship-trained orthopedic surgeons. There were several study limitations. First, because the original diagnoses were not recorded, it was unclear exactly which pathologies were treated with tenodesis, limiting our ability to make recommendations regarding treatment trends for specific pathologies. Similarly, we did not assess outcome variables, which would have allowed us to draw conclusions about the effectiveness of the biceps tenodesis procedures. Furthermore, some procedures may have been coded incorrectly, and therefore some patients may have been erroneously included or excluded. In addition, using data from only one institution may have introduced bias into our conclusions, though the results are consistent

with national trends. Finally, there was some variability among the 4 surgeons in the number of LHB tenodesis procedures performed, and this variability may have confounded results, though these surgeons treat biceps pathology in similar ways.

Dr. Erickson is a Resident, Mr. Jain is a Research Assistant, and Dr. Cvetanovich is a Resident, Department of Orthopaedic Surgery, and Dr. Nicholson is an Attending Physician, Department of Shoulder and Elbow Surgery, Midwest Orthopaedics at Rush, Rush University Medical Center, Chicago, Illinois. Dr. Cole is an Attending Physician, Department of Sports Medicine, Midwest Orthopaedics at Rush, Rush University Medical Center, Chicago, Illinois, and Head Team Physician, Chicago Bulls, Chicago, Illinois. Dr. Romeo is an Attending Physician and Chair, Department of Shoulder and Elbow Surgery, and Dr. Verma is an Attending Physician, Department of Sports Medicine, Midwest Orthopaedics at Rush, Rush University Medical Center, Chicago, Illinois.

Address correspondence to: Brandon J. Erickson, MD, Department of Orthopaedic Surgery, Midwest Orthopaedics at Rush, Rush University Medical Center, 1611 W Harrison St, Suite 300, Chicago, IL 60612 (tel, 312-243-4244; fax, 312-942-1517; email, berickso.24@gmail.com).

*Am J Orthop.* 2017;46(4):E219-E223. Copyright Frontline Medical Communications Inc. 2017. All rights reserved.

## References

- Denard PJ, Dai X, Hanypsiak BT, Burkhart SS. Anatomy of the biceps tendon: implications for restoring physiological length-tension relation during biceps tenodesis with interference screw fixation. *Arthroscopy.* 2012;28(10):1352-1358.
- Ejnisman B, Monteiro GC, Andreoli CV, de Castro Pochini A. Disorder of the long head of the biceps tendon. *Br J Sports Med.* 2010;44(5):347-354.
- Mellano CR, Shin JJ, Yanke AB, Verma NN. Disorders of the long head of the biceps tendon. *Instr Course Lect.* 2015;64:567-576.
- Szabo I, Boileau P, Walch G. The proximal biceps as a pain generator and results of tenotomy. *Sports Med Arthrosc Rev.* 2008;16(3):180-186.
- Harwin SF, Birns ME, Mbabuue JJ, Porter DA, Galano GJ. Arthroscopic tenodesis of the long head of the biceps. *Orthopedics.* 2014;37(11):743-747.
- Holtby R, Razmjou H. Accuracy of the Speed's and Yergason's tests in detecting biceps pathology and SLAP lesions: comparison with arthroscopic findings. *Arthroscopy.* 2004;20(3):231-236.
- Ben Kibler W, Sciascia AD, Hester P, Dome D, Jacobs C. Clinical utility of traditional and new tests in the diagnosis of biceps tendon injuries and superior labrum anterior and posterior lesions in the shoulder. *Am J Sports Med.* 2009;37(9):1840-1847.
- Lafosse L, Reiland Y, Baier GP, Toussaint B, Jost B. Anterior and posterior instability of the long head of the biceps tendon in rotator cuff tears: a new classification based on arthroscopic observations. *Arthroscopy.* 2007;23(1):73-80.
- Adams CR, Schoolfield JD, Burkhart SS. The results of arthroscopic subscapularis tendon repairs. *Arthroscopy.* 2008;24(12):1381-1389.
- Provencher MT, McCormick F, Dewing C, McIntire S, Solomon D. A prospective analysis of 179 type 2 superior labrum anterior and posterior repairs: outcomes and factors associated with success and failure. *Am J Sports Med.* 2013;41(4):880-886.
- Gombera MM, Kahlenberg CA, Nair R, Saltzman MD, Terry MA. All-arthroscopic suprapectoral versus open subpectoral tenodesis of the long head of the biceps brachii. *Am J Sports Med.* 2015;43(5):1077-1083.
- Delle Rose G, Borroni M, Silvestro A, et al. The long head of biceps as a source of pain in active population: tenotomy or tenodesis? A comparison of 2 case series with isolated lesions. *Musculoskelet Surg.* 2012;96(suppl 1):S47-S52.
- Chalmers PN, Trombley R, Cip J, et al. Postoperative restoration of upper extremity motion and neuromuscular control during the overhand pitch: evaluation of tenodesis and repair for superior labral anterior-posterior tears. *Am J Sports Med.* 2014;42(12):2825-2836.
- Gupta AK, Chalmers PN, Klosterman EL, et al. Subpectoral biceps tenodesis for bicipital tendonitis with SLAP tear. *Orthopedics.* 2015;38(1):e48-e53.
- Ge H, Zhang Q, Sun Y, Li J, Sun L, Cheng B. Tenotomy or tenodesis for the long head of biceps lesions in shoulders: a systematic review and meta-analysis. *PLoS One.* 2015;10(3):e0121286.
- Kaback LA, Gowda AL, Paller D, Green A, Blaine T. Long head biceps tenodesis with a knotless cinch suture anchor: a biomechanical analysis. *Arthroscopy.* 2015;31(5):831-835.
- Kany J, Guinand R, Amaravathi RS, Alassaf I. The keyhole technique for arthroscopic tenodesis of the long head of the biceps tendon. In vivo prospective study with a radio-opaque marker. *Orthop Traumatol Surg Res.* 2015;101(1):31-34.
- Mazzocca AD, Cote MP, Arciero CL, Romeo AA, Arciero RA. Clinical outcomes after subpectoral biceps tenodesis with an interference screw. *Am J Sports Med.* 2008;36(10):1922-1929.
- Provencher MT, LeClere LE, Romeo AA. Subpectoral biceps tenodesis. *Sports Med Arthrosc Rev.* 2008;16(3):170-176.
- Erickson BJ, Jain A, Abrams GD, et al. SLAP lesions: trends in treatment. *Arthroscopy.* 2016;32(6):976-981.
- Erickson J, Lavery K, Monica J, Gatt C, Dhawan A. Surgical treatment of symptomatic superior labrum anterior-posterior tears in patients older than 40 years: a systematic review. *Am J Sports Med.* 2015;43(5):1274-1282.
- Denard PJ, Lademann A, Parsley BK, Burkhart SS. Arthroscopic biceps tenodesis compared with repair of isolated type II SLAP lesions in patients older than 35 years. *Orthopedics.* 2014;37(3):e292-e297.
- Patterson BM, Creighton RA, Spang JT, Roberson JR, Kamath GV. Surgical trends in the treatment of superior labrum anterior and posterior lesions of the shoulder: analysis of data from the American Board of Orthopaedic Surgery certification examination database. *Am J Sports Med.* 2014;42(8):1904-1910.
- Weber SC, Martin DF, Seiler JG 3rd, Harrast JJ. Superior labrum anterior and posterior lesions of the shoulder: incidence rates, complications, and outcomes as reported by American Board of Orthopedic Surgery. Part II candidates. *Am J Sports Med.* 2012;40(7):1538-1543.
- Werner BC, Brockmeier SF, Gwathmey FW. Trends in long head biceps tenodesis. *Am J Sports Med.* 2015;43(3):570-578.

*This paper will be judged for the Resident Writer's Award.*