



ELSEVIER

A comprehensive analysis of pectoralis major transfer for long thoracic nerve palsy

Peter N. Chalmers, MD*, Bryan M. Saltzman, MD, Terrence F. Feldheim, BA, Randy Mascarenhas, MD, Chris Mellano, MD, Brian J. Cole, MD, Anthony A. Romeo, MD, Gregory P. Nicholson, MD

Department of Orthopaedic Surgery, Rush University Medical Center, Chicago, IL, USA

Background: In the treatment of long thoracic nerve palsy with pectoralis major transfer, it remains unknown whether direct transfer of the pectoralis to the scapula or indirect transfer with an interpositional graft provides superior outcomes.

Methods: A 3-tiered study was performed to gain a comprehensive understanding. (1) A survey of the membership of the American Shoulder and Elbow Surgeons (ASES) was conducted to reach a Level V consensus. (2) A systematic review was conducted to identify all series evaluating direct and indirect transfer of the pectoralis major tendon to create a Level IV consensus. (3) A retrospective review was performed to provide Level III evidence.

Results: (1) Surgeons were evenly split between whole and split tendon transfers, direct and indirect transfers, and graft types. More experienced surgeons were more likely to prefer an indirect transfer. (2) Analysis of 10 Level IV studies (131 shoulders) revealed that patients who underwent indirect transfer were significantly more likely to develop recurrent winging ($P = .009$) and had lower active forward elevation ($P < .001$) and ASES scores ($P = .0016$). (3) Twenty-four patients were included in our retrospective review with a mean follow-up of 4.3 years (77% follow-up), of whom 14 underwent indirect transfer and 10 underwent direct transfer. There were no significant differences in recurrence of winging, range of motion, or ASES scores.

Conclusions: Level V and III evidence suggests that there is no functional difference between direct and indirect transfer. Level IV evidence must be interpreted with caution.

Level of evidence: Level III, Retrospective Cohort Design, Treatment Study.

© 2015 Journal of Shoulder and Elbow Surgery Board of Trustees.

Keywords: Long thoracic nerve palsy; serratus anterior palsy; pectoralis major transfer; allograft; meta-analysis; levels of evidence

This study has been approved under Rush University Medical Center Institutional Review Board protocol No. 12062702.

*Reprint requests: Peter N. Chalmers, MD, Department of Orthopaedic Surgery, Rush University Medical Center, 1611 W Harrison St, Suite 200, Chicago, IL 60612, USA.

E-mail address: p.n.chalmers@gmail.com (P.N. Chalmers).

Injury to the long thoracic nerve with resultant serratus anterior palsy results in medial winging of the scapula.^{3,7,10} This nerve is susceptible to trauma and iatrogenic injury because of its prominence on the rib cage and circuitous route along the lateral thorax.^{4,17,21,22} In addition, the long thoracic nerve is susceptible to postinfectious and inflammatory neuritides.^{12,16,21} The serratus anterior stabilizes the

Table I Survey questions and answers

Question	Possible answers
Is an electromyogram necessary for diagnosis?	Yes/No
How many months do you wait for recovery before considering a tendon transfer?	6/9/12/18/24
When performing a tendon transfer, what is your ideal donor muscle?	Pectoralis minor/Pectoralis major/Sternal head of pectoralis major
What is your ideal technique for transfer?	Direct transfer onto the scapula augmented with a graft/Indirect transfer [tendon graft extension] with allograft or autograft/ Direct transfer onto the scapula
What is your ideal graft?	Fascia lata autograft/Achilles allograft/Hamstring autograft/ Tibialis anterior allograft
How many years have you been in practice?	No/Hand/Shoulder and elbow/Sports/Multiple fields
Did you complete fellowship training?	
How many patients have you seen with this condition in the last year?	
How many patients have you seen with this condition in the history of your practice?	

scapula to the thorax, providing the remainder of the glenohumeral and parascapular musculature a stable fulcrum against which to elevate the humerus.^{1,2,11,20,22} Paralysis of the serratus therefore predictably leads to dysfunction.^{1,2,11,20,22} Most long thoracic neuropathies resolve within 12 to 18 months, and thus the majority of patients can be successfully treated with expectant observation with physical therapy and avoidance of activities that involve elevation of the shoulder.^{3,4,10,23}

For those patients who fail to respond to nonoperative treatment, a variety of tendon transfers to substitute for the action of the serratus anterior have been proposed.^{1-3,5,6,11,13,14,17,18,20,22} The sternal head of the pectoralis major is particularly well suited owing to similar line of pull, excursion, and cross-sectional area (i.e., power) to the serratus.^{3,4,10,11,23} The surgical technique has evolved, with older series reporting the use of an interpositional fascia lata autograft.^{3,11,14} The use of the graft as a bridge was thought to lead to stretching and fraying of the graft, with the development of recurrent winging in some patients.^{6,13,14,17,18} These concerns led to an anatomic “proof of concept” study showing that direct transfer of the sternal head of the pectoralis major was possible without the use of a graft for interposition.¹⁵ This has been followed by a number of studies demonstrating excellent outcomes with this technique.^{2,20} However, because direct transfer places the transferred sternal head of the pectoralis major on significant tension, it can lead to traction neurapraxia of the medial and lateral pectoral nerves⁹ as well as potentially decreased postoperative range of motion.¹⁸ At our institution, we have modified the techniques described to avoid issues of both autograft donor morbidity and stretching of fascia lata grafts. Two separate techniques have been employed by the 2 senior authors: either (1) direct transfer in a fashion similar to previously described^{1,22} techniques with Achilles allograft augmentation or (2) indirect transfer with an interpositional tibialis anterior allograft tendon.

Numerous orthopedic procedures involve the use of graft tissue for the reconstruction of ligament and tendon. In these procedures, graft length is critical to restoration of function. However, our understanding of the effect of biologic incorporation and mechanical strain on change in length in graft tissue remains incomplete. The purpose of this study was to compare direct and interpositional indirect transfers. Our hypothesis was that direct transfers would provide superior outcomes by avoiding loss of graft tension. Because of the rarity of the procedure, it was decided to provide a comprehensive understanding of the currently available evidence using a 3-part study with (1) a Level V survey of the membership of the American Shoulder and Elbow Surgeons (ASES), (2) a Level IV systematic review of the literature, and (3) a Level III retrospective comparative cohort study.

Materials and methods

Survey

To better understand the current state of the art, we conducted an anonymous survey of the ASES membership. Participants were asked a series of 9 multiple choice questions that can be seen in [Table I](#). An a priori condition was set that the survey would not be considered complete until a 25% response rate was achieved. All analyses were conducted in Excel X (Microsoft Inc., Redmond, WA, USA) and SPSS 21 (IBM Inc., Armonk, NY, USA). Data were analyzed by descriptive statistics and χ^2 . These analyses looked to determine whether a relationship exists between the use of indirect and direct transfer and years in practice, area of fellowship training, and number of patients seen.

Systematic review

PubMed (MEDLINE), the Cochrane Central Register of Controlled Trials, and MD Consult were searched for all literature published from January 1, 1970, to January 31, 2014, with the following key words: pectoralis transfer AND (serratus OR “long

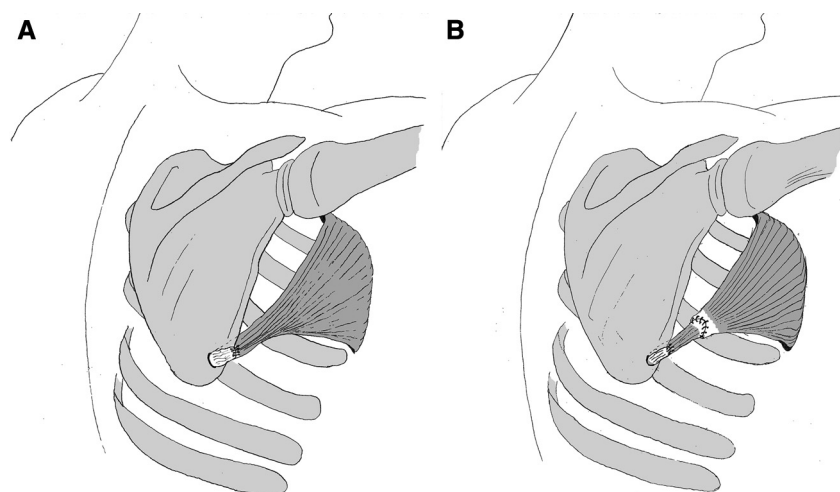


Figure 1 These schematic diagrams demonstrate direct (A) and indirect (B) pectoralis major transfer for serratus anterior palsy.

thoracic” OR palsy OR winged OR scapula). General search terms were used in an effort to capture all of the relevant studies. The abstracts of all resultant citations were reviewed by 2 authors. Studies were included only if they reported on clinical outcomes after pectoralis transfer for long thoracic nerve palsy. Criteria for exclusion were as follows: (1) fewer than 3 patients reported, (2) no clinical outcomes reported, and (3) articles in languages other than English.

Study characteristics, demographic characteristics, preoperative data, operative data, and postoperative data were recorded from each of the studies included for analysis. Study authors were contacted to gather missing data where necessary. Data were extracted from sources and then standardized to arithmetic means and standard deviations. In those cases in which standard deviation was not reported, it was calculated from the measure of variance reported by the authors. All means were weighted for sample size. Data are reported as weighted means \pm standard deviation. Statistical analysis was reported only for those variables reported by $\geq 50\%$ of the cohorts. In all cases, a P value of $<.05$ was considered statistically significant. Data reported as proportions were compared with z test calculators, which allow statistical comparison between 2 groups with different sample sizes.

Comparative cohort study

The operative logs of the 2 senior authors was reviewed from 2004 until the present, and those patients who had long thoracic nerve palsy and underwent transfer of the sternal head of the pectoralis major with or without use of tibialis anterior or Achilles allograft were included in this study. Exclusion criteria included patients with incomplete medical records.

The preoperative, operative, perioperative, and postoperative records for each of these patients were reviewed. Demographic and preoperative data were collected. Preoperative electromyography (EMG) was not performed in all cases as not all patients agreed to undergo EMG and in some cases the diagnosis was sufficiently clear to the examining surgeon that preoperative EMG was not thought to be clinically indicated. Postoperative data included complications and time to return to work or sport. Patients were also assessed clinically for recurrence of winging. The following clinical data were collected preoperatively and at final follow-up: range of

motion, the visual analog scale (VAS) score for pain, the Simple Shoulder Test (SST) score,⁸ and the ASES score.

Surgical technique

Our surgical technique is similar conceptually to previously described 2-incision techniques for transfer of the sternal head of the pectoralis major to the inferior portion of the lateral border of the scapula.^{2,22} After placement of the patient in the lateral decubitus position, the humeral insertion of the sternal head of the pectoralis major was identified through an axillary incision. This attachment was sharply detached and bluntly dissected from the clavicular head, all while protecting the long head of the biceps tendon and the humeral attachment of the clavicular head. To prepare the recipient site, a 5-cm incision was made at the inferior aspect of the lateral border of the scapula. The interval between the teres major and the latissimus dorsi was exploited, and the inferior lateral border of the scapula was subperiosteally dissected both anteriorly and posteriorly. A 2-cm drill hole was then made roughly 1 to 2 cm from the lateral border of the scapula, roughly at the junction of the inferior and middle thirds of the scapula. After rasping of the tunnel edges clean to avoid any fragments that may fray the graft, a blunt tunnel was created along the lateral thoracic cage while being careful to avoid a graft position that might compress the neurovascular bundle. The graft was then brought through the tunnel, confirming a direct line of pull. The sutures were brought through the scapula, and the scapula was manually reduced.

Direct transfer technique

In cases in which a direct transfer was performed, an Achilles allograft was employed, and it was tubularized with No. 5 braided sutures. The graft was then passed through the center of the pectoralis tendon and secured to itself by passing No. 5 FiberWire sutures (Arthrex Inc., Naples, FL, USA) through the graft, through the pectoralis tendon, and then through the graft again, tying these sutures to form the graft-tendon construct into a single unit. The transfer was tensioned until the pectoralis tendon contacted the scapula, with the graft used as an augment to assist in fixation (Fig. 1, A). In these cases, No. 5 FiberWire sutures were placed

through the tendon, through the augmentation, and through the bone of the scapula itself.

Indirect transfer technique

In cases in which an indirect technique was used, the sternal head of the pectoralis major was interwoven with and tubularized around allograft tibialis anterior tendon prepared with No. 2 Ethibond (Johnson and Johnson, New Brunswick, NJ, USA) Krackow locking stitches at both ends, with the tendon-graft junction reinforced with No. 2 Ethibond sutures to create a tapered construct. The graft was brought through the hole in the scapula and tensioned to reduce the scapula, but the pectoralis was not seated against the scapula and a gap existed between the tendon and the scapula. The graft was then sewn back onto itself with No. 2 FiberWire sutures (Fig. 1, B).

Similar postoperative protocols were used for both cohorts. Postoperatively, patients were immobilized in a sling for the first 4 to 6 weeks after surgery. At 6 weeks postoperatively, formal physical therapy was initiated, with a gradual progression from range of motion to strengthening with a focus on retraining the pectoralis musculature to assist with scapular stabilization during forward elevation, although no formal biofeedback is used. Previous studies have documented failure due to premature return to athletic activity or heavy labor at 2 to 3 months postoperatively,^{1,6,13} and thus we restricted patients from return to these activities for 4 to 6 months, depending on the activity and the patient.

Planned statistical analyses included Kolmogorov-Smirnov testing to determine whether parametric or nonparametric tests would be more appropriate and then paired Student *t* tests or Mann-Whitney *U* tests as appropriate to compare preoperative and postoperative VAS, SST, and ASES scores. Categorical data were compared by Fisher exact tests. No portion of the study received any funding.

Results

Survey

One hundred and twelve members of the ASES responded for a response rate of 26.6%, of whom 50% had been in practice for >20 years and 84% had been in practice for >10 years. Of all respondents, 94% were fellowship trained, with 59% having fellowship training specifically in shoulder and elbow surgery. Despite these respondents being fellowship-trained experts with well-established referral practices, this condition and this procedure remained infrequent, with 91% of respondents having seen fewer than 5 cases within the past year and 47% of respondents having seen fewer than 10 cases in their careers. A minority of surgeons could be classified as high-volume surgeons, with only a single surgeon having seen >20 cases in the past year and only 25% of respondents having seen >20 cases in their careers. The majority of respondents thought that EMG was necessary to make the diagnosis (79%; Supplemental Fig. 1). Although spontaneous improvement has been well described,^{3,4,10,23} there was no

consensus regarding the length of nonoperative treatment necessary before tendon transfer, with 46% of respondents selecting 1 year and 83% of respondents selecting 1 year or greater. There was no consensus regarding whether a split or whole pectoralis tendon should be used, with 30% of surgeons preferring the sternal head, 63% of surgeons preferring the entire pectoralis major, and 2% of surgeons preferring the pectoralis minor. There was also no consensus regarding transfer technique, with 30% of surgeons selecting a direct transfer, 24% of surgeons selecting a direct transfer augmented with a graft, and 40% of surgeons selecting an indirect transfer with graft interposition. There was no consensus regarding graft type, and surgeons were split between autograft and allograft (Supplemental Fig. 1).

When responses were stratified by years in practice, less experienced surgeons were no more likely than their more experienced counterparts to use whole vs. split tendon transfer or to prefer allograft over autograft ($P = .11$ and $.253$, respectively; Supplemental Fig. 2, A and B). Less experienced surgeons were more likely to use a direct transfer technique, and surgeons who had been in practice for more years were more likely to use an indirect transfer with graft interposition ($P = .026$; Supplemental Fig. 2, C). Surgeons who had seen more cases during their careers were more likely to use a split transfer with the sternal head as the donor tendon ($P < .001$; Supplemental Fig. 3, A) and more likely to use an indirect transfer technique with graft interposition ($P < .001$; Supplemental Fig. 3, B), but there were no differences in graft selection ($P = .238$; Supplemental Fig. 3, C).

Systematic review

The initial keyword search produced 238 combined unique articles from the 3 databases. After application of inclusion and exclusion criteria, 10 studies were included (Supplemental Fig. 4). There were 131 shoulders in 130 patients at final follow-up. Overall, there were 27 shoulders (26 patients) that received a direct transfer, which were compared with 104 shoulders (104 patients) that received an indirect transfer (Supplemental Table I). Unlike in our comparative cohort series, all direct transfers within our systematic review were performed without augmentation and all indirect transfers used autograft tendon.

Patients who underwent indirect transfer were significantly more likely to develop recurrent medial scapular winging than those who underwent direct transfer ($7.2\% \pm 3.1\%$ vs. $32.3\% \pm 15.8\%$; $P = .009$). Patients who underwent indirect transfer also had significantly lower postoperative active forward elevation ($152^\circ \pm 5^\circ$ vs. $164^\circ \pm 10^\circ$; $P < .001$) and ASES scores (63 ± 5 vs 66 ± 3 ; $P = .0016$) despite a shorter overall length of follow-up (41 ± 18 months vs. 61 ± 30 months; $P = .001$) and a population of younger patients (33 ± 1 vs. 38 ± 4 ; $P < .0001$). There were no additional significant differences

Table II Weighted mean and standard deviation of patient demographics and outcome measures in the direct and indirect cohorts

Variable	Direct		Indirect		P value
	Mean	SD	Mean	SD	
Age (years)	37.6	4.0	32.6	0.9	<.0001
Men (%)	40.5	19.2	56.0	17.7	.16
Traumatic (%)	48.2	6.6	66.1	15.8	.09
Iatrogenic (%)	30.4	20.9	18.3	15.4	.17
Idiopathic (%)	13.3	4.6	14.0	5.1	.9
Prior surgery (%)	59.7	25.2	40.0	16.8	.06
EMG positive (%)	100.0	0.0	89.9	13.0	.08
Duration of symptoms (months)	48.7	23.0	35.4	11.8	.18
Length of follow-up (months)	61.2	30.2	41.4	18.5	.001
Preoperative AFE (°)	115.9	35.9	102.8	13.2	.63
Postoperative AFE (°)	164.0	10.1	152.3	4.7	<.001
ASES score	65.8	3.4	63.2	5.1	.0016
Failures (%)	7.4	3.2	10.7	11.6	.54
Anatomic failures (%)	7.7	3.3	6.8	9.5	.86
Rate of return to work (%)	93.8	11.2	81.0	14.2	.11
Winging on examination (%)	7.2	3.1	32.3	15.8	.009
Reoperation rate (%)	11.3	6.4	15.6	11.1	.52
Complication rate (%)	7.7	3.3	16.5	10.4	.23

SD, standard deviation; EMG, electromyography; AFE, active forward elevation; ASES, American Shoulder and Elbow Surgeons.

with respect to demographics, preoperative data, or postoperative outcomes (Table II; $P > .05$ in all cases).

Comparative cohort study

Twenty-four patients with a mean follow-up of 4.3 ± 2.2 (standard deviation) years met inclusion criteria, with 9 men and a mean age of 30.0 ± 10.1 years (Table III). Eleven patients had undergone a variety of previous shoulder surgeries, including 1 glenohumeral fusion, 1 suprascapular nerve decompression, 1 long thoracic nerve decompression, 1 distal clavicle resection, 1 scapulothoracic bursectomy, 3 subacromial decompressions, and 5 labral repairs. Two patients had also undergone anterior cervical discectomy and fusion. In 14 cases, a tibialis anterior allograft and an indirect transfer were used; and in 10 cases, an Achilles allograft tendon and a direct transfer were used. One patient in each cohort underwent a concomitant procedure; in the indirect cohort, 1 patient underwent a concomitant arthroscopic subacromial decompression, and in the direct cohort, 1 patient underwent a concomitant superomedial angle resection. Three patients in the indirect cohort developed postoperative complications, including 2 suture wound infections that resolved with oral antibiotics and 1 case of complex

regional pain syndrome. One patient in the direct cohort developed postoperative arthrofibrosis requiring a manipulation under anesthesia. Patients in the direct cohort has significantly higher preoperative VAS scores ($P = .041$), significantly lower SST scores ($P = .02$), and significantly lower ASES scores ($P = .006$) and were also less likely to have confirmatory EMG ($P = .009$). There were otherwise no other differences between groups preoperatively.

There were no significant postoperative differences between the indirect and direct cohorts in rates or return to full-duty work, return to play, resolution of scapular winging, complications, VAS scores, SST scores, ASES scores, or range of motion ($P > .05$ in all cases; Figs. 2 and 3, Table III). There were no significant differences between groups in change in VAS, SST, or ASES scores preoperatively and postoperatively ($P > .05$ in all cases). Within the overall cohort, VAS ($P = .003$), SST ($P = .006$), and ASES ($P < .001$) scores were significantly improved postoperatively compared with preoperative scores (Figs. 2 and 3, Table III). Range of motion was not significantly different between groups ($P > .05$ in all cases). No patients were dissatisfied with the cosmetic appearance of their axillary fold or chest postoperatively.

Discussion

Serratus anterior palsy due to long thoracic neuropathy causes significant shoulder disability with restricted range of motion, loss of strength and endurance, and pain.^{1,2,11,20,22} In those patients who do not recover, serratus transfer of the sternal head of the pectoralis major has been demonstrated to decrease pain, to improve range of motion, and to improve outcomes.^{1-3,6,11,13,14,17,18,20,22} However, it remains unknown whether an indirect technique with interpositional autograft or a direct technique without the use of a graft leads to better outcomes, with each having advantages and disadvantages. The purpose of this study was to understand the optimal technique through a survey of experts, a systematic review of the literature, and a comparative cohort analysis.

Our survey of the ASES membership revealed that no current consensus exists among experts regarding this condition, with surgeons split between donor tendon, surgical technique, and graft type. More experienced surgeons were more likely to use an indirect transfer technique with graft interposition, which could reflect a historical bias within training, given that the direct technique was first described in 2000. Alternatively, experience may have led these surgeons to select the indirect technique.

Within the systematic review, patients who underwent indirect transfer were 4.5 times more likely to develop recurrent medial scapular winging and had a mean of 12° less postoperative active forward elevation. These results were achieved despite a mean length of follow-up 20 months longer for direct transfers and an older

Table III Baseline demographic characteristics and outcome measures for each group in our comparative cohort study as well as for the overall group

Variable	Direct		Indirect		P value	Total	
	Mean	SD	Mean	SD		Mean	SD
Gender (% female)	60	NA	64	NA	.582	63	NA
Manual laborers (%)	20	NA	50	NA	.143	38	NA
Surgery on dominant extremity (%)	60	NA	50	NA	.473	54	NA
Concomitant procedures (%)	10	NA	7	NA	.670	8	NA
Iatrogenic etiology (%)	14	NA	0	NA	.330	8	NA
Idiopathic etiology (%)	21	NA	10	NA	.395	17	NA
Traumatic etiology (%)	64	NA	90	NA	.171	75	NA
EMG positive (%)	93	NA	40	NA	.009	71	NA
Prior shoulder surgery (%)	43	NA	50	NA	.527	46	NA
Age (years)	30	8	30	12	.984	30	10
Time from injury to surgery (years)	3.7	3.9	1.5	0.7	.122	2.4	2.7
Preoperative VAS	7.4	1.6	4.9	2.7	.041	5.7	2.6
Preoperative SST	2.4	3.6	5.4	3.2	.067	4.4	3.6
Preoperative ASES	26	11	51	25	.006	42	24
Preoperative AFE	101	40	131	27	.240	114	37
Preoperative AER	39	28	43	16	.851	41	22
Length of follow-up (years)	3.9	2.3	4.5	2.2	.487	4.3	2.2
Complications (%)	21	NA	10	NA	.437	17	NA
Return to full duty (%)	10	NA	36	NA	1.000	25	NA
Return to full play (%)	0	NA	29	NA	.200	17	NA
Winging resolved (%)	86	NA	93	NA	1.000	90	NA
Postoperative VAS	4.4	2.8	3.7	3.4	.603	4.0	3.0
Postoperative SST	5.9	4.7	7.5	4.0	.378	6.8	4.3
Postoperative ASES	52	29	64	29	.339	59	29
Postoperative AFE	137	50	166	13	.110	155	34
Postoperative AER	55	30	72	16	.175	65	24

SD, standard deviation; NA, not applicable; EMG, electromyography; VAS, visual analog scale score for pain; SST, Simple Shoulder Test score; ASES, American Shoulder and Elbow Surgeons score; AFE, active forward elevation; AER, active external rotation.

P values of <.05 are bolded for emphasis. There were no differences in postoperative outcomes between groups.

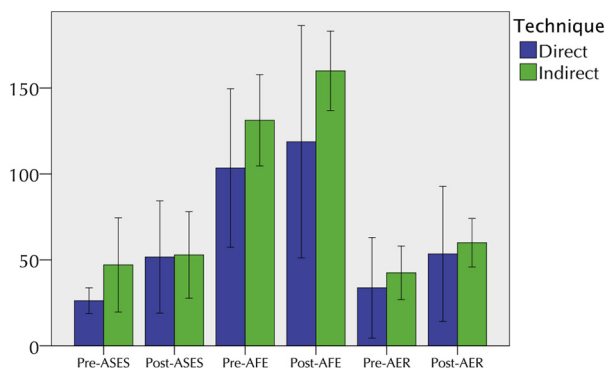


Figure 2 Mean preoperative (*Pre*) and postoperative (*Post*) American Shoulder and Elbow Surgeons (ASES) scores as well as mean active forward elevation (AFE) and active external rotation (AER) (\pm standard deviation) for both direct and indirect groups.

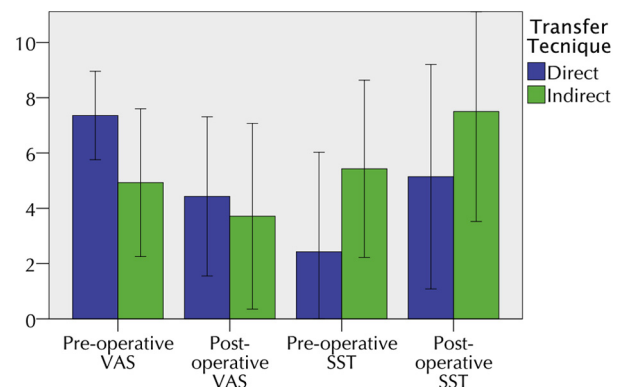


Figure 3 Mean preoperative (*Pre*) and postoperative (*Post*) visual analog scale (VAS) scores for pain and Simple Shoulder Test (SST) scores (\pm standard deviation) for both direct and indirect groups.

population of patients by 5 years. Whereas a difference was also seen in ASES scores, it is not likely to be clinically significant because the minimal clinically important

difference for the ASES score is 12 to 17 points after nonoperative treatment for rotator cuff disease.¹⁹ The Level IV evidence suggests that interpositional grafts are more

likely to attenuate with time and to lead to recurrence of medial scapular winging. Differences in forward elevation may be due to the loss of a stable fulcrum against which the glenohumeral musculature can elevate the humerus.

Within our comparative cohort, no significant differences were observed in functional outcomes, recurrence of winging, or return to work or play. Unfortunately, in both groups, outcome remains guarded, with a final overall ASES score of 59 ± 29 and 54% of patients unable to return to work, which is consistent with the current literature on direct transfers. Superior results to previous studies were seen in our indirect cohort, possibly because tibialis anterior allografts may be more appropriate than fascia lata autografts to avoid winging recurrence, especially in the setting of a heavy laborer intending to return to the pre-injury profession. However, patients should be counseled that even with resolution of winging, pain may be persistent because of either persistence of the underlying neuropathy or inability of the transfer to recreate physiologic scapulothoracic rhythm even with resolution of winging.

Our methodology provides insight into differences between Level III, Level IV, and Level V evidence as all 3 were obtained simultaneously for this condition. Given the relative rarity of this condition even among subspecialist referral practices (91% of survey respondents had seen fewer than 5 cases within the past year), randomized clinical trials may be impossible to perform, and thus the evidence presented here may represent the highest level of evidence attainable. Interestingly, in this case, the Level V evidence and Level III evidence were concordant in their findings of the equivalency of both techniques, whereas the Level IV evidence strongly suggested direct transfer to be superior. Surgeons must be cautious while interpreting Level IV evidence because results are difficult to interpret and to compare between cohorts without a control group, even with standardized outcome measures.

Limitations

This study has several important limitations. Limitations of the survey include a relatively low response rate and recall bias. Limitations of the systematic review include a relative scarcity of clinical studies, which are all Level IV and are heterogeneous. Limitations of the retrospective case series include a small sample size, short-term follow-up, and selection bias. In addition, direct transfers in our comparative cohort were augmented with allograft, whereas those within the systematic review were not, which limits the ability to compare between arms of our study. A post hoc power analysis using ASES scores determined that 146 patients would be necessary to adequately power a randomized clinical trial for this condition. In combination, all of the series published to date include only 131 patients, so it seems unlikely that such a trial will even be conducted, and thus these conditions can be considered effectively equivalent. Our ability to compare those patients with

interpositional tibialis anterior allografts and those with augmentational Achilles allograft is also limited by residual unmeasured bias between the study groups as each comes from an individual surgeon, and thus minor differences in populations of patients, surgical indications, previous procedures, operative technique, and postoperative rehabilitation protocol may play a role in differences seen between groups.

Conclusion

Treatment of long thoracic nerve palsy with split pectoralis major transfer can significantly improve patient-oriented outcomes, but final clinical outcomes remain guarded, and many patients have persistent pain regardless of the transfer technique selected. The highest level of currently available evidence on the topic suggests that both indirect and direct transfers are equivalent in outcomes.

Disclaimer

The authors, their immediate families, and any research foundation with which they are affiliated have not received any financial payments or other benefits from any commercial entity related to the subject of this article.

Supplementary data

Supplementary data related to this article can be found at <http://dx.doi.org/10.1016/j.jse.2014.12.014>.

References

1. Connor PM, Yamaguchi K, Manifold SG, Pollock RG, Flatow EL, Bigliani LU. Split pectoralis major transfer for serratus anterior palsy. *Clin Orthop Relat Res* 1997;341:134-42.
2. Galano GJ, Bigliani LU, Ahmad CS, Levine WN. Surgical treatment of winged scapula. *Clin Orthop Relat Res* 2008;466:652-60. <http://dx.doi.org/10.1007/s11999-007-0086-2>
3. Gozna ER, Harris WR. Traumatic winging of the scapula. *J Bone Joint Surg Am* 1979;61:1230-3.
4. Gregg JR, Labosky D, Harty M, Lotke P, Ecker M, DiStefano V, et al. Serratus anterior paralysis in the young athlete. *J Bone Joint Surg Am* 1979;61:825-32.
5. Herzmark MH. Traumatic paralysis of the serratus anterior relieved by transplantation of the rhomboidei. *J Bone Joint Surg Am* 1951;33:235-8.
6. Icton J, Harris WR. Treatment of winged scapula by pectoralis major transfer. *J Bone Joint Surg Br* 1987;69:108-10.
7. Kuhn J, Plancher K, Hawkins R. Scapular winging. *J Am Acad Orthop Surg* 1995;3:319-25.

8. Lippitt S, Matsen F. Mechanisms of glenohumeral joint stability. *Clin Orthop Relat Res* 1993;291:20-8.
9. Litts CS, Hennigan SP, Williams GR. Medial and lateral pectoral nerve injury resulting in recurrent scapular winging after pectoralis major transfer: a case report. *J Shoulder Elbow Surg* 2000;9:347-9.
10. Meininger AK, Figuerres BF, Goldberg BA. Scapular winging: an update. *J Am Acad Orthop Surg* 2011;19:453-62.
11. Noerdlinger MA, Cole BJ, Stewart M, Post M. Results of pectoralis major transfer with fascia lata autograft augmentation for scapula winging. *J Shoulder Elbow Surg* 2002;11:345-50. <http://dx.doi.org/10.1067/mse.2002.124525>
12. Parsonage MJ, Turner JWA. Neuralgic amyotrophy; the shoulder-girdle syndrome. *Lancet* 1948;1:973-8.
13. Perlmutter GS, Leffert RD. Results of transfer of the pectoralis major tendon to treat paralysis of the serratus anterior muscle. *J Bone Joint Surg Am* 1999;81:377-84.
14. Post M. Pectoralis major transfer for winging of the scapula. *J Shoulder Elbow Surg* 1995;4:1-9.
15. Povacz P, Resch H. Dynamic stabilization of winging scapula by direct split pectoralis major transfer: a technical note. *J Shoulder Elbow Surg* 2000;9:76-8.
16. Radin EL. Peripheral neuritis as a complication of infectious mononucleosis. Report of a case. *J Bone Joint Surg Am* 1967;49:535-8.
17. Steinmann SP, Wood MB. Pectoralis major transfer for serratus anterior paralysis. *J Shoulder Elbow Surg* 2003;12:555-60. [http://dx.doi.org/10.1016/S1058-2746\(03\)00174-5](http://dx.doi.org/10.1016/S1058-2746(03)00174-5)
18. Streit JJ, Lenarz CJ, Shishani Y, McCrum C, Wanner JP, Nowinski RJ, et al. Pectoralis major tendon transfer for the treatment of scapular winging due to long thoracic nerve palsy. *J Shoulder Elbow Surg* 2012;21:685-90. <http://dx.doi.org/10.1016/j.jse.2011.03.025>
19. Tashjian RZ, Deloach J, Green A, Porucznik CA, Powell AP. Minimal clinically important differences in ASES and simple shoulder test scores after nonoperative treatment of rotator cuff disease. *J Bone Joint Surg Am* 2010;92:296-303. <http://dx.doi.org/10.2106/JBJS.H.01296>
20. Tauber M, Moursy M, Koller H, Schwartz M, Resch H. Direct pectoralis major muscle transfer for dynamic stabilization of scapular winging. *J Shoulder Elbow Surg* 2008;17(Suppl):29S-34S. <http://dx.doi.org/10.1016/j.jse.2007.08.003>
21. Vastamäki M, Kauppila LI. Etiologic factors in isolated paralysis of the serratus anterior muscle: a report of 197 cases. *J Shoulder Elbow Surg* 1993;2:240-3.
22. Warner JJ, Navarro RA. Serratus anterior dysfunction. Recognition and treatment. *Clin Orthop Relat Res* 1998;349:139-48.
23. Wiater JM, Flatow EL. Long thoracic nerve injury. *Clin Orthop Relat Res* 1999;368:17-27.