

# Clinical Indications and Techniques for the Use of Platelet-Rich Plasma in the Shoulder

Nickolas Garbis, MD,\* Anthony A. Romeo, MD,\* Geoffrey Van Thiel, MD, MBA,\*  
Neil Ghodadra, MD,\* Matthew T. Provencher, MD,<sup>†</sup> Brian J. Cole, MD, MBA,\* and  
Nikhil Verma, MD\*

Platelet-rich plasma (PRP) has recently been a topic of significant interest in the orthopedic community. In addition to the numerous basic science studies regarding the *in vitro* effects of PRP, there is more literature regarding the use of PRP in the clinical setting. PRP is overall very safe and carries minimal risk for the patient, making it appealing even if there is a small improvement in the final outcome. There appears to be significant interest in using it in the shoulder, particularly in conjunction with rotator cuff repair. We briefly outline the basics of PRP and discuss a few potential operative and nonoperative indications, such as rotator cuff tendinitis, biceps tendinitis, rotator cuff tears, and superior labrum anterior-posterior lesions.

Oper Tech Sports Med 19:165-169 © 2011 Elsevier Inc. All rights reserved.

**KEYWORDS** platelet-rich plasma, superior labrum anterior-posterior, rotator cuff tear, biologic augmentation, operative technique

Different techniques for incorporating platelet-rich plasma (PRP) into a rotator cuff repair, such as direct injection and suture fixation, are described as well as other variations that may be used. There is still a significant amount of clinical research that needs to be performed regarding the routine use of PRP and to delineate which method, if any, seems to provide the best delivery of growth factors to the site of interest.

The use of PRP has been a topic of recent interest in the orthopedic community. PRP has been used successfully in other fields of medicine such as plastic surgery and maxillofacial surgery before its use in musculoskeletal care. In addition, there have been numerous basic science publications studying the effect of PRP on the healing cascade. However, at the time of this publication, there have been very few trials involving the results of PRP use in the clinical setting. Most have been limited to basic case series or case reports.<sup>1-8</sup> The goal of this article is to provide a basic review of the rationale and techniques of using PRP in the shoulder. In addition, we would like to describe methods that can be used by the prac-

itioner both in the operative and nonoperative treatment of shoulder pathology.

## Basics of PRP

The use of PRP was first described in the early 1990s. Many of the first applications of PRP were in maxillofacial<sup>9</sup> and plastic surgery.<sup>10</sup> It was postulated that the platelets in PRP led to faster healing times with the release of growth factors locally. The active components in PRP are believed to be transforming growth factor- $\beta$ , basic fibroblast growth factor, platelet-derived growth factor, epidermal growth factor, vascular endothelial growth factor, and connective tissue growth factor.<sup>11</sup> These are all believed to be active in the healing process.

Although there are several PRP systems available on the market, the basic procedure for obtaining the PRP remains the same. Usually, a certain volume of peripheral venous blood is obtained from the patient depending on the particular preparation system used. The blood is then placed into a centrifuge and allowed to separate. The red blood cells move to the bottom of the tube. The platelet-poor plasma remains at the top of the tube. In between the 2 layers, the platelets and white blood cells separate into the "buffy coat." This is what is used for PRP injections. It can be combined with either calcium chloride or thrombin to activate the platelets before applying to the target site. Activation can also form a clot, which makes it easier to handle the PRP and suture it in place if necessary.

\*Rush University Medical Center, Chicago, IL.

<sup>†</sup>Naval Medical Center, San Diego, CA.

Address reprint requests to Anthony A. Romeo, MD, Rush University Medical Center, 1611 W Harrison, Chicago, IL 60612. E-mail: [shoulderelbowdoc@gmail.com](mailto:shoulderelbowdoc@gmail.com)

## Nonsurgical Indications for PRP in the Shoulder

At the time of this publication, there were no articles found in our literature search regarding nonoperative treatment of shoulder conditions with PRP. However, multiple shoulder surgeons do have anecdotal experience with the use of PRP in the nonoperative management of subacromial inflammation. Theoretically, PRP may have a future role in the management of superior labrum anterior-posterior (SLAP) lesions and long head of the biceps tendonitis, chronic rotator cuff tendinopathy, and partial-thickness rotator cuff tears.

To determine a potential role for PRP in the conservative management of shoulder pathology and direct future research, an extrapolation must be made from the limited data available regarding its other uses. There have been many studies on the PRP treatment of chronic tendinopathies, such as lateral epicondylitis and Achilles tendon pathology. In a study by Mishra et al,<sup>12</sup> 20 patients who had persistent lateral epicondylitis symptoms for a mean of 15 months were given either a PRP injection or a bupivacaine injection. The cohort of patients who received the PRP injection had a 60% improvement in their visual analog pain scores at 8 weeks compared with a 16% improvement in the control group.

More recently, Peerbooms et al<sup>13</sup> published a randomized controlled trial comparing corticosteroid injections with PRP in chronic lateral epicondylitis. There were 51 patients in the PRP group and 49 in the corticosteroid group. At 1 year, their results showed that the PRP group was significantly better in regards to visual analog scale (VAS) scores and DASH score compared with corticosteroids.

There has also been some investigation into using PRP in Achilles tendinosis. Gaweda et al<sup>14</sup> treated 15 Achilles tendons with autologous PRP injections and followed them at 6 weeks and then 3, 6, and 18 months. They had statistically significant improvement at 3 months. In a randomized controlled trial recently published by De Vos et al,<sup>15</sup> there was no significant difference found at 2 years between patients randomized to either a saline injection or to PRP.

Overall, PRP plasma use for the conservative management of shoulder pathology has not been frequently used or reported in the literature. However, PRP has been used for a limited number of conditions in specific patient populations. More specifically, because of concerns about steroid use around healthy/intact tendons, PRP injection has been reported in high-level athletes with subacromial inflammation. This use highlights the need for further studies. Basic science has shown us that PRP formulations are both varied and effective in a variety of situations. Applications for conservative management will continue to be refined and expanded.

## Surgical Indications for PRP in the Shoulder

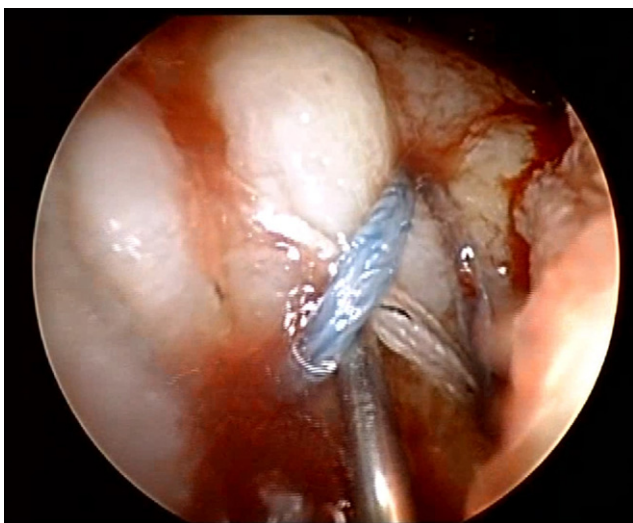
PRP has experienced a recent growth in surgical indications and use. As of now, the major orthopedic Food and Drug Administration (FDA)-approved application of PRP is for

combination with allograft or autograft bone before implantation. It is also FDA approved for the treatment of nonhealing diabetic ulcers. The other uses of PRP discussed here are off-label uses. Most of the data available consists of relatively small case series that do not give a definitive answer to the efficacy of PRP. A lack of power in each study does contribute to the variety of conclusions, but, perhaps more importantly, there is a significant difference in the PRP preparation procedure, composition, and surgical technique used. This creates a heterogeneous grouping of studies that are often viewed as "similar." Regardless, these initial results are important in the establishment of a framework for future research.

In a presentation by Weber et al,<sup>16</sup> at the American Association of Orthopedic Surgeons (AAOS) meeting, they described the use of PRP during arthroscopic rotator cuff repair. Their study was designed as a randomized controlled trial on the basis that 30 patients were needed in both the treatment group and control group to determine a 20% difference in postoperative pain scores. There were no significant differences in narcotic use and outcome scores between the 2 groups. In regards to the imaging studies, patients from both groups had residual defects. The technique used to incorporate the PRP into the cuff repair was described by Gamradt et al.<sup>17</sup> A shoulder arthroscopy was performed in the beach chair position, and, after appropriate mobilization of the rotator cuff tear, a doubly loaded suture anchor was placed into the decorticated insertion. The sutures were then passed through the tendon in either a simple or a mattress configuration. The PRP was passed onto 1 limb of the suture and pushed through an 8.25-mm cannula with the diaphragm removed. Once the PRP was at the level of the anchor, the sutures were tied down, and the PRP was incorporated into the bone-tendon interface. This article only described a technique, and no clinical outcomes were reported.

Maniscalco et al<sup>1</sup> described a similar method for using PRP in rotator cuff tears. Specifically, they used the "Cascade" system in conjunction with a shoulder arthroscopy and mini-open rotator cuff repair. The supraspinatus tendon had retracted significantly in their case, and the 10-mm gap was bridged with the Cascade membrane. They found favorable results after surgery, with magnetic resonance imaging showing an intact tendon and the constant score rising from 56 to 96 after 6 months. Unfortunately, this was an isolated case and had no control available with which to compare it.

The previous articles discussed attempted to have the PRP clot applied directly to the bone-tendon interface via suture fixation. Randelli et al<sup>8</sup> used a different method to apply PRP to rotator cuff repairs. Their group enrolled 14 patients who were undergoing rotator cuff repair to participate and evaluate the safety of using PRP with arthroscopy. The patients had their tear repaired arthroscopically with anchor fixation, and then all arthroscopic fluid was drained from the subacromial space. The PRP was then sprayed into the shoulder through one of the inflow cannulas along with thrombin, and the clot formed inside the subacromial space. A total of 100 mL of air was then injected into the subacromial space, and a dry check of the clot with the camera was performed. Patients were followed up for a minimum of 2 years after their surgery.



**Figure 1** Injecting PRP under a rotator cuff repair with an 18 gauge needle under arthroscopic visualization.

Their VAS, Constant, and University of California Los Angeles (UCLA) scores all improved at the time of follow-up. Their VAS score improved from 5.31 preoperatively to 0.57, 1.29, and 1.00 at 6, 12, and 24 months, respectively ( $P < .001$ ). The UCLA score and Constant score improved from 16.54 to 32.94 and 54.62 to 85.23 at 24 months, with  $P < .001$ . The authors did recognize that a prospective randomized controlled trial is needed to adequately compare the PRP-treated group with a control. In terms of safety, no adverse complications were reported postoperatively.

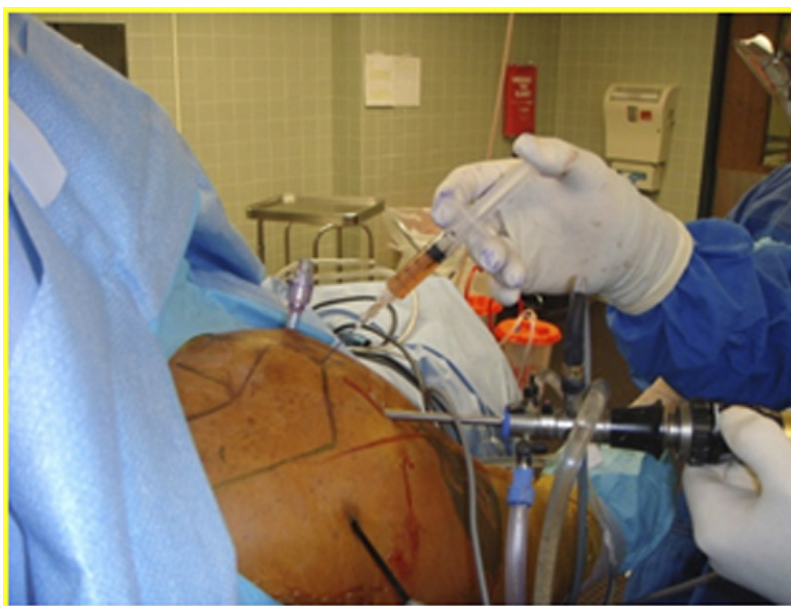PRP has also been used in open subacromial decompression. Everts et al<sup>4</sup> randomized 40 patients with shoulder impingement syndrome with no rotator cuff tear to an open subacromial decompression with either PRP injected at the end or no PRP. After the osteophytes were removed from the

acromion and the undersurface smoothed with an oscillating saw, the deltoid was reattached, and the wound was closed over a blunt cannula left in the subacromial space. Those patients in the PRP group received a 10-mL injection into the subacromial space and then 3 mL into the subcutaneous tissues. At 3 months, the authors found a significant difference between the 2 groups. The PRP-treated patients used less pain medication, had a better range of motion ( $P < .001$ ), and were able to return to their activities of daily living faster than the control group (return at 4 vs 6 weeks,  $P < .05$ ).

## Authors' Operative Technique

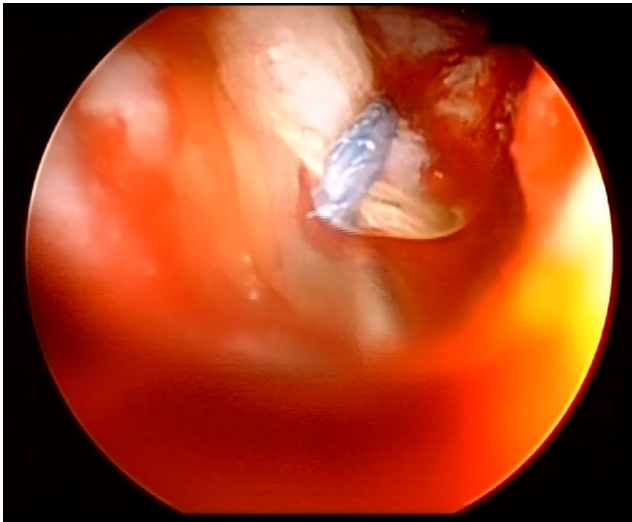
There are a number of different methods available in regards to using PRP in the shoulder. At this time, it is unclear which method is ideal, and techniques vary among surgeons. Later we provide a basic technique that can be applied to rotator cuff tears. A similar method is used for other operative procedures that involve tendon to tendon or tendon to bone healing, such as SLAP repair, intratendinous cuff tears, and subscapularis tendon repair during shoulder arthroplasty. Our preference is to use PRP in a syringe without activator or a matrix. To date, there have been no studies that have determined whether there are changes in the elution of growth factors when the PRP is in a matrix form.

Although both the beach chair and lateral decubitus positions have been described for rotator cuff repair surgery, we prefer to place the patient in a beach chair position to facilitate visualization of rotator cuff reduction. Before prepping and draping of the arm, a tourniquet is placed on the forearm, and an alcohol pad is used to prepare the most visible vein on the dorsum of the hand. Approximately 20 cm<sup>3</sup> of venous blood is drawn from the patient with a 22-G butterfly needle and prepared according to the manufacturer's guidelines. Although the withdrawn blood is being prepared, rotator cuff



**Figure 2** Insertion of syringe with PRP into rotator cuff repair under visualization.





**Figure 3** After injection, a “yellow haze” of PRP can be seen in the joint and surrounding the repair.

repair is performed arthroscopically using suture anchor fixation. After completion of the repair, the arthroscope is inserted into the lateral portal to provide optimal visualization of the repair construct and, specifically, the rotator cuff tendon–humeral bone interface. At this point, the arthroscopic fluid inflow is turned off, and all arthroscopic fluid is drained from the shoulder. An 18-G spinal needle is inserted approximately 1.5 cm anterior to the lateral portal at approximately a 15° angle to allow penetration into the repair site (Fig. 1). The spinal needle should be placed under the rotator cuff tendon and inserted below the repair construct until the humerus is abutted. Once the needle tip is against the humeral bony surface, it is withdrawn a few millimeters, and the PRP is drawn up and attached to the needle (Fig. 2). The PRP is then injected under direct visualization as a “yellow haze” of PRP is seen in the joint (Fig. 3). Once the PRP has been injected, no more arthroscopic fluid is used, the arthroscope is removed, and the portals are closed with a monofilament suture.

There are also alternative methods of fixation or application of the PRP. Our description is a simple “squirt” method. As mentioned earlier, other surgeons use suture-based clot application and fixation. This is usually facilitated by penetrating a PRP clot with a needle and threading the clot onto a suture. The suture is then used to hold the clot in place.

The PRP can also be sutured in place as described in the article by Maniscalco et al.<sup>1</sup> In this situation, the patient’s blood is spun down, and the PRP is formed into a membranous disk. This material is suturable and pliable and can be

used to span defects. There is also the option of soaking an allograft in PRP before implantation in the shoulder for tissue augmentation although we have no experience with this procedure.

## Discussion/Future Directions

Most of the literature available regarding PRP use in the shoulder is largely anecdotal and in the form of case series. Intuitively, basic science research does suggest that there may be an augmentation of the healing process and/or a decrease in the inflammatory response when using PRP. However, further research is needed to elucidate the efficacy and specific situations that benefit from PRP.

There are multiple limitations to the use of PRP in the shoulder. Many of these are simply a result of the operative technique. It is often difficult to ensure that the PRP is delivered to the appropriate area. Some techniques involve fixing a clotted PRP membrane to the tendon/bone interface by capturing it with a suture. When the suture is tightened, there is potential to saw through the PRP clot and lose the clot in the shoulder. The other option can be to inject the PRP into the site of repair, but this also can lead to an inadequate amount remaining at the desired site. Any PRP placed into a repair in the shoulder also has the potential to be washed away simply by not having the inflow fluid turned off all the way or inadvertently leaving the suction on.

This lack of clarity in the clinical application of PRP is compounded by the fact that there are numerous formulations available on the market and a variety of techniques and uses aimed at reaching the same goal. This creates an environment in which cross-study comparison is difficult. Nonetheless, expert opinion continues to drive the proliferation of PRP use in orthopedics.

Given the lack of multiple clinical trials, it would be difficult for us to support or oppose the use of PRP in the treatment of shoulder disorders based solely on the research available. When deciding whether or not to inject PRP, one must keep in mind that it is FDA approved for mixing with allograft bone only. With that being said, it does appear that there is some preliminary work that is promising, and basic science results strongly suggest a potential clinical and surgical use. Most of the potential uses we see are in regards to tendon to bone healing. In trying to extrapolate potential nonoperative uses, several disorders and clinical questions should be addressed (Table 1).

On the surgical side, there are multiple potential uses for PRP in the shoulder. The most discussed one is improving the healing of the rotator cuff. Potential avenues to explore in-

**Table 1** Potential Nonoperative Indications for PRP Use

Partial-Thickness Rotator Cuff Tears	Will PRP Accelerate Healing of Tendon?
SLAP tears	Will PRP accelerate healing of labrum to bone?
Long head of the biceps tendonitis	Can PRP decrease inflammation in the tendon?
Chronic rotator cuff tendinopathy	Can PRP stimulate tendon healing when injected into tendinotic area?
Rotator cuff tendonitis/impingement syndrome	Will PRP accelerate healing of tendon or decrease inflammation?

**Table 2 Potential Operative Indications for PRP Use**

<b>Rotator Cuff Repair</b>	<b>Will PRP Help Tendon to Heal to Bone?</b>
<b>SLAP repair</b>	<b>Will PRP help labrum heal to bone?</b>
<b>Subacromial decompression/acromioplasty</b>	<b>Can PRP help speed recovery?</b>
<b>Open shoulder procedures</b>	<b>Can PRP lead to lower blood loss and less stiffness?</b>

clude either improving the healing potential of native tendon to bone or possibly improving the incorporation of biological augmentation into cuff repairs (ie, rotator cuff allograft, acellular dermal matrix, and so on) (Table 2).

In summary, there are many different potential uses of PRP in the shoulder. None have been validated with multiple large randomized controlled trials. Although there are some side effects of PRP use, such as local injection reaction and swelling, they seem to be minimal, and the benefits could potentially outweigh the risks. One risk to keep in mind is that the activation of PRP often involves using calcium chloride and bovine thrombin. High doses of bovine thrombin have been shown to cause cross-reactivity to human factor V and can potentially induce antibodies.<sup>18</sup> The doses and type of bovine thrombin used in commercial systems should not be an issue.

Most surgeons look at the risk-to-benefit ratio before making an operative or nonoperative decision. If the risk of a PRP injection does not pose significant poor consequences but may influence a positive outcome because of accelerated healing, many surgeons may choose to use PRP despite having data to justify its use or cost to the health care system.

## References

- Maniscalco P, Gambera D, Lunati A, et al: The "Cascade" membrane: A new PRP device for tendon ruptures. Description and case report on rotator cuff tendon. *Acta Biol Med* 79:223-226, 2008
- Arnoczky SP, AL, Fanelli G, et al: The role of platelet-rich plasma in connective tissue repair. *Orthop Today* 26, 2009 Available at: <http://www.orthosupersite.com/view.aspx?rid=37598>
- Cheung EV, Silverio L, Sperling JW: Strategies in biologic augmentation of rotator cuff repair: A review. *Clin Orthop Relat Res* 468:1476-1484, 2010
- Everts PA, Devilee RJJ, Brown-Mahoney C, et al: Exogenous Application of Platelet-Leukocyte Gel during Open subacromial Decompression Contributes to Improved Patient Outcome. *Eur Surg Res* 40:203-210, 2008
- Hall MP, Band PA, Meislin RJ, et al: Platelet-rich plasma: Current concepts and application in sports medicine. *J Am Acad Orthop Surg* 17:602-608, 2009
- Lopez-Vidriero E, Goulding KA, Simon DA, et al: The use of platelet-rich plasma in arthroscopy and sports medicine: Optimizing the healing environment. *Arthrosc J Arthroscopic Relat Surg* 26:269-278, 2010
- Lubowitz JH, Poehling GG. Shoulder, hip, knee, and PRP. *Arthroscopy* 26:141-142, 2010
- Randelli PS, Arrigoni P, Cabitza P, et al: Autologous platelet rich plasma for arthroscopic rotator cuff repair. A pilot study. *Disabil Rehabil* 30: 1584-1589, 2008
- Freymler EG, Aghaloo TL: Platelet-rich plasma: Ready or not? *J Oral Maxillofac Surg* 62:484-488, 2004
- Man D, Plosker H, Winland-Brown JE: The use of autologous platelet-rich plasma (platelet gel) and autologous platelet-poor plasma (fibrin glue) in cosmetic surgery. *Plast Reconstr Surg* 107:229-237, 2001
- Everts PA, Knape JT, Weibrich G, et al: Platelet-rich plasma and platelet gel: A review. *J Extra Corpor Technol* 38:174-187, 2006
- Mishra A, Pavelko T: Treatment of chronic elbow tendinosis with buffered platelet-rich plasma. *Am J Sports Med* 34:1774-1778, 2006
- Peerbooms JC, Sluimer J, Bruijn DJ, et al: Positive effect of an autologous platelet concentrate in lateral epicondylitis in a double-blind randomized controlled trial. *Am J Sports Med* 38:255-262, 2010
- Gaweda K, Tarczyska M, Krzyzanowski W: Treatment of Achilles tendinopathy with platelet-rich plasma. *Int J Sports Med* 31:577-583, 2010
- de Vos RJ, Weir A, van Schie HT, et al: Platelet-rich plasma injection for chronic Achilles tendinopathy: A randomized controlled trial. *JAMA* 303:144-149, 2010
- Weber SC, Kauffman JL, Parise C, et al. Platelet-rich fibrin-membrane in arthroscopic rotator cuff repair: A prospective, randomized study. Paper presented at: American Academy of Orthopedic Surgeons Annual Meeting. 3/10/2010, New Orleans, LA
- Gamradt SC, Rodeo SA, Warren RF: Platelet rich plasma in rotator cuff repair. *Tech Orthop* 22:26-33, 2007
- Alsousou J, Thompson M, Hulley P, et al: The biology of platelet-rich plasma and its application in trauma and orthopaedic surgery: A review of the LITERATURE. *J Bone Joint Surg Br* 91-B:987-996, 2009