

# Rotator Cuff Repair

## Massive Tears

*Allison McNickle, MD; Champ Baker, MD; and Brian Cole, MD*

### SURGICAL GOALS

Massive rotator cuff tears have been variably defined as tears exceeding greater than 5 cm in diameter<sup>1</sup> or involving the detachment of at least 2 entire tendons.<sup>2</sup> Though once requiring open repair techniques, the vast majority of massive rotator cuff tears can now be managed arthroscopically.<sup>3-7</sup> Successful arthroscopic treatment of massive rotator cuff tears depends upon tear pattern recognition, tendon mobilization, and margin convergence (when necessary) to create a tension-free tendon-to-bone interface and a biomechanically stable repair construct that balances forces in the transverse and coronal planes.

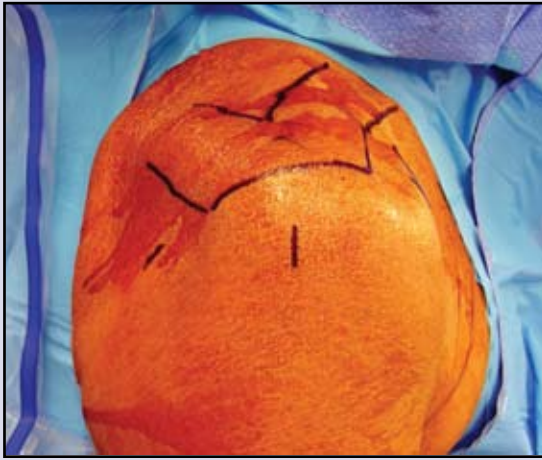
Burkhart and Lo have recognized 4 major types of full-thickness rotator cuff tears.<sup>8</sup> Crescent tears can be easily reapproximated to the prepared greater tuberosity and repaired under minimal tension. U-shaped tears extend medially, occasionally to the level of the glenoid rim. These types of tears have minimal medial-to-lateral mobility but demonstrate sometimes surprising posterior-to-anterior mobility. Using the principle of margin convergence, sequential side-to-side sutures are placed in the anterior and posterior leaves of the tear.<sup>9</sup> As these sutures are tied from medial to lateral, the free ends of the tear converge to the anatomic insertion. This margin can then be anatomically reduced to the prepared footprint and repaired under minimal tension similar to a crescent-type repair. L-shaped tears have both longitudinal and transverse components. Leaf mobility in an L-shaped tear is unequal—one flap will be easier to reapproximate in the anterior-posterior direction and facilitate footprint reattachment. This more mobile leaf forms the corner of the repair to the tuberosity. The longitudinal split component is reapproximated with side-to-side sutures followed by repair of the converged transverse margin to the greater tuberosity. Massive, contracted immobile rotator cuff tears are characterized as having severely retracted margins and minimal movement in both medial-to-lateral and anterior-to-posterior planes.<sup>6</sup>

Adequate tendon mobilization and margin convergence techniques for U-shaped and L-shaped tears, is critical for reducing tension and strain at the repair margin. Adequate tendon mobilization is achieved by releasing all adhesions between the tendon and capsule in addition to bursal adhesions between the rotator cuff, acromion, and deltoid. For the rare massive, immobile rotator cuff tears, additional releases, such as anterior and posterior interval slides are performed to increase medial to lateral mobility and obtain a repair under minimal tension.<sup>6</sup>

Balancing force couples in the transverse and coronal planes is of utmost importance in the repair of the massive rotator cuff tear.<sup>8</sup> If possible, our preference is to completely restore the anatomic footprint without excessive tension. Alternatively, a partial repair of the posterosuperior

## PORTALS

- The acromion, AC joint, lateral aspect of the clavicle, and coracoid are outlined on the skin to facilitate proper portal placement, as soft tissue swelling can make delayed palpation of the bony landmarks difficult. Four standard portals are typically used during arthroscopic rotator cuff repair (posterior, lateral, anterior, and anterolateral) (Figure 8-1).



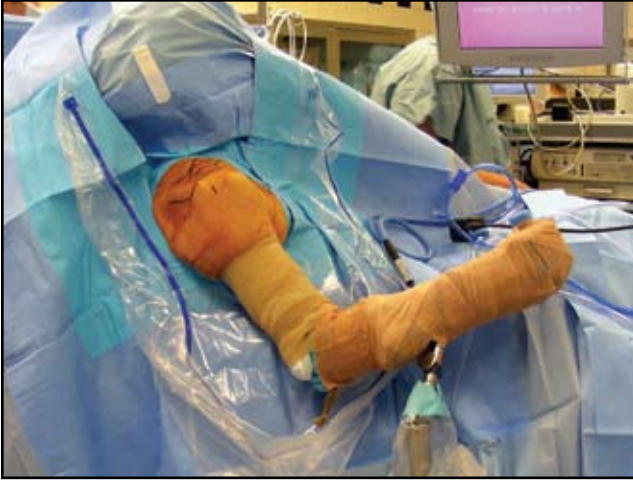**Figure 8-1.** Portal placement. The posterior portal is typically 2 cm inferior and 1 cm medial to the posterolateral border of the acromion. The lateral portal is marked approximately 3 cm lateral to the lateral border of the acromion in line with the posterior border of the clavicle. The anterior portal is marked just lateral to the outlined coracoid.

rotator cuff that restores the posterior moment and balance of the transverse force couple still provides a favorable outcome.<sup>10</sup>

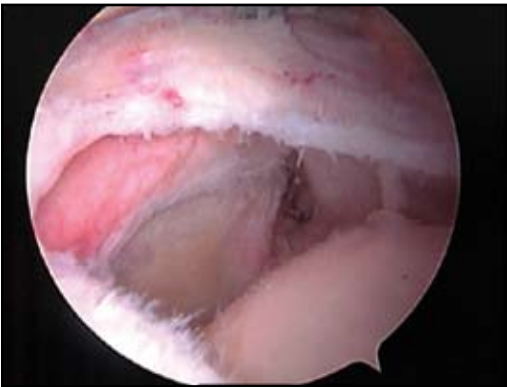
The appropriate repair construct has been a subject of considerable debate. If tendon mobility allows, we currently prefer to perform a transosseous-equivalent repair for massive rotator cuff tears based upon recent studies detailing the biomechanics and footprint contact characteristics of the construct.<sup>11,12</sup> Regardless of the type of construct utilized, the surgeon should adhere to the principles of appropriate tear pattern recognition, tendon mobilization, margin convergence when necessary, balances of force couples, and good arthroscopic knot tying techniques to ensure both knot and loop security.<sup>13</sup>

## OPERATIVE STEPS

- \* Patients are placed in the beach chair position. Anesthesia is induced, generally with a combination of intrascapular block and intravenous sedation. The involved upper extremity is draped to allow full access to the anterior and posterior aspects of the shoulder. We have found the use of a commercial arm holder (eg, Spyder Arm Holder [Tenet Medical, Calgary, Canada]) invaluable in maintaining the arm in the proper position during the procedure (Figure 8-2).
- \* The arthroscope is inserted through the posterior portal and a complete glenohumeral diagnostic arthroscopy is performed. An anterior working portal is created in the rotator interval with an outside-in technique. Associated intra-articular pathology is documented and addressed as indicated.

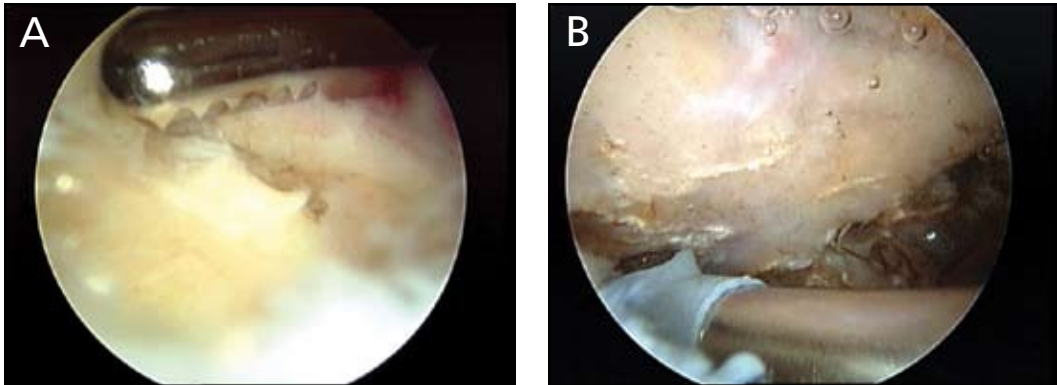


**Figure 8-2.** Patient positioning. The patient is draped in the beach chair position. The entire scapula should be off the edge of the table to provide adequate access to the posterior shoulder during the procedure. A pneumatic arm holder facilitates positioning and provides slight traction.

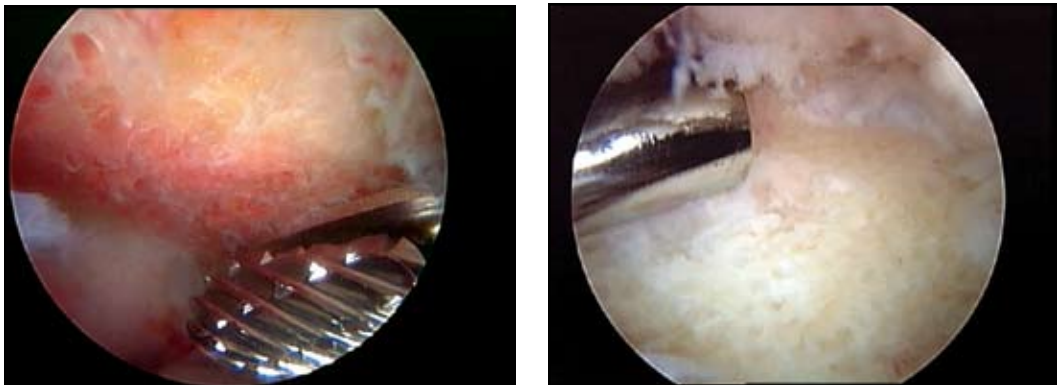


**Figure 8-3.** Massive tear. This U-shaped cuff tear is visualized from the posterior portal.

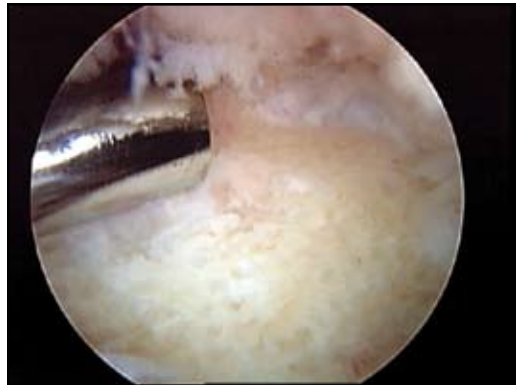- \* After completion of the glenohumeral portion of the procedure, the arthroscope is withdrawn from the joint. The scope sheath and trocar are then directed into the subacromial space through the posterior portal and out the anterior portal incision. A 5.5-mm plastic outflow cannula is placed over the scope sheath, which is then withdrawn into the center of the subacromial space. The arthroscope is then inserted through its sheath and the outflow cannula and scope sheath are gently separated under direct visualization. The lens is rotated to look laterally, and the lateral portal is created after localization with a spinal needle parallel to the undersurface of the acromion and in line with the posterior border of the clavicle.
- \* A thorough subacromial bursectomy is required to identify the margins of the rotator cuff tear prior to classification and mobilization. While viewing from the posterior portal, a 4.5-mm lateral shaver is utilized to resect the bursal and fibrofatty tissue overlying the rotator cuff. Hemostasis is achieved with a bipolar electrofrequency device during removal of the vascular bursal tissue. With adequate resection of the bursa, the surgeon is able to delineate and debride the anterior and medial margins of the tear (Figure 8-3).
- \* Exposure of the lateral and anterior subacromial gutters is performed. Thorough lateral gutter debridement is critical for visualization of the greater tuberosity and future anchor placement. The greater tuberosity footprint is cleared of soft tissue with the shaver or alternatively the radiofrequency device.



**Figure 8-4.** Subacromial bursectomy. The soft tissue is resected using a shaver (A) with a bipolar electrocautery device (B) utilized to achieve hemostasis.

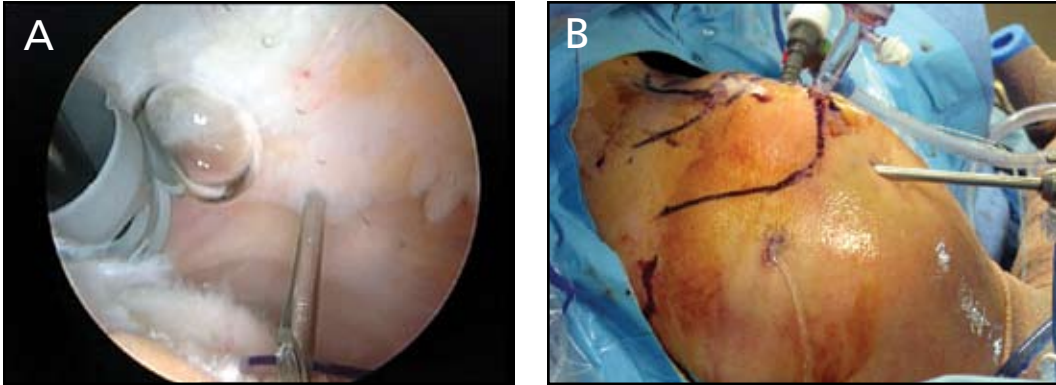


**Figure 8-5.** Acromioplasty. The undersurface of the acromion is prepared with a burr using a cutting block technique.

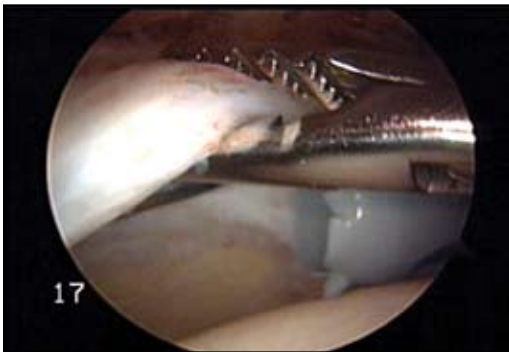


**Figure 8-6.** Footprint preparation. The greater tuberosity is gently debrided with a burr without decorticating the surface.

- \* Viewing from the lateral portal, the posterior gutter and rotator cuff are debrided from the posterior portal (Figure 8-4). The subacromial decompression increases repair workspace and removes impinging acromial osteophytes. For massive rotator cuff tears, every attempt is made to preserve the CA ligament. If necessary, a cutting block technique with the burr placed posteriorly is utilized to convert the acromion to a type 1 (Figure 8-5).
- \* The footprint of the greater tuberosity is debrided to a bleeding surface with an acromial burr in the posterior portal. Though debridement optimizes the healing environment, decortication decreases anchor fixation and is avoided (Figure 8-6).
- \* A spinal needle is used to localize the anterolateral portal directly over the prepared greater tuberosity bed (Figure 8-7). An 8.25-mm threaded plastic cannula is inserted. The arm is placed in a position of slight forward elevation and external rotation with gentle traction by the arm holder. This portal is established as vertical as possible adjacent to the anterolateral acromial border.
- \* Viewing from the lateral portal, rotator cuff tear pattern, mobility, and extent are evaluated.<sup>6</sup> A grasper is introduced from the anterior portal and alternatively the posterior portal to assess the mobility of the rotator cuff in both the medial-to-lateral and the anterior-to-posterior planes (Figure 8-8). No cannula is inserted in the posterior portal.

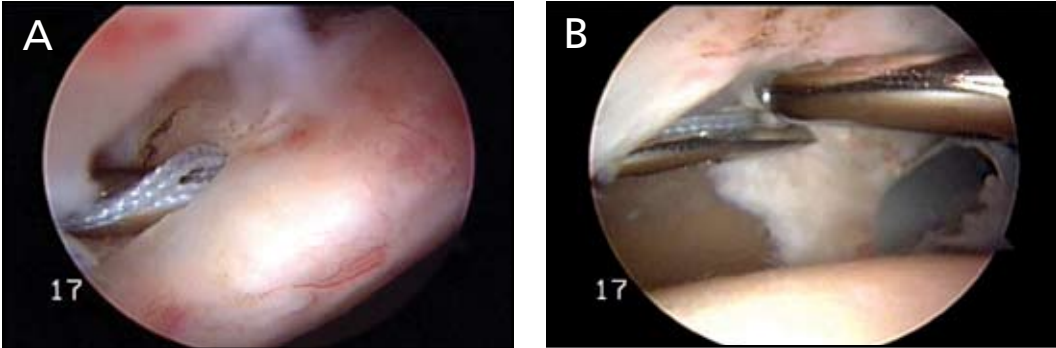


**Figure 8-7.** Anterolateral portal. (A) The working portal is localized with a spinal needle. (B) Externally, the portal is located just anterior and lateral to the border of the acromion (clear cannula).

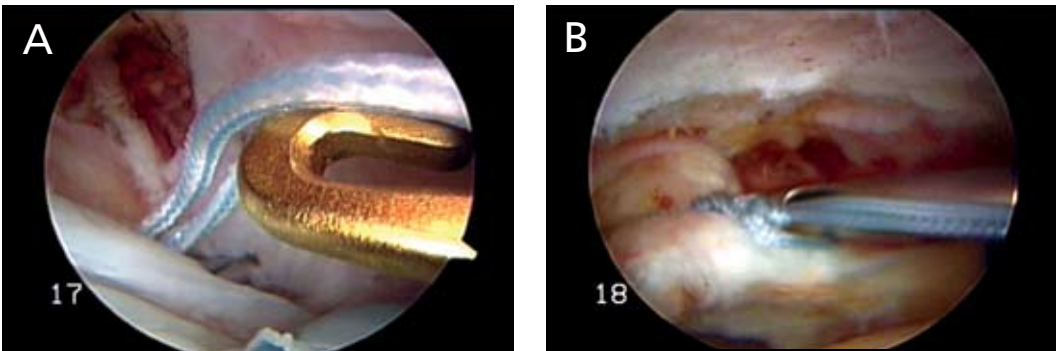


**Figure 8-8.** Grasper on cuff. The grasper is utilized to assess cuff mobility in addition to stabilizing the tendon during suture passing and retrieval.

- \* Cuff excursion can be increased with release of bursal adhesions between the rotator cuff and medial acromion with the use of a radiofrequency device. In addition, an arthroscopic elevator is useful to release the tendon capsule interface above the superior labrum and glenoid neck. This can safely be performed beginning at the level of the rotator interval and progressing posteriorly to the level of the scapular spine. Care must be taken to avoid dissection more than 2 cm medial to the glenoid edge to avoid neurovascular injury. What is the most common “release” that the author utilizes to increase excursion? Release of bursal adhesions alone typically provides sufficient mobility of the rotator cuff. If needed, we then proceed with release of the tendon capsule interface.
- \* For massive L-shaped or U-shaped tears, the first step is placement of side-to-side sutures between the anterior and posterior leaves of the tear. With the arthroscope in the lateral portal, a Penetrator suture passer (Arthrex Inc, Naples, FL) loaded with #2 FiberWire (Arthrex Inc) is brought in through the posterior portal. No cannula is utilized. The suture passer pierces the posterior leaf just lateral to the apex of the cuff tear (Figure 8-9A).
- \* A tendon grasper is brought in from the anterior portal and stabilizes the anterior leaf of the rotator cuff. The Penetrator then passes through the anterior leaf just lateral to the apex of the tear (Figure 8-9B). The grasper then pulls the passed suture out through the anterolateral cannula. The posterior suture limb is also retrieved through the anterolateral cannula with a crochet hook (Figure 8-10A) and an arthroscopic Revo knot is tied (Figure 8-10B).

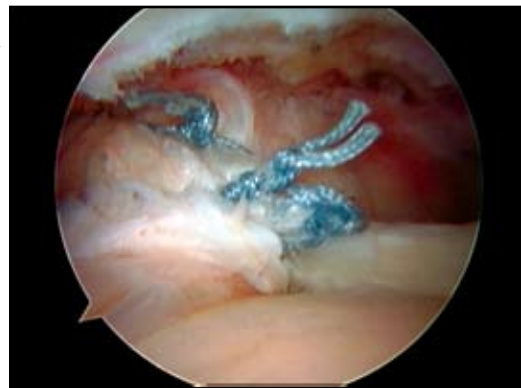

**Figure 8-9.** Side-to-side suturing—posterior leaf. (A) The Penetrator device, loaded with #2 FiberWire, pierces the posterior leaf with a superior-to-inferior trajectory. (B) The anterior leaf is stabilized with a grasper as the Penetrator is passed from the inferior-to-superior aspect.

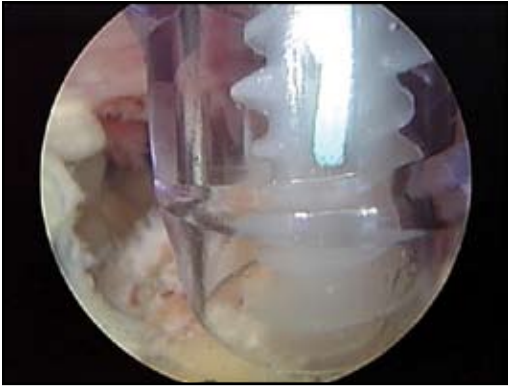


**Figure 8-10.** Suture retrieval. (A) A crochet hook is used to pull both suture limbs out through the anterolateral portal for tying. (B) The margin convergence sutures are tied with a Revo knot using an arthroscopic knot pusher.

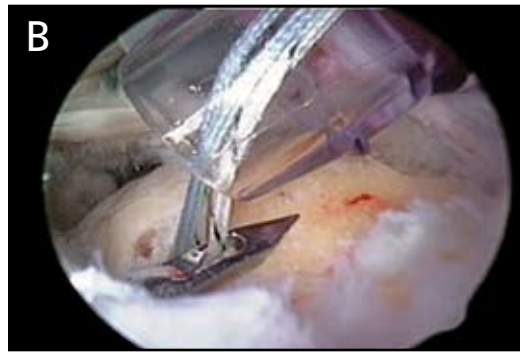
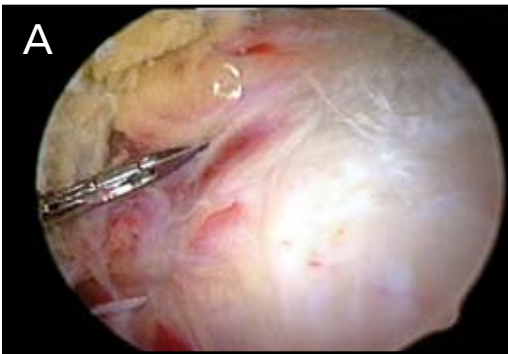
**Figure 8-11.** Completed margin convergence. Three sutures were utilized to reapproximate the longitudinal component of the tear.



- \* These steps are repeated with additional sutures placed at 10-mm intervals that progress from medial to lateral. As these margin convergence sutures are tied, the free end of the rotator cuff converges to the prepared bone bed (Figure 8-11).
- \* The tendon-bone component of the repair is subsequently undertaken. If tendon excursion allows, a transosseous equivalent repair technique is employed. We prefer double-loaded over single-loaded suture anchors due to increased points of fixation and the ability to



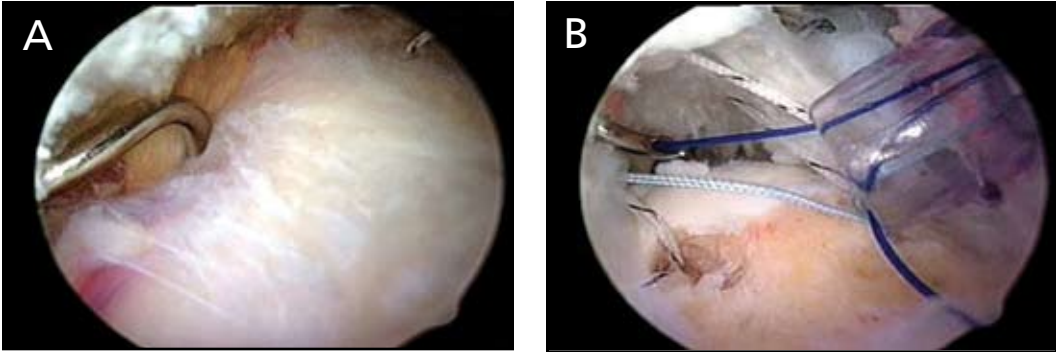
**Figure 8-12.** Medial anchor insertion. We prefer to use Arthrex 4.5-mm fully threaded Biocorkscrew anchors (Arthrex Inc, Naples, FL) double-loaded with #2 FiberWire.



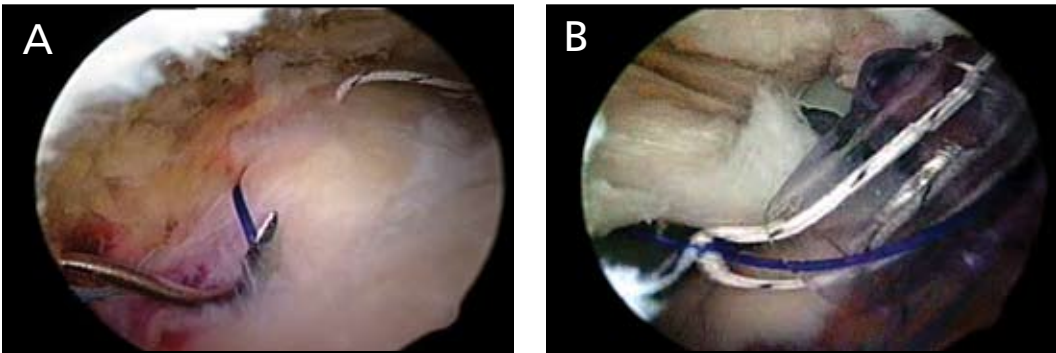
**Figure 8-13.** Posterior suture passing with Penetrator device. (A) The Penetrator device is positioned above the cuff for penetration at least 15 mm from the free edge and 5 mm from the repaired longitudinal split (B) The Penetrator retrieves one suture limb from the suture anchor.

perform a horizontal mattress suture configuration with the medial row of anchors. A first row of suture anchors are placed along the medial border of the rotator cuff footprint, approximately 4 mm from the articular margin. The most posterior anchor is placed first, utilizing the anterolateral cannula and entering the supraspinatus footprint at a 45-degree angle to the bone (Figure 8-12).

- \* For the posterior cuff, sutures are passed retrograde with a Penetrator. The Penetrator is brought in through the posterior portal and pierces the cuff at least 15 mm from the tear margin (Figure 8-13A). One limb is retrieved and the instrument withdrawn out the posterior portal thus passing the suture (Figure 8-13B).
- \* These steps are repeated with the other suture limbs to create two horizontal mattress configurations. Hemostats are placed on the 2 suture pairs as they exit the posterior portal to maintain their identity.
- \* A second anchor is then placed in the anteromedial region of the footprint and 3 suture limbs are pulled out through the anterior cannula, leaving one remaining suture in the anterolateral cannula. For suture passage through the anterior cuff, we prefer a hooked Spectrum suture relay device (Linvatec, Largo, FL). The tip has a 45-degree curve in the direction of the operative shoulder (ie, right-angled hook for a right shoulder). The Spectrum is brought into the subacromial space through the posterior portal and pierces the rotator cuff anterior to the previously placed sutures along the free anteromedial edge of the tendon (Figure 8-14A).



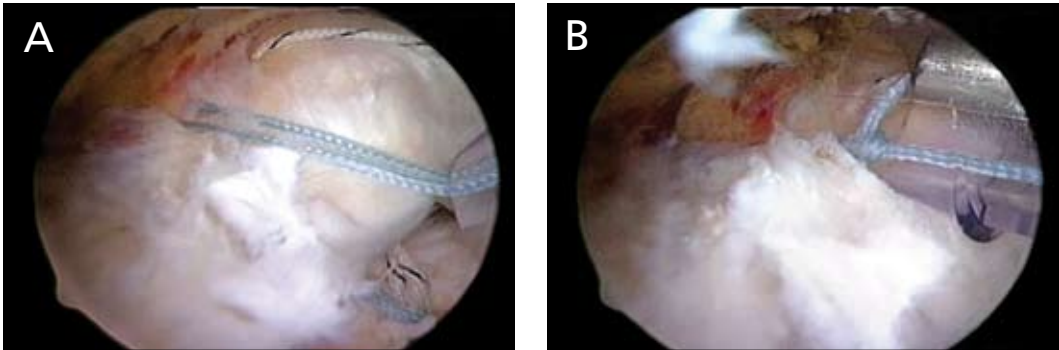
**Figure 8-14.** Anterior suture passing with the Spectrum device. (A) The curved device is passed through the superior aspect of the anterior leaf. (B) A polydioxanone suture is advanced through the device and retrieved through the anterolateral cannula.



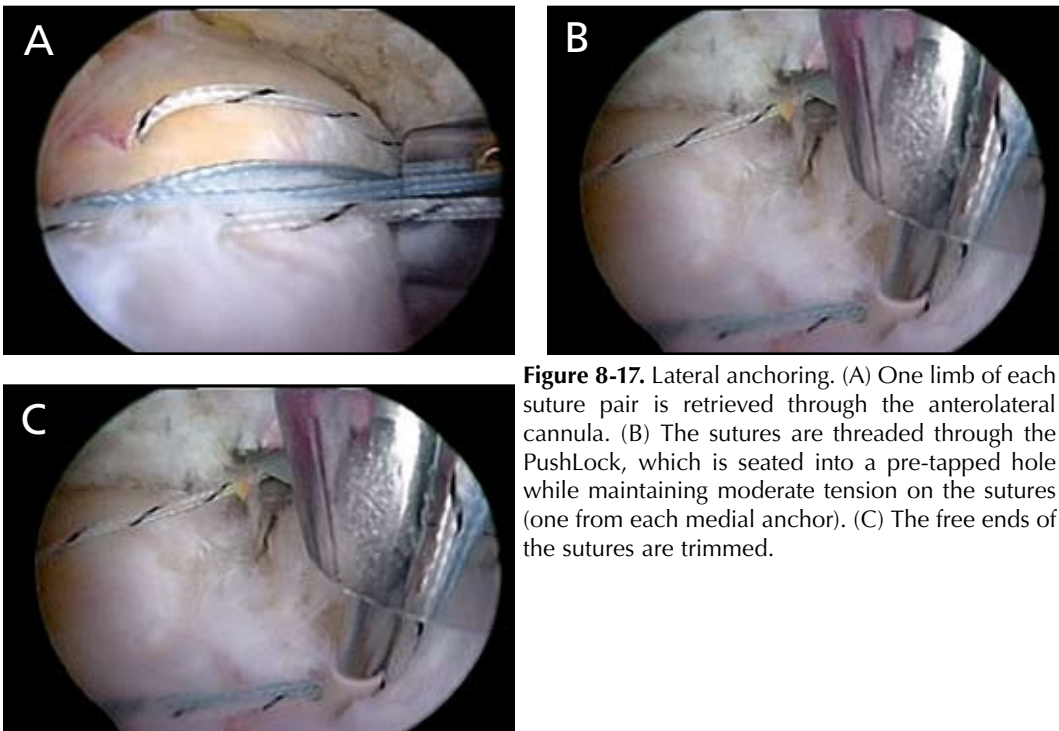
**Figure 8-15.** Completion of anterior suture passing. (A) The Spectrum device is rotated out of the anterior leaf. (B) The FiberWire suture is tied to the polydioxanone suture and shuttled through the anterior cuff and out the posterior portal.

- \* Once the tip of the device is visualized under the rotator cuff, a number 0 PDS suture (polydioxanone, Ethicon Inc, Piscataway, NJ) is advanced into view and pulled out through the anterolateral cannula by a grasper (Figure 8-14B). A half-hitch loop is created with the PDS suture and approximately 5 cm of the FiberWire suture exiting the cannula is placed into the loop and then tightened. The Spectrum is rotated out of the rotator cuff and removed from the shoulder (Figure 8-15A). The end of PDS suture exiting the posterior portal is pulled, thus shuttling the FiberWire suture from the anchor through the rotator cuff (Figure 8-15B).
- \* The corresponding same-color suture limb is retrieved from the anterior cannula and brought out the anterolateral cannula. The Spectrum passing sequence is repeated to produce a horizontal mattress configuration with the free ends exiting the posterior portal. The process is repeated with the other pair of sutures from the anterior anchor, producing 2 horizontal mattress configurations in the anterior leaf of the tear (Figure 8-16A).
- \* The mattress sutures are tied posterior to anterior while visualizing through the lateral portal. Each pair of sutures is shuttled to the anterolateral cannula where they are tied with a Revo knot (Figure 8-16B). The lens is rotated as needed to visualize the knot on top of the cuff as it is tied as well as the approximation of the rotator cuff to the footprint. After each knot is secured, the sutures are not cut but are brought out through the anterior cannula.





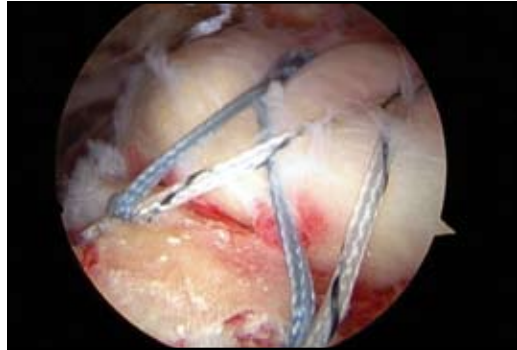**Figure 8-16.** Completion of the medial repair. (A) Four suture limbs of the anterior anchor have been passed through the anterior cuff. (B) Each pair is tied in a horizontal mattress configuration.



**Figure 8-17.** Lateral anchoring. (A) One limb of each suture pair is retrieved through the anterolateral cannula. (B) The sutures are threaded through the PushLock, which is seated into a pre-tapped hole while maintaining moderate tension on the sutures (one from each medial anchor). (C) The free ends of the sutures are trimmed.

- \* A radiofrequency device is used to clear an area lateral to the footprint in preparation for completion of the transosseous-equivalent repair. This is up to 1 cm lateral to the margin of the footprint and in line with the previously placed posterior, medial anchor.
- \* One suture limb from each of the previously-placed and tied mattress sutures is then brought out through the anterolateral cannula (Figure 8-17A). These suture limbs are threaded through a 4.5-mm Bio PushLock anchor (Arthrex Inc). At the previously prepared site, the pilot hole is tapped followed by insertion of the PushLock at a 45-degree angle to the proximal lateral humerus (Figure 8-17B).
- \* The sutures form a bridge over the completed cuff repair. The sutures are tied to increase security, then cut (Figure 8-17C). The process is repeated with the remaining sutures and a second PushLock is in line with the anterior, medial row anchor. After these sutures are cut, the arm is taken through gentle rotation, demonstrating the completed repair (Figure 8-18).

**Figure 8-18.** Completed repair. A completed transosseous equivalent repair with minimal tension and reapproximation of the footprint.



## TIPS AND PEARLS

- ✓ When using the beach chair position, ensure that the patient is far enough lateral to allow full access to the anterior and posterior shoulder.
- ✓ Efficient time management is crucial because swelling of the surrounding soft tissues can impair visualization. Auxiliary procedures—including subacromial decompression and acromioplasty—should be completed within 30 minutes to allow sufficient time for the rotator cuff repair.
- ✓ Complete visualization of the subacromial space through radiofrequency ablation of the bursa and adhesions is critical to correctly identify the tear pattern and perform the appropriate repair.
- ✓ Trim, but do not remove, the torn tendon edges.
- ✓ Superficial decortication of the greater tuberosity during footprint preparation is all that is required to avoid reduction in suture anchor fixation strength.
- ✓ Have an assistant hold the working cannula whenever you are passing and removing instruments to prevent inadvertent advancement or removal of the cannula. The scope is maintained in the lateral portal throughout the process of passing sutures.
- ✓ Stay organized with suture management. Alternating colors of the sutures helps with correct identification. When pulling sutures out of the shoulder, always visualize the anchor eyelet to prevent unthreading of the anchor.
- ✓ When passing sutures through the posterior cuff in a retrograde fashion with the Penetrator, “line up the putt” prior to piercing the cuff to ensure a direct line to the suture anchor.
- ✓ A grasper can be used to stabilize the cuff to enable the suture passing instrument to pass through with minimal additional trauma.
- ✓ An anterior and posterior cannula can be utilized to facilitate the passage of instruments and the shuttling of sutures; however, our preference is to work without a cannula in the posterior portal.
- ✓ The medial row sutures are typically tied with the arm in a position of slight forward elevation and external rotation with traction maintained by the commercial arm holder.

## PITFALLS

- ✘ Failure to preserve the deltoid fascia contributes to significant swelling of the surrounding soft tissues and limitation of the available work space.
- ✘ Failure to perform appropriate releases will lead to inadequate mobilization of the tendons and resultant excessive tension on the repair.

## REFERENCES

1. DeOrio JK, Cofield RH. The results of a second attempt at surgical repair of a failed initial rotator cuff repair. *J Bone Joint Surg Am.* 1984;66:563-567.
2. Gerber C, Fuchs B, Hodler J. The results of repair of massive tears of the rotator cuff. *J Bone Joint Surg Am.* 2000;82:505-515.
3. Bennett WF. Arthroscopic repair of massive rotator cuff tears: a prospective cohort with 2- to 4-year follow-up. *Arthroscopy.* 2003;19:380-390.
4. Galatz LM, Ball CM, Teefey SA, et al. The outcome and repair integrity of completely arthroscopically repaired large and massive rotator cuff tears. *J Bone Joint Surg Am.* 2004;86:219-224.
5. Jones CK, Savoie FH III. Arthroscopic repair of large and massive rotator cuff tears. *Arthroscopy.* 2003;19:564-571.
6. Lo IK, Burkhart SS. Arthroscopic repair of massive, contracted, immobile rotator cuff tears using single and double interval slides: technique and preliminary results. *Arthroscopy.* 2004;20:22-33.
7. Burkhart SS, Barth JRH, Richards DP, et al. Arthroscopic repair of massive rotator cuff tears with stage 3 and 4 fatty degeneration. *Arthroscopy.* 2007;23:347-354.
8. Burkhart SS, Lo IK. Arthroscopic rotator cuff repair. *J Am Acad Orthop Surg.* 2006;14:333-346.
9. Burkhart SS, Athanasiou KA, Wirth MA. Margin convergence: a method of reducing strain in massive rotator cuff tears. *Arthroscopy.* 1996;12:335-338.
10. Burkhart SS, Nottage WM, Ogilvie-Harris DJ, et al. Partial repair of irreparable rotator cuff tears. *Arthroscopy.* 1994;10:363-370.
11. Park MC, ElAttrache NS, Tibone JE, et al. Part I: footprint contact characteristics for a transosseous-equivalent rotator cuff repair technique compared with a double-row repair technique. *J Shoulder Elbow Surg.* 2007;16:461-468.
12. Park MC, Tibone JE, ElAttrache NS, et al. Part II: biomechanical assessment for a footprint-restoring transosseous-equivalent rotator cuff repair technique compared with a double-row repair technique. *J Shoulder Elbow Surg.* 2007;16:469-476.
13. Cole BJ, ElAttrache NS, Anbari A. Arthroscopic rotator cuff repairs: an anatomic and biomechanical rationale for different suture-anchor repair configurations. *Arthroscopy.* 2007;23:662-669.

