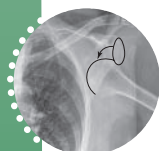


SECTION

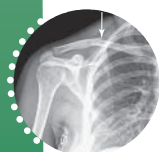
6

Shoulder



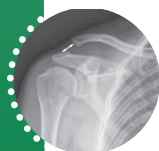Chapter 30 Shoulder Dislocations

*George M. Bridgeforth, Shane J. Nho,
Rachel M. Frank, and Brian J. Cole*



Chapter 31 Clavicle Fractures

*George M. Bridgeforth, Shane J. Nho,
Rachel M. Frank, and Brian J. Cole*



Chapter 32 Acromioclavicular Joint Injury

*George M. Bridgeforth, Shane J. Nho,
Rachel M. Frank, and Brian J. Cole*

Functional Anatomy

The shoulder has three major joints: the glenohumeral, acromioclavicular, and sternoclavicular. The glenohumeral joint is a ball-and-socket joint that is formed by the articulation between the head of the humerus and the lateral scapula. It is capable of flexion (anterior elevation of the arm), abduction (outward elevation of the arm), flexion (posterior elevation of the arm), internal rotation (rotating the fist toward the body with the elbow flexed at 90 degrees), external rotation (rotating the fist away from the body with the elbow flexed at 90 degrees), and circumduction (rotation of the arm in a clockwise or counterclockwise direction). In addition to the head, the (proximal)

humerus comprises the anatomical neck, surgical neck, and shaft (diaphysis). The head, a rounded structure, contains the greater and lesser tuberosities.

The greater tuberosity, which is more prominent and is lateral to the proximal tuberosity (and slightly higher), allows for the insertion of the tendons from three of the four rotator cuff muscles: the supraspinatus, infraspinatus, and teres minor. The supraspinatus muscle initiates shoulder abduction, and the infraspinatus and teres minor insert laterally (from the outside) to promote external rotation. The fourth rotator cuff muscle, the subscapularis, originates along the inside of the shoulder blade (in the subscapular fossa) and traverses medially in front of the head of the humerus to the lesser trochanter. It rotates the shoulder internally. During shoulder abduction, the infraspinatus and the teres minor externally rotate the greater tubercle and pull the head of the humerus inferiorly into the glenoid socket. The rotator cuff muscles counteract the upward and lateral pull of the deltoid to stabilize the humeral head during shoulder rotation. The greater and lesser trochanters are separated by the bicipital (intertubercular) groove, which anchors the tendon from the long head of the biceps (the short head inserts into the coracoid process of the shoulder). This (long head tendon) tendon inserts into the superior labrum. The biceps is the major flexor and supinator (palm facing upward) of the elbow and forearm.

The anatomical neck of the humerus, which connects the head and the shaft, has a medial (inward) angulation of 130 to 150 degrees. There is a slight angulation posteriorly (~30 degrees) as well in the sagittal (anterior-posterior) plane. This medial posterior angulation allows for better articulation of the humerus with the glenoid fossa. Just above the anatomical neck (but below the tuberosities) is the surgical neck, a more frequent site of fractures. The head of the humerus articulates with a shallow concave structure called the “glenoid fossa.” The glenoid labrum forms a wedge-shaped cartilaginous cushion around the rim of the articulating humerus. This cushion, which is several millimeters thick, deepens the concavity of the glenoid fossa and allows for better contact and joint stability.

The acromioclavicular joint connects the acromion, a bony process that represents the most superior extension from the scapula, with the distal clavicle. This diarthrodial joint contains a synovial lining and is encased by a joint capsule. The acromioclavicular ligament, which supports the acromioclavicular joint, helps prevent posterior dislocations of the clavicle. The sternoclavicular joint connects the medial end of the clavicle to the sternum.

The clavicle acts like a strut that prevents compression between the arm and the sternum. Moreover, it provides protection for the subclavian neurovascular bundles. The conical middle third is its weakest part and is the most common area of clavicle fractures. The costoclavicular ligament receives additional support from the medial first rib and the sternal capsule. This supporting ligament helps anchor the medial clavicle from dislocating not only during shoulder movements but also when the arms are carrying heavy loads.

Located medially and inferiorly to the acromion is the coracoid process of the scapula. This knob-shaped extension of the scapula lies beneath the clavicle. The coracoclavicular ligament attaches the coracoid process to the outer third of the overlying clavicle (Fig. 1). This ligament may be subdivided into the medial trapezoid and the conoid, its lateral counterpart (the ligaments are named for their shapes), which help prevent superior displacement of the clavicle. The acromioclavicular ligament connects the coracoid process to the acromion.

During shoulder abduction (outward movement of the arm in a superior direction), the scapula glides across the thoracic cavity in a 2 to 1 ratio. In other words, for every two degrees of abduction of the humerus at the

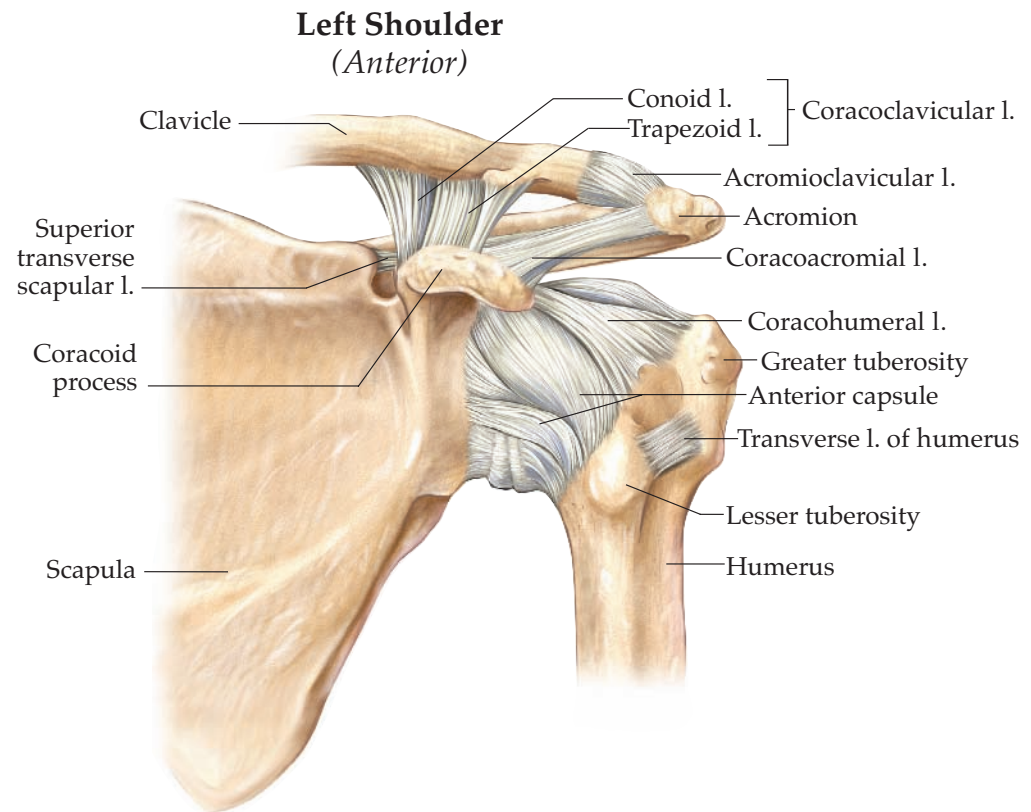
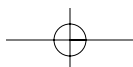
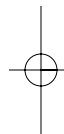
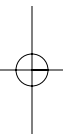
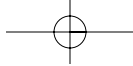


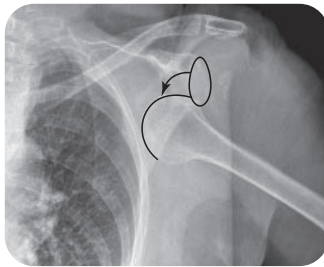
Figure 1 Left shoulder ligaments, anterior labeled. Asset provided by Anatomical Chart Co.

glenohumeral joint, there is a one-degree abduction of the tip of the scapula across the thorax. However, the scapular thoracic glide is not a true joint. Rather, winging of the scapula is prevented by its surrounding muscular attachments.

Regarding shoulder movement, it is important to note the complex relationship between the static stabilizers and the dynamic stabilizers. The static stabilizers hold the shoulder in place at rest. The major static stabilizers are the glenoid labrum, the ligaments (joining various shoulder structures), and the joint capsule. The dynamic stabilizers include the major surrounding muscle groups: the rotator cuff, deltoid, pectoralis muscles, rhomboids, and latissimus dorsi. These muscles work in concert with the static stabilizers to help maintain shoulder stability when the shoulder is in motion.



George M. Bridgeforth, Shane J. Nho, Rachel M. Frank, and Brian J. Cole



An 83-year-old woman who fell from a treadmill now complains of pain and soreness in both shoulders.

Clinical Presentation

A shoulder dislocation occurs at the glenohumeral joint when the humerus separates from the scapula (Fig. 30.1). The shoulder's great range of motion makes it especially susceptible to dislocation, and it is the most commonly dislocated joint. Shoulder dislocations have a bimodal incidence; they occur more frequently in younger men and older

women. The cause of most of these dislocations is generally a direct force applied to the arm; this force could result from a fall or a collision with another person or object.

Approximately 95% of all shoulder dislocations are anteroinferior. Posterior dislocations are uncommon, and pure inferior dislocations are rare. Most anteroinferior dislocations are characterized by displacement of the humeral head. Signs and symptoms include:

- Difficulty with arm movement together with impaired range of motion
- Marked pain
- Numbness of the arm
- Palpable gap in the subdeltoid region

Tears of the rotator cuff contribute to shoulder instability and may occur in shoulder dislocation. Patients with these tears, with or without an associated dislocation, have impaired range of motion with a positive drop arm test—an inability to sustain abduction (in which the arm is raised laterally) against resistance. The ability to abduct the arm to 90 to 120 degrees with limited resistance may indicate a partial tear or strain of a rotator cuff. The presence of limited extension (i.e., in which the arm is placed behind the shoulder) and weak external rotation (in which the forearm is rotated away from the body against resistance) commonly signifies complete tears of the rotator cuff. Supraspinatus tendinopathy also results unimpaired abduction and marked pain with resistance.

It is always important to rule out cervical disc disease, because a C5 radiculopathy can mimic or be associated with a shoulder injury. Patients with a C5 radiculopathy have a positive Spurling's test (cervical pain with axial compression), pain-limited cervical pain, and sensory loss along the lateral deltoid. In advanced cases, deltoid function may be pain limited and mimic a shoulder injury. Patients with C6 radiculopathies have numbness of the thumb

CLINICAL POINTS

- Most shoulder displacements occur in an anterior-inferior direction.
- Posterior dislocations are uncommon, and inferior dislocations (*luxatio erecta*) are rare.
- Gross dislocations may be associated with rotator cuff tears.

Dislocation of the Humerus

The shoulder joint is the most frequently dislocated joint in the body. It can become dislocated when a strong force pulls the shoulder outward (abduction) or when extreme rotation of the joint causes the head of the humerus to pop out of the shoulder socket.

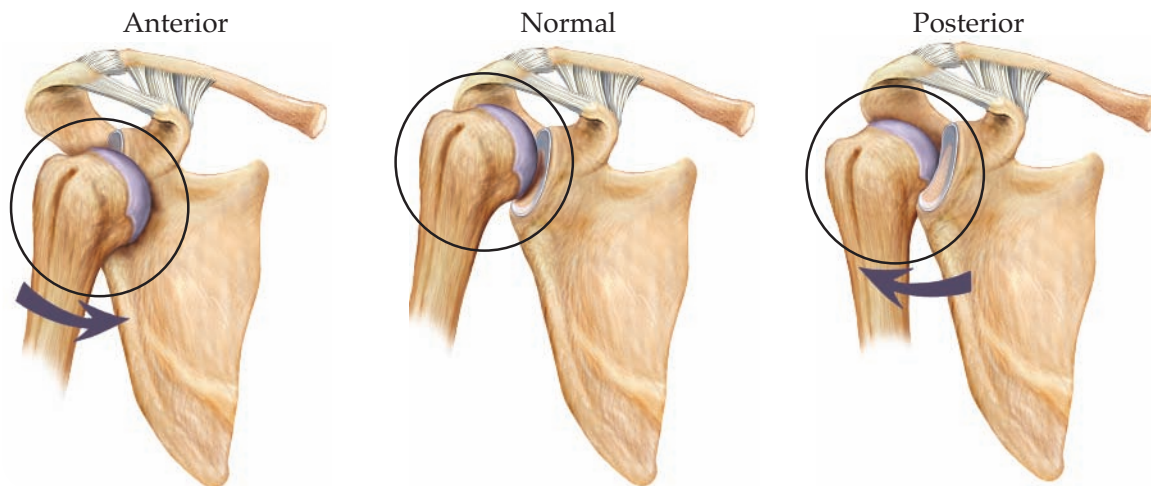


Figure 30.1 Anatomy and injuries of the shoulder. Instability. Dislocation of the humerus. Asset provided by Anatomical Chart Co.

and forefinger (Hoppenfeld's "six shooter"). C7 radiculopathies present with numbness to the middle finger, and C8 radiculopathies are characterized by cervical pain and numbness that radiates to the little finger. More advanced cases (C8 radiculopathy) demonstrate triceps weakness (elbow extension) with an impaired triceps reflex.

Posterior dislocations account for less than 5% of all shoulder dislocations. Unlike anterior-inferior dislocations, they can be missed on the clinical examination. It is strongly recommended that clinicians obtain a "Y" view (see section, "Radiographic Evaluation").

PATIENT ASSESSMENT

1. Marked pain and tenderness
2. Inability to abduct the affected arm (i.e., raise the arm away from the body)
3. Elbow flexion

Radiographic Evaluation

An anteroposterior (AP) view, AP view with internal rotation, and "Y" (transcapular) view (used in acute trauma to determine whether there is an anterior or posterior dislocation of the humerus; Fig. 30.2) should be ordered. An axillary view is optional (some physicians prefer an axillary view to a "Y" view to rule out a shoulder dislocation).

Normally, the humeral head fits into the glenoid fossa like a golf ball on a tee. The golf ball analogy is very important. In a normal radiograph, a plumb line (a downward vertical line dropped at a 90 degree angle from a point on a horizontal plane) that goes directly below the coracoid process should lie medial to the humeral head. The head of the displaced humerus lies directly inferior to the coracoid process as the dislocated humeral head crosses the scapula. Note the anterior and inferior displacement of the humeral head. It lies medial to the glenoid rim and below the glenoid fossa as well.

The overwhelming majority of anterior dislocations are identified on the standard AP and AP view with internal rotation. If the head of the humerus lies inside and inferior to the glenoid fossa, the examiner should immediately suspect a shoulder dislocation. However, some shoulder dislocations, especially

NOT TO BE MISSED

- Shoulder fractures
- Shoulder contusions
- Associated chronic shoulder instability
- Associated Bankart fractures, Hill-Sachs fractures, and superior labrum anterior posterior (SLAP) lesions
- Rotator cuff strains/tears
- C5 radiculopathy
- Subacromial bursitis
- Upper biceps tendonitis
- Acromioclavicular joint strains
- Clavicular fractures
- Pneumothoraces
- Upper lobe pneumonia
- Pancoast tumors

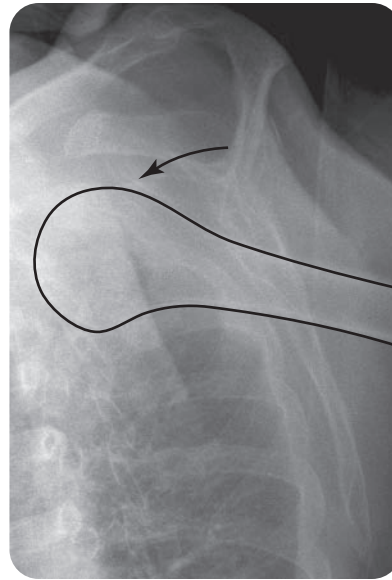


Figure 30.2 Scapular “Y” view of the left shoulder, demonstrating anterior shoulder dislocation from the patient in the introductory case. Note that on the anteroposterior view shown at the beginning of the chapter, the shoulder is inferiorly displaced and that the scapular “Y” view confirms and anterior dislocation.

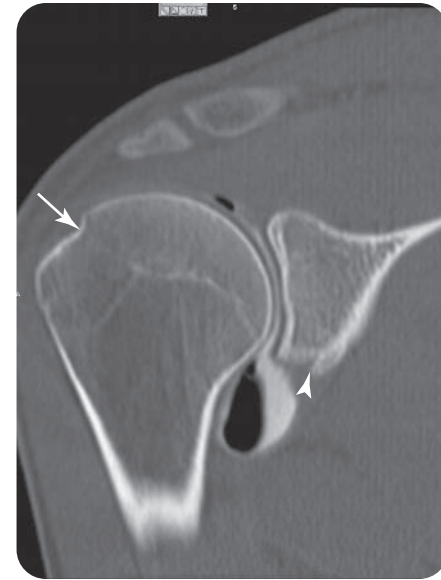

Figure 30.3 Selected coronal image from a right shoulder computed tomography arthrogram with iodinated contrast and air contrast demonstrating Hill-Sachs lesion (*arrow*) and Bankart fracture (*arrowhead*). This 23-year-old man dislocated his right shoulder 6 weeks earlier when he fell off the back of a moving truck.

posterior dislocations, are best identified on the “Y” view. In this projection, the anterior arm of the “Y” is formed by the coracoid process, and the posterior arm of the “Y” is formed by the acromion. Normally, the long axis of the humerus should bisect the “Y”. The long axis of the humerus clearly lies in front of the “Y”. Therefore, the “Y” view provides additional evidence of an anterior dislocation. On the other hand, with a posterior dislocation, the long axis of the humerus would lie behind the “Y”.

HILL-SACHS FRACTURES

Acute anterior dislocations may result in an impaction of the humerus head against the glenoid rim. The force of the impact may cause a fracture along the posterolateral head of the humerus. This type of injury is called a Hill-Sachs fracture (Fig. 30.3). Hill-Sachs deformities appear in 20% to 38% of anterior shoulder dislocations and are more common with chronic recurrent dislocations. A flattening along the posterior lateral segment of the humerus identifies an old Hill-Sachs fracture. Another sign of a Hill-Sachs fracture is a poorly defined sclerotic margin along the posterior lateral head (Harris).

Hill-Sachs fractures may have a variety of appearances, which vary from minimal cortical flattening to a notch (hatchet) defect of the humeral head. However, the classic hatchet deformity is uncommon and occurs in approximately 15% of cases. These defects of the humeral head may be associated with a sclerotic density along the posterior lateral humeral heads; these radiological findings are important clues to a prior Hill-Sachs fracture. In addition, the presence of an old Hill-Sachs fracture is important radiological evidence of chronic instability secondary to recurrent dislocations.

The AP view is best for appreciating Hill-Sachs fractures. An axillary view may reveal a hatchet-shaped deformity in the posterior lateral portion of the humeral head.

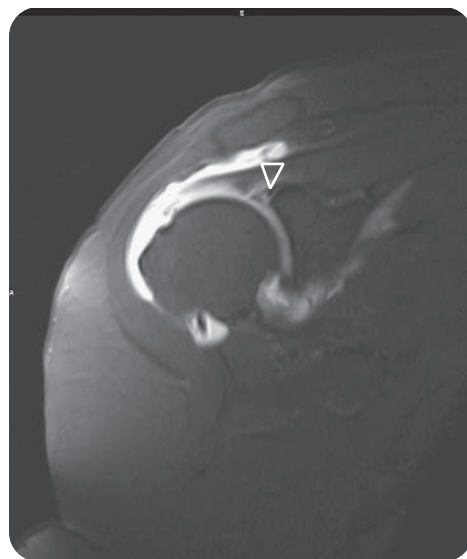


Figure 30.4 A selected coronal magnetic resonance imaging scan from a gadolinium-injected left shoulder arthrogram, demonstrating contrast extending between a torn superior labrum (*arrow*). Additionally, contrast is demonstrated in the sub-acromion space from a full thickness tear of the supraspinatus tendon.

BANKART FRACTURES

In addition, the impact of the humeral head may cause a fracture of the anterior-inferior glenoid rim. This type of fracture is called a Bankart fracture (see Fig. 30.3). From a clinical standpoint, Bankart fractures should be suspected in any patient with an anterior dislocation who has palpable pain and tenderness along the inferior glenoid labrum, which forms a fibrocartilaginous rim around the glenoid fossa. It is sometimes necessary to palpate the inferior rim of the glenoid fossa carefully for an associated Bankart fracture. However, it is important to note that if the impact is limited to the cartilaginous labrum, the injury to the inferior rim of the glenoid may not be identified on routine radiographs. Following a reduction, consideration should be given to obtaining a computed tomography scan to rule out an occult Bankart fracture. A magnetic resonance imaging (MRI) scan or an MRI arthrogram may be necessary (Fig. 30.4).

SLAP LESIONS

These injuries may occur in individuals who engage in overhead sports and work activities. The injury damages the superior glenoid labrum near the insertion of the long head of the biceps, which is an important stabilizer of the shoulder joint. Detachment of the long head of the biceps may result in superior instability of the shoulder. In addition, patients may complain of shoulder popping from the detached labral-biceps tendon complex. Moreover, the popping may be accentuated with overhead activities. Associated complaints may include shoulder pain with elevation and external rotation. If a SLAP lesion is suspected, an MRI arthrogram should be obtained.

Treatment

The treatment options for shoulder instability caused by shoulder dislocation have evolved over the years, and patients must be evaluated on a case-by-case basis. Treatment decisions are based on patient factors (sport-specific injury, timing of athlete's dislocation relative to the sport season, work-related injury, single traumatic dislocation versus a chronic, recurrent dislocation). In addition, some patients present without frank instability yet have pain due to excessive laxity that might be considered pathologic.

In general, treatment for shoulder dislocation can be divided into nonoperative and operative courses. The first step in the management of nearly any shoulder dislocation should be attempted closed reduction. This can be done at the site of injury, or preferably, in the emergency department. It is critical to obtain an axillary lateral view of the shoulder to confirm the direction of dislocation, as they can occur anterior, posterior, or inferior. A number of reduction maneuvers have been described; however, appropriate pain control and muscle relaxation is critical for a successful reduction. In many instances, a simple 10-mL injection of 1% lidocaine into the glenohumeral joint and placing the patient in the prone position with the affected arm hanging freely facilitate reduction and can avoid the need for a traumatic traction-induced reduction. Following reduction, nonoperative treatment involves immobilization of the glenohumeral joint with a sling as well as rehabilitation of the joint with an experienced physical therapist. Nonsteroidal anti-inflammatory drugs as well as ice therapy may also be used to relieve pain and reduce swelling. Early return to play for in-season athletes has been documented following this type of nonoperative treatment; however, it should be noted that athletes may need to undergo stabilization surgery if they continue to experience recurrent dislocations. See Figure 30.5 for postreduction radiographs.

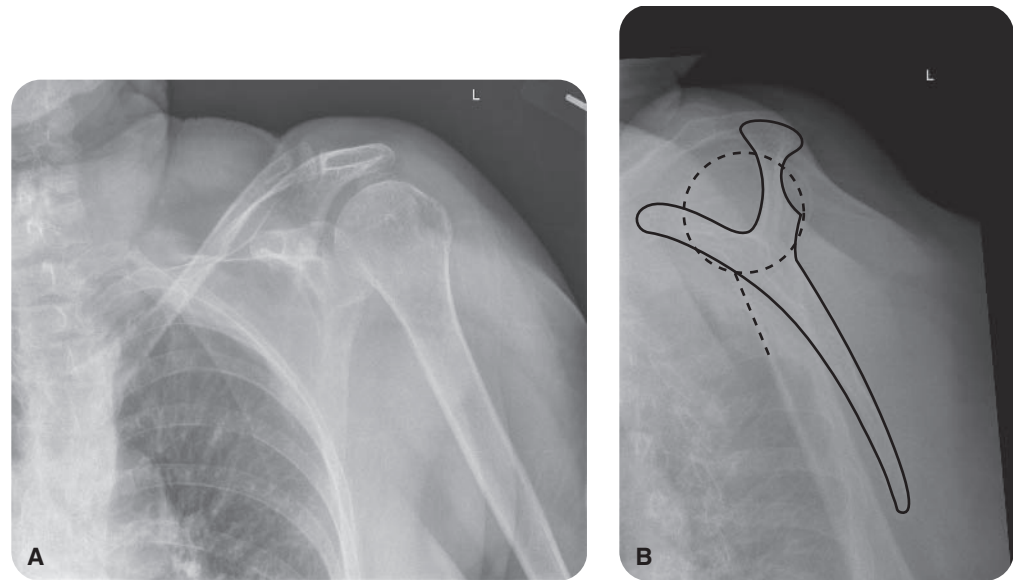


Figure 30.5 (A and B) Postreduction radiographs of the left shoulder in a more normal alignment.

Operative intervention is generally reserved for cases of recurrent dislocation, and factors such as age, type of sport or work, activity level, number of dislocations, and type of motions that cause instability may help guide the decision for operative intervention. Operative treatment for shoulder dislocation injuries usually involves minimally invasive arthroscopic surgery, during which the surgeon addresses any pathology associated with the glenohumeral joint. Specific attention is paid to the anteroinferior glenoid labrum and capsule (Bankart lesion), and repair of the Bankart lesion with or without capsular plication may be performed to reduce any capsular redundancy. The surgeon also examines the entire shoulder joint to assess for any concomitant pathology, including anteroinferior glenoid bone loss, Hill-Sachs lesions, additional labral tears, rotator cuff tears, or biceps pathology, and he or she makes treatment decisions depending on the operative findings. Return to sports generally occurs within 4 to 6 months, but this period can be somewhat longer when the dominant arm of a throwing athlete is involved.

WHEN TO REFER

- Immediate referral is necessary for patients with significant dislocations for reduction.
- Patients with chronic instability may be surgical candidates

Suggested Readings

- Burbank KM, Stevenson JH, Czarneck GR, Dorfman J. Chronic shoulder pain; Part I. evaluation and diagnosis. *Am Fam Physician*. 2008;77(4):453-460.
- Buss DD, Lynch GP, Meyer CP, Huber SM, Freehill MQ. Nonoperative management for in-season athletes with anterior shoulder instability. *Am J Sports Med*. 2004;32(6):1430-1433.
- Hendry GW. Necessity of radiographs in the emergency department management of shoulder dislocations. *Ann Emerg Med*. 2000;36:108-113.
- Hoppenfeld S. *Physical examination of the spine and extremities*. Norwalk, CT: Appleton-Century-Crofts; 1976:121.
- Hovelius L, Olofsson A, Sandstrom B, et al. Nonoperative treatment of primary anterior shoulder dislocation in patients forty years of age and younger. A prospective twenty-five-year follow-up. *J Bone Joint Surg Am*. 2008;90(5):945-952.
- Millett PJ, Clavert P, Warner JJ. Open operative treatment for anterior shoulder instability: when and why? *JBJS*. 2005;87:419-432.
- O'Connor DR, Schwarze D, Fragomen AT, Perdomo M. Painless reduction of acute anterior shoulder dislocation without anesthesia. *Orthopedics*. 2006;29(6):528-532.
- Perron AD, Ingerski MS, Brady WJ, Erling BF. Acute complications associated with shoulder dislocations at an academic emergency department. *J Emerg Med*. 2003;24(2):141-145.
- Quillen DM., Wuchner M, Hatch RL. Acute shoulder injuries. *Am Fam Physician*. 2004;70:1947-1954.
- Robinson CM, Adertinto J. *Posterior shoulder dislocations and fracture-dislocations*. *JBJS*. 2005;87:639-650.
- Woodward TW, Best TM. The painful shoulder: Part 1. Clinical evaluation. *Am Fam Physician*. 2000;61:3079-3088.
- Woodward TW, Best TM. The painful shoulder: Part II. Acute and chronic disorders. *Am Fam Physician*. 2000;61:3291-3300.