

5 points on



ARTHROSCOPIC DOUBLE-ROW AND “TRANSOSSEOUS-EQUIVALENT” ROTATOR CUFF REPAIR

Adam Yanke, MS, Matthew T. Provencher, MD, and Brian J. Cole, MD, MBA

The successful surgical treatment of rotator cuff tears remains challenging, because the high re-tear rate following rotator cuff repair is due to multiple factors. Aspects such as poor tendon biology, muscular fatty infiltration and retraction, and nonanatomical repairs ultimately lead to inferior repair biomechanics. Although many of these factors remain beyond the control of the surgeon, certain repair constructs have been shown to decrease suture interface stress and ultimate gap formation while increasing initial fixation strength. A repair that can recreate the tendon's natural footprint, while providing sufficient bony contact and repair construct stiffness during the healing process, optimizes the biomechanical aspects of rotator cuff repair.

For the purposes of this article, a double-row construct consists of 2 rows of suture anchors all placed within the supraspinatus footprint. The transosseous-equivalent repair is a variant of the double-row repair and consists of a medial row of suture anchors; however, the lateral row of fixation is accomplished through more laterally based sutures and anchors to compress the rotator cuff footprint.

The use of either the double-row or, more recently, the “transosseous-equivalent” repair construct has been advocated, as both have demonstrated superior biomechanical properties and footprint restoration. These repairs allow for an even distribution of load and increased tendon-bone contact in the area of the tendon's natural insertion.¹⁻³ In addition, when assessed at time zero, double-row and transosseous-equivalent repairs have demonstrated less gap formation, less bone-tendon interface motion, and superior overall biomechanical tendon fixation properties compared with single-row techniques.⁴⁻⁷

Although the biomechanical advantages of these procedures are attractive, the double-row and transosseous-equivalent repair types require additional surgical expertise. It should be noted that superior long-term clinical results for these techniques remain to be seen.

The following outlines 5 points on the surgical and technical aspects of performing an arthroscopic double-row or transosseous-equivalent rotator cuff repair.

1 Identify candidates on the basis of tear size and pattern.

Once the subacromial space is adequately prepared, the rotator cuff tear is visualized and assessed from the lateral portal. The rotator cuff edges are débrided and the overall medial-to-lateral and anterior-to-posterior mobility of the tear is assessed. The tear pattern is then classified, and it is determined whether the tear is amenable to double-row or transosseous-equivalent repair techniques. Most U-shaped, L-shaped, and crescent tears (following side-to-side repair when necessary) whose lateral edge is reducible to the lateral edge of the tuberosity are amenable to double-row repair constructs.⁸ Various techniques may be utilized to completely liberate the borders of the tear, allowing for optimal tendon mobilization and reduction.

Smaller tears may not require a double-row repair configuration simply because the strength of the single-row repair is more than adequate to resist in-vivo forces and cyclic load during the initial postoperative protection phase. Larger



Mr. Yanke is Research Fellow, Department of Orthopaedic Surgery, Dr. Provencher is Orthopaedic Sports Fellow, Department of Orthopaedic Surgery, and Dr. Cole is Professor, Departments of Orthopaedic Surgery and Anatomy and Cell Biology, and Director, Cartilage Restoration Center at Rush, Rush University, Chicago, Illinois.



For reprints, contact Brian J. Cole, MD, MBA, Rush University, Department of Orthopaedic Surgery, 1725 W. Harrison, Suite 1063, Chicago, IL 60612 (email, bcole@rushortho.com).



Am J Orthop. 2007;36(6):294-297. Copyright Quadrant HealthCom Inc 2007.

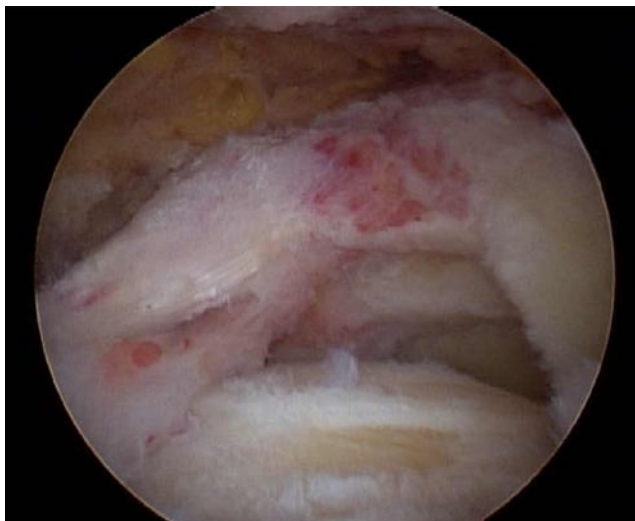


Figure 1. Rotator cuff tear in a left shoulder viewed from lateral portal demonstrates large tear approximately 4 cm from anterior to posterior.

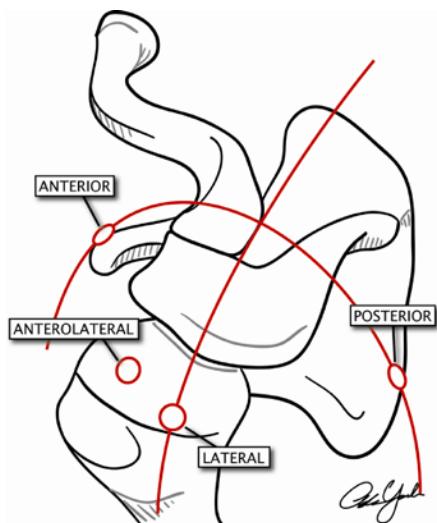


Figure 2. Schematic of portal placement in a left shoulder for arthroscopic rotator cuff repair devices, directly in-line with the trajectory of the cuff tendons. Note the anterolateral portal location in line with the anterior edge of the supraspinatus tendon, making it ideal for placing sutures anteriorly. Alternatively, retrograde suture passers can be utilized from the anterior or posterior portals. Illustration by Adam Yanke, MS.

tears (up to 5 cm) that involve either the entire supraspinatus (SS) and/or infraspinatus (IS) are also candidates for double-row techniques. It is important to remember that the anatomic footprint of the supraspinatus tendon is in the shape of a rectangle, approximately 25 mm from anterior to posterior and 12 mm in a medial-to-lateral direction.⁹ The supraspinatus inserts approximately 1.5 to 2 mm lateral to the articular margin of the humeral head. Knowing the size of the anatomic footprint assists with proper tear reduction, double-row anchor placement, and suture placement for medial-row repair.

2 Use optimal portal positioning to improve preparation and visualization.

Portal positioning is critical to the success of a double-row repair. With the arthroscope in the posterior portal, a lateral portal is made at the midpoint (anterior-posterior) of the rotator cuff tear, approximately 2 to 3 cm inferior to the inferior edge of the acromion and generally in line with the posterior border of the clavicle. This allows for in-line visualization of the rotator cuff tear and leaves room for an anterolateral accessory instrumentation portal. To prevent fluid extravasation, a 5-mm cannula should be inserted through a sufficiently small incision in the lateral portal, ensuring a solid seal of the cannula against the skin and deltoid fascia. From the lateral portal, a shaver and/or radiofrequency (RF) device is utilized to complete the subacromial space débridement and cuff tear preparation.

The lateral gutter needs to be cleaned of adhesions and bursal tissue to ensure that the tuberosity can be fully visualized to perform the transosseous-equivalent technique. Care should be taken to avoid penetration of the deltoid fascia, which can cause excessive bleeding, fluid extravasation, and deltoid compromise. At this point, the arthroscope is placed in the lateral portal, and the preparation of the lateral gutter is completed with a shaver or RF wand from the posterior portal. The arthroscope will then remain in the lateral portal for the remainder of the case.

Through the lateral portal, the tear configuration and mobility can be reassessed (Figure 1). Additional releases and tissue preparation should be performed at this point. A temporary cuff tear reduction stitch may be utilized to help orient the tear, prevent tissue over-distraction (with potential loss of motion), and serve as a visual guide to facilitate anatomical repair. We find that the reduction stitch should be placed in the most anterior aspect of the tear, near the anterior edge of the SS tendon, and tied loosely with a #2 braided suture after placement with a penetrator device. This still allows for placing instrumentation through the cuff to accomplish the repair while avoiding excessive tendon constraint. An arthroscopic grasper placed on the edge of the tendon during the reduction and stitch repair process facilitates suture passage and management.

3 Know your rotator cuff repair devices. They will help dictate the location of your accessory repair portals.

Before creating any additional portals to accomplish the repair, choose accessory portals according to which devices you utilize for rotator cuff repair. Antegrade devices, retrograde devices, and a variety of others are currently available to place sutures through specific sites in the rotator cuff. Antegrade devices are utilized from a direct lateral portal and plicate tissue with an enclosed needle-tip that advances the suture at the desired depth. Examples are the ExpresSew Flexible Suture Passer (Mitek, Raynham, MA) with a 4.5-mm tip and 18-mm jaw length and the Scorpion Suture

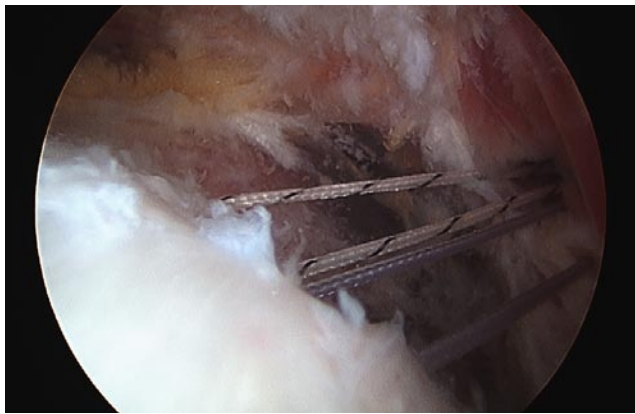


Figure 3. Arthroscopic view of sutures placed in the rotator cuff in a left shoulder for a posteromedial repair. This was achieved with a retrograde suture hook (to the left) through the accessory posteromedial portal.

Passer (Arthrex, Naples, FL), which is available with a 16-mm or an extended 20-mm jaw length. If you plan to use an antegrade passer, the arthroscope is maintained in the lateral portal, an accessory anterolateral portal is made directly in line with the edge of the rotator cuff, and a cannula of appropriate diameter is placed to accommodate the instrumentation (Figure 2). In this manner, the antegrade passers enter the shoulder at a trajectory that facilitates the excursion of the rotator cuff tissue into the jaws of the device. We find that these are frequently useful in the anterior portion of the cuff repair.

There are numerous retrograde passers, including hand-held sharp tissue-penetration instruments and instruments with a straight or curved arthroscopic needle. We perform the majority of the posteromedial cuff repairs using a retrograde device introduced from either the existing posterior portal or an accessory posterolateral or posteromedial portal. The posteromedial portal¹⁰ is also effective for repairing most posterior cuff tears (Figure 3). With the arthroscope in the lateral portal, sutures are retrieved from the anterolateral portal placed

directly off the anterolateral aspect of the acromion and tied. As the anteromedial repair can be more challenging, it can be accomplished from an accessory anterior portal with either antegrade or retrograde passers or through the posterior portal using a shuttle-type device curved 45° in the direction of the shoulder. Any of the retrograde devices may also be used in the modified Neviaser portal, which is useful to place sutures in the central and medial portion of the cuff. Regardless of which repair device is utilized, one should keep in mind the anatomy of the rotator cuff insertion footprint and ensure that a minimum of 10 to 12 mm of tissue is grasped medially by the suturing device. If double-loaded anchors are used, both limbs of suture should be tied (in any of a variety of horizontal techniques); however, the suture limbs should be preserved to perform the lateral-row repair.

4 Choose the proper amount of cuff tissue plication to establish correct tension and complete lateral row fixation.

To prevent violation of the articular margin, the medial row of anchors is placed approximately 10 mm medial to the lateral reduced edge of the rotator cuff tendons (or 2 mm from the articular margin)—1 anterior and 1 posterior (Figure 4). An 18-gauge spinal needle is utilized to obtain the correct trajectory for subsequent percutaneous anchor placement just off the anterolateral edge of the acromion. The humerus should be abducted approximately 20° to 30° to ensure that the anchors do not violate the articular surface. The anchors are inserted at a 45° angle to the surface,¹¹ with caution taken to ensure that the trajectory does not violate the tunnel of the previous anchor. Depending on tear size (up to 12 mm anterior-to-posterior), only 1 medial anchor may be necessary, especially if it is double-loaded. Even with 1 medial anchor, 2 lateral anchors may be used to increase the surface area of compression. Once the medial row of anchors is in place, sutures are passed through the corresponding cuff tissue. In other words, suture

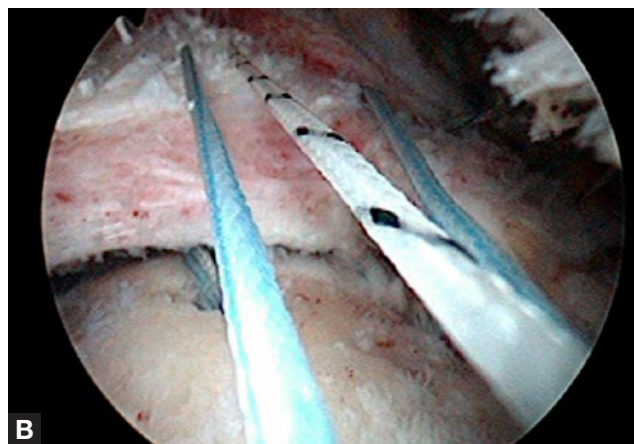
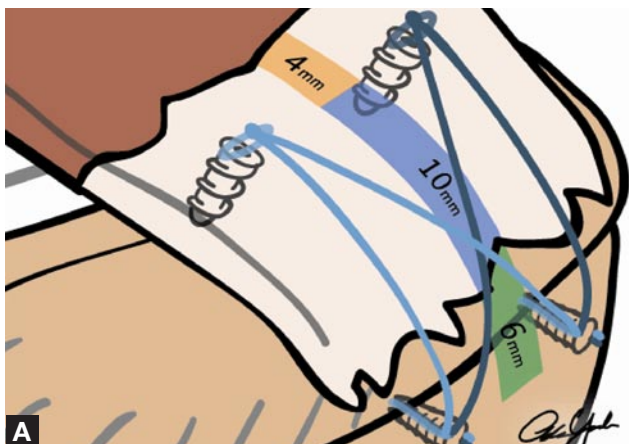


Figure 4. (A) Schematic of a double-row “transosseous-equivalent” repair displaying the mean distances for anchor placement that optimizes footprint restoration. The medial row of anchors has been placed (B) just prior to tying. Illustration by Adam Yanke, MS.

placement into the tendon should be about 10 to 15 mm medial and also oriented in the correct anterior-to-posterior configuration, since the medial row dictates the cuff tear reduction. The medial sutures are tied, and the anterior and posterior anchor sutures are shuttled anteriorly and posteriorly, respectively.

5

Plan your suture configurations for suture compression or suture bridge transosseous-equivalent techniques.

At this point, the medial tension has been established, the cuff tear reduced into place, and the medial sutures are parked outside the shoulder. The limbs are preserved and the transosseous-equivalent lateral repair is performed. With the arthroscope in the lateral portal, 1 limb of suture from each anchor (anterior and posterior anchors) is retrieved through the accessory anterolateral cannula and threaded through the eyelet of a lateral anchor device such as the Bio-PushLock (Arthrex, Naples, FL) or the Versalok (Mitek, Raynham, MA). Once both suture limbs are evenly tensioned, the suture is secured into place with a hemostat. The lateral anchor device is introduced into the shoulder before one taps the hole to assess tear reduction and implant placement. We generally start posteriorly, with the arm internally rotated. A radiofrequency wand or shaver may be used to mark the location of the lateral anchor device, so that the hole may be easily visualized after tapping. Since the lateral anchor device has already been preloaded, the time required to thread the device and the chances of losing the location of the hole are diminished. Once the hole is tapped, the anchor is introduced and secured into place while tension is maintained on each suture limb. After the device has been placed, the 2 limbs of the suture may be tied together to improve biomechanical stability of the construct. The process is repeated for the anterior implant and the final repair is evaluated (Figure 5). The lateral anchor devices will accommodate several limbs of suture; thus, a variety of configurations are made possible by varying the number of medial and lateral anchors and suture limb management.

CONCLUSIONS

Double-row fixation of rotator cuff tears continues to evolve. The first-generation double-row rotator cuff repair techniques

have demonstrated improved biomechanical properties, including higher load to failure, less gap formation, and less cyclic displacement. Newer transosseous-equivalent techniques have the potential added benefit of increased structural integrity and higher mean contact area of the tendon-to-bone interface.² Although we currently await longer-term data from clinical trials of double-row and transosseous-equivalent repairs, the biomechanical evidence in support of utilizing a double-row construct is compelling.

AUTHORS' DISCLOSURE STATEMENT AND ACKNOWLEDGEMENTS

Mr. Yanke and Dr. Provencher report no actual or potential conflicts of interest in relation to this article. Dr. Cole wishes to note that he receives funding, consultant fees, and royalties from Arthrex.

REFERENCES

- Mazzocca AD, Millett PJ, Guanche CA, Santangelo SA, Arciero RA. Arthroscopic single-row versus double-row suture anchor rotator cuff repair. *Am J Sports Med.* 2005;33(12):1861-1868.
- Park MC, Cadet ER, Levine WN, Bigliani LU, Ahmad CS. Tendon-to-bone pressure distributions at a repaired rotator cuff footprint using transosseous suture and suture anchor fixation techniques. *Am J Sports Med.* 2005;33(8):1154-1159.
- Tuoheti Y, Itoi E, Yamamoto N, Seki N, Abe H, Minagawa H, Okada K, Shimada Y. Contact area, contact pressure, and pressure patterns of the tendon-bone interface after rotator cuff repair. *Am J Sports Med.* 2005;33(12):1869-1874.
- Ahmad CS, Stewart AM, Izquierdo R, Bigliani LU. Tendon-bone interface motion in transosseous suture and suture anchor rotator cuff repair techniques. *Am J Sports Med.* 2005;33(11):1667-1671.
- Kim DH, Elatrache NS, Tibone JE, Jun BJ, DeLaMora SN, Kvitne RS, Lee TQ. Biomechanical comparison of a single-row versus double-row suture anchor technique for rotator cuff repair. *Am J Sports Med.* 2006;34(3):407-414.
- Ma CB, Comerford L, Wilson J, Puttitz CM. Biomechanical evaluation of arthroscopic rotator cuff repairs: double-row compared with single-row fixation. *J Bone Joint Surg Am.* 2006;88(2):403-410.
- Smith CD, Alexander S, Hill AM, Huijsmans PE, Bull AM, Amis AA, De Beer JF, Wallace AL. A biomechanical comparison of single and double-row fixation in arthroscopic rotator cuff repair. *J Bone Joint Surg Am.* 2006;88(11):2425-2431.
- Severud EL, Ruotolo C, Abbott DD, Nottage WM. All-arthroscopic versus mini-open rotator cuff repair: A long-term retrospective outcome comparison. *Arthroscopy.* 2003;19(3):234-238.
- Ruotolo C, Fow JE, Nottage WM. The supraspinatus footprint: an anatomic study of the supraspinatus insertion. *Arthroscopy.* 2004;20(3):246-249.
- Glenn RE, Jr, McCarty LP, Cole BJ. The accessory posteromedial portal revisited: utility for arthroscopic rotator cuff repair. *Arthroscopy.* 2006;22(10):1133.e1131-1135.
- Burkhart SS. The deadman theory of suture anchors: observations along a south Texas fence line. *Arthroscopy.* 1995;11(1):119-123.

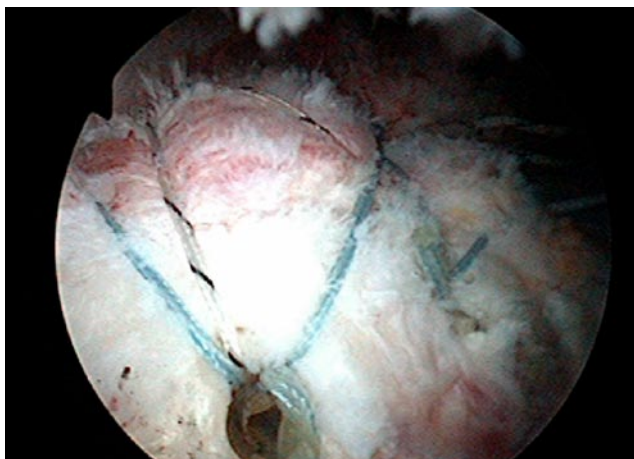
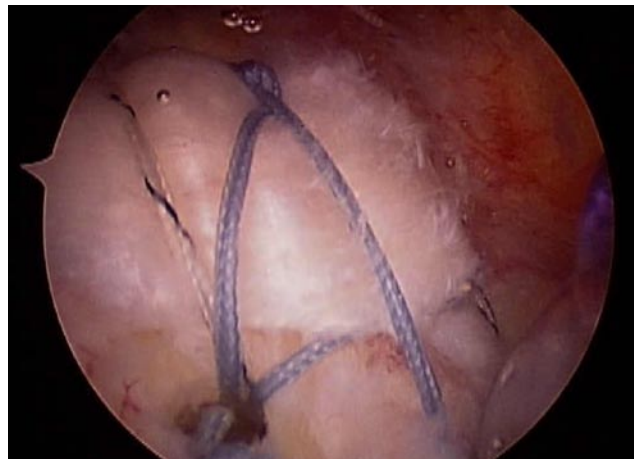


Figure 5. Final repair construct in a left shoulder with 2 lateral PushLock (Arthrex, Naples, FL) anchors placed approximately 6 mm lateral to the most lateral edge of the reduced tendon.



This paper will be judged for the Resident Writer’s Award.
