

Chapter 46

Pectoralis Major Transfer for Scapular Winging

Andreas H. Gomoll, MD

Brian J. Cole, MD, MBA

Indications

Scapular dysfunction is a relatively common orthopaedic problem, resulting from a variety of conditions that includes deconditioning and primary shoulder pathology. In most patients, rehabilitation leads to a resolution of symptoms. Occasionally, scapular winging (**Figure 1**) is refractory to nonsurgical treatment. In most of these patients, scapular winging results from serratus anterior dysfunction and may be a source of considerable functional limitations and pain, especially with overhead activities or when the arm is positioned away from the body. The serratus anterior stabilizes the scapula to the chest wall during elevation and is the most powerful protractor of the upper limb. The most frequently reported complaints are weakness of elevation, fatigue with overhead activities, and posterior periscapular pain. Because these symptoms are frequently vague and nonspecific, delayed or incorrect diagnoses such as glenohumeral instability or subacromial impingement are common.

The long thoracic nerve supplies the serratus anterior muscle and is formed from the anterior rami of C5 to C7; its injury causes weakness or complete paralysis. The roots of C5 and C6 run through the middle scalene muscle, then merge with fibers from C7,

before traveling along the lateral aspect of the thorax. The superficial location makes it susceptible to blunt trauma, but other etiologies exist such as traction injuries, brachial plexus neuritis (Parsonage-Turner syndrome), and iatrogenic injuries. Most traumatic insults to the long thoracic nerve are blunt injuries from sports participation or accidents that result in a neurapraxia, but repetitive strenuous activities also have been implicated.

Long thoracic nerve palsy usually resolves within 8 to 12 months but can last up to 2 years in infectious etiologies. However, up to 25% of patients experience persistent scapular winging and fatigue. Initial treatment should consist of gentle range-of-motion exercises to avoid shoulder stiffness. Electrodiagnostic studies can be obtained at 3-month intervals to evaluate recovery of the nerve. If physical examination or electrodiagnostic studies do not demonstrate signs of recovery after a year, surgical treatment may be indicated. The procedure of choice for persistent scapular injury secondary to long thoracic nerve palsy/serratus anterior weakness is transfer of the pectoralis major tendon to the scapula.

Contraindications

Associated paralysis of the trapezius muscle is a relative contraindication because it compromises the results of pectoralis major transfer. If present, trapezius palsy should be addressed by a levator scapula and rhomboid transfer, preferably in a staged procedure. Previous injury or compromise of the pectoralis major musculotendinous unit also is a contraindication to this procedure as it interferes with the ability to transfer the tendon appropriately.

Alternative Treatments

Continued physical therapy, the use of a brace to stabilize the scapula against the chest wall, and avoiding overhead activities are valid nonsurgical treatment modalities. Many patients, however, are unable to tolerate indefinite brace use and functional limitations, and they choose surgical treatment. Many techniques have been described to address scapular winging, and all aim to statically or functionally stabilize the scapula. Scapulothoracic fusion achieves static stabilization through fixation of the scapula to the chest wall. Fusion is successful in ad-

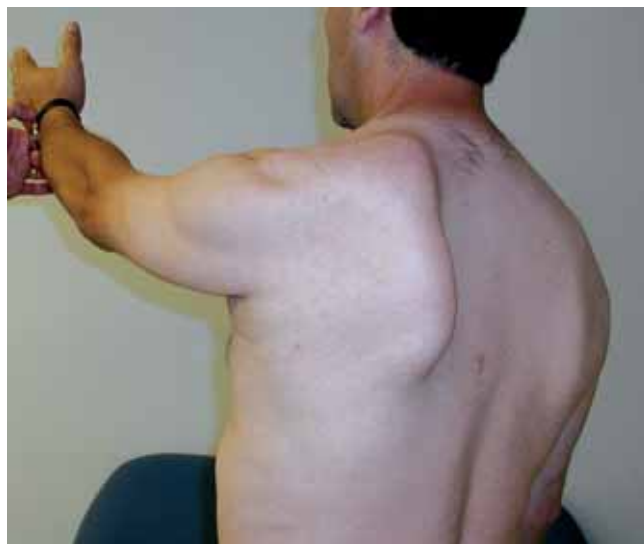

Figure 1 Scapular winging as evident with attempted elevation of the upper extremity.

dressing scapular winging, but it eliminates scapulothoracic motion. On average, one third of total elevation is lost after arthrodesis, as is a significant amount of extension and external rotation. Nonunion rates of up to 50% also have been described. Thus, scapulothoracic fusion should be reserved for cases of systemic muscular weakness, such as muscular dystrophies, or as a salvage procedure in patients with intractable pain and dysfunction after muscle transfer.

Results

Traditionally, failure rates for pectoralis major transfer have ranged between 0% and 26%. Early techniques were associated with significant donor site morbidity from the fascia lata graft harvest, but this problem has been successfully addressed by the use of autograft or allograft hamstring tendon. Earlier studies also described failures resulting from stretching of the avascular fascia lata graft when used to extend the length of the pectoralis major tendon. This issue also has been resolved as contemporary techniques attempt to approximate the pectoralis tendon into direct con-

tact with the scapula and use the graft only to reinforce the repair. Overall, transfer of the sternal head of the pectoralis major tendon is a successful procedure to address painful scapular winging refractory to nonsurgical management, providing consistent functional improvement and pain relief through dynamic stabilization (**Table 1**).

Techniques

Setup/Exposure

A combination of regional interscalene block with general anesthesia reduces postoperative pain and decreases narcotic requirements in the early postoperative period. The patient is positioned on a standard operating table with the help of a pneumatic (bean) bag in the lateral decubitus position with the torso tilted 30° posteriorly. This position allows the surgeon to simultaneously access the sternal head of the pectoralis major tendon and the inferior pole of the scapula. The shoulder is draped free to the midline both anteriorly and posteriorly. It is critical that the medial border of the scapula is easily palpable to allow intraoperative manipulation.

Traditional techniques have used a long anterior incision in the deltopectoral interval, but many surgeons, ourselves including, prefer two smaller incisions to provide improved cosmesis. The anterior incision measures approximately 3 to 4 cm, and is centered in the inferior half of the axillary crease (**Figure 2, A**). It begins at the inferior margin of the pectoralis major tendon and extends proximally, ending just lateral to the coracoid. A posterior incision of similar length is located over the inferior and lateral border of the scapula (**Figure 2, B**).

Instruments/Equipment/Implants Required

Allograft tendon, if preferred over autogenous hamstring graft, should be ordered in advance. A long hemostat or Kelly clamp facilitates passage of the traction sutures. A 7-mm drill or reamer is used to create the scapular drill hole for graft fixation.

Procedure

PECTORALIS TENDON HARVEST

Following the skin incision, an electrocautery device is used for dissection through the subcutaneous fat to the fascia overlying the pectoralis tendon. The creation of subcutaneous flaps should be avoided to prevent postoperative hematoma formation. The pectoralis major tendon inserts on the humerus just lateral to the long head of the biceps tendon and consists of the deeper sternal head that inserts on the lateral lip of the bicipital groove, and the superficial clavicular head that inserts more laterally. The raphe between the clavicular and sternal head is identified most easily approximately 7 to 9 cm medial to its insertion (**Figure 3**). The overlying fascia is incised and bluntly dissected to develop the interval between the sternal and clavicular heads. Abduction and external rotation of the arm are helpful to define the interval and to improve exposure. The deeper ster-

Table 1 Results of Pectoralis Major Transfer for Scapular Winging

Author(s) (Year)	Number of Patients	Mean Patient Age	Mean Follow-Up	Results
Steinmann, et al (2003)	9	34 years (21-47)	70 months (12-168)	4 excellent, 2 good, and 4 poor results. 7 patients returned to work. Two cases complicated by postoperative stiffness.
Noerdlinger, et al (2002)	15	33 years (17-44)	64 months (33-118)	2 excellent, 5 good, 4 fair, and 4 poor results by the Rowe criteria. Pain decreased in 11 patients, function improved in 10. 12 patients would undergo the procedure again. 13 patients returned to work. Two cases of postoperative stiffness, and 1 case of muscle hernia after fascia lata harvest.
Perlmutter, et al (1999)	16	33 years (20-55)	51 months (25-108)	8 excellent, 5 good, and 1 fair result. 14 patients returned to their previous employment, 9 patients returned to full recreational activities. Two graft failures associated with the use of fascia lata strip grafts early in the series.
Warner, et al (1998)	8	33 years (24-43)	32 months (24-40)	7 patients reported complete resolution of pain. Forward flexion improved from an average of 97° preoperatively to 150° postoperatively. One postoperative infection required graft removal.
Connor, et al (1997)	11	34 years (20-52)	41 months (12-84)	7 excellent, 3 satisfactory, and 1 unsatisfactory result by the Neer criteria, 2 of 4 heavy laborers returned to full duty, the other two returned to work with modifications. One graft failure 2 months postoperatively due to aggressive unsupervised physical therapy.
Post (1995)	8	NA	27 months (12-57)	All excellent results, all returned to work, 5 of 8 with modifications.

NA = not available

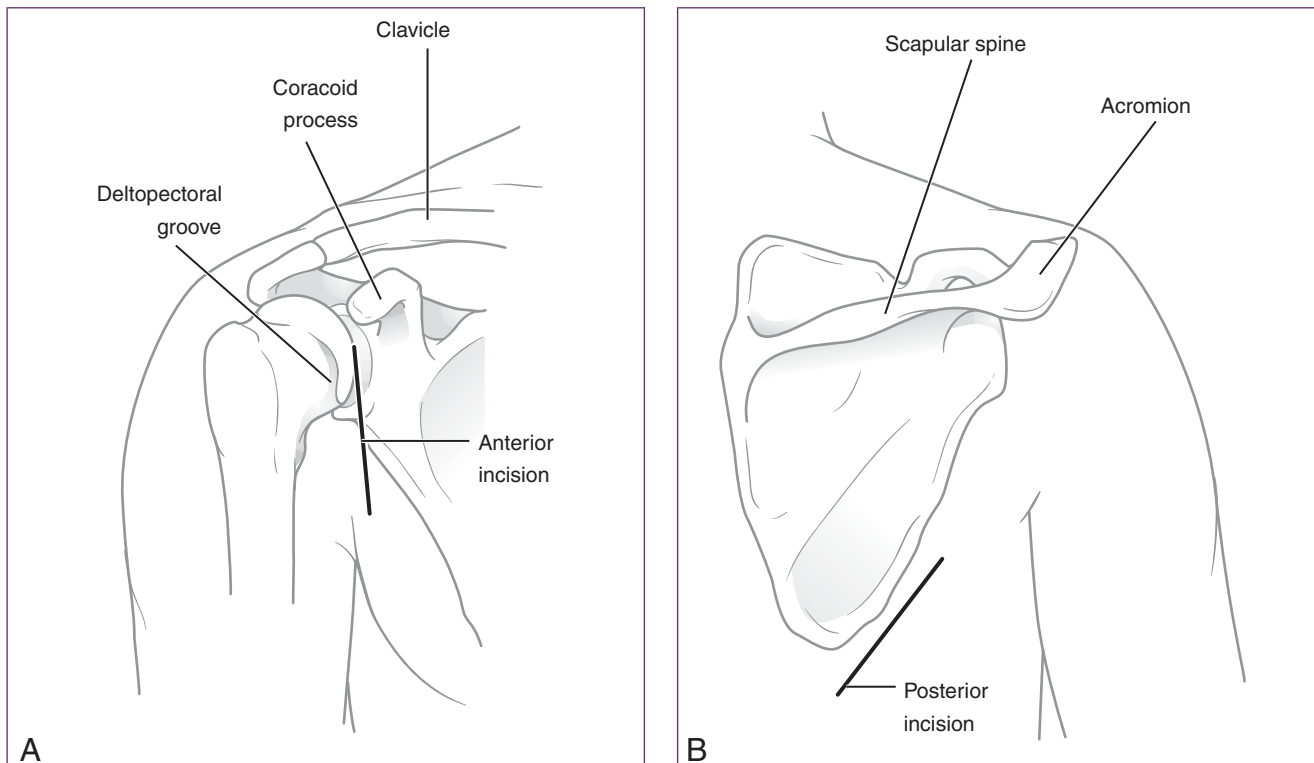


Figure 2 Anterior (left) and posterior (right) incisions.

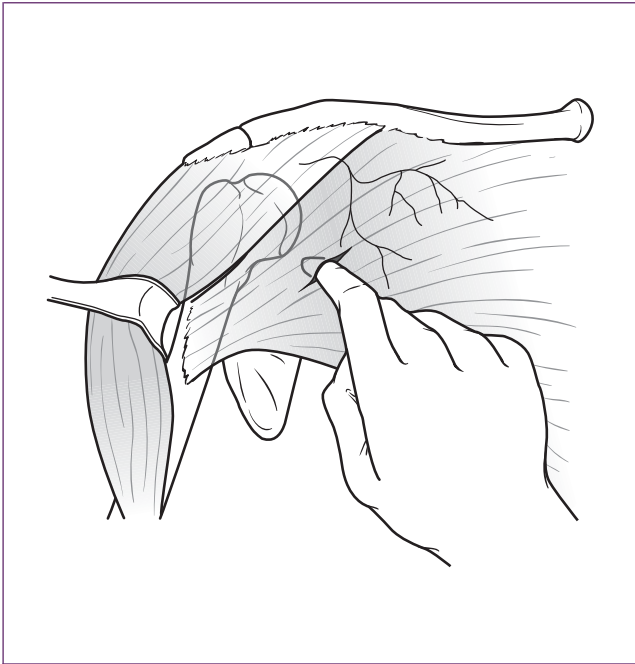


Figure 3 Raphe between sternal and clavicular heads. The surgeon's finger bluntly dissects between the two heads of the pectoralis muscle.

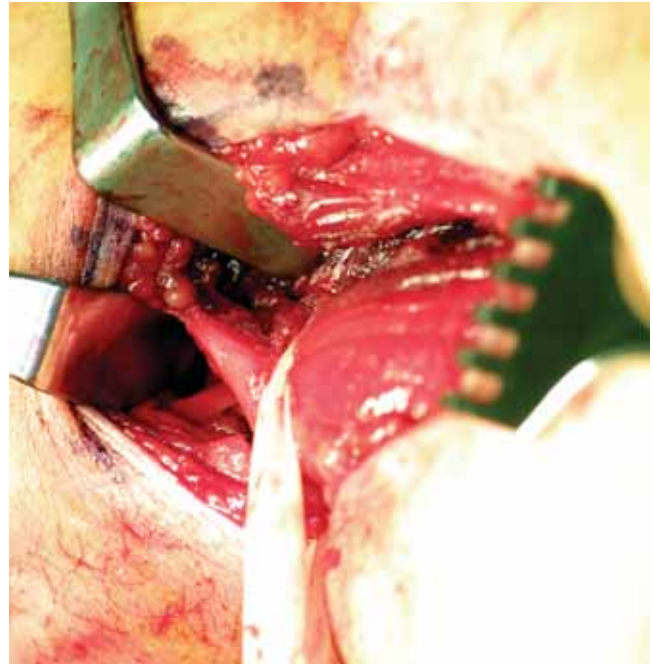


Figure 4 The sternal head of the pectoralis major marked with Penrose drain, with the retractors pulling the clavicular head superiorly.

nal tendon is clearly identified and exposed at its insertion on the humerus.

A Penrose drain is passed around the sternal head and used for traction while dissecting in a lateral direction toward the insertion site (**Figure 4**). The tendon is sharply taken off the humerus while protecting the long head of the biceps, which is located directly underneath. Medial dissection frequently is required to release the sternal head from surrounding soft tissue, including fibrous bands to the clavicular head. However, overly aggressive mobilization can lead to denervation and thus should be avoided.

GRAFT PREPARATION

With adequate release of the pectoralis tendon off its humeral insertion site, tendon length is usually sufficient to reach the inferior border of the scapula, but the tendon is frequently not long enough for passage through the drill hole and secure fixation. A semitendinosus autograft or allograft can be used to lengthen and reinforce the

construct. If harvesting an autograft, the ipsilateral knee should be prepared and draped free. The graft tendon is doubled on itself with the free ends sutured together, and is woven through the pectoralis tendon. The usually broad pectoralis tendon insertion is then tubularized around the graft tendon for a length of about 3 cm using heavy nonabsorbable suture (**Figure 5**). A tagging suture is then placed through the graft tendon to facilitate passage of the construct during the next step.

SCAPULA PREPARATION

The inferior pole of the scapula is directed toward the posterior incision through gentle longitudinal traction of the arm and manual displacement of the inferior pole of the scapula anteriorly and laterally. After superficial dissection, the latissimus muscle is split in line with its fibers and retracted. The subscapularis, infraspinatus, and serratus anterior muscles are dissected subperiosteally to expose

the inferior pole of the scapula. A malleable or similar retractor is placed between the scapula and chest wall for protection during drilling. Subsequently, a 7-mm drill or reamer is used to create a hole at the inferior angle of the scapula. The point of entry is in the thin bone just proximal to the thickened medial and lateral scapular edges, resulting in bone bridges of approximately 6 to 8 mm from the medial, inferior, and lateral borders of the scapula (**Figure 6**).

Using blunt digital dissection, a plane between the latissimus and the chest wall is developed to create a tunnel connecting the anterior and posterior approaches. The tunnel should be of adequate size to facilitate graft passage and allow unrestricted tendon excursion. A long hemostat is directed through the tunnel from posteriorly to retrieve the tagging suture and pass the tendon construct. The graft tendon is pulled through the drill hole from anterior to posterior until the end of the pectoralis tendon is in con-

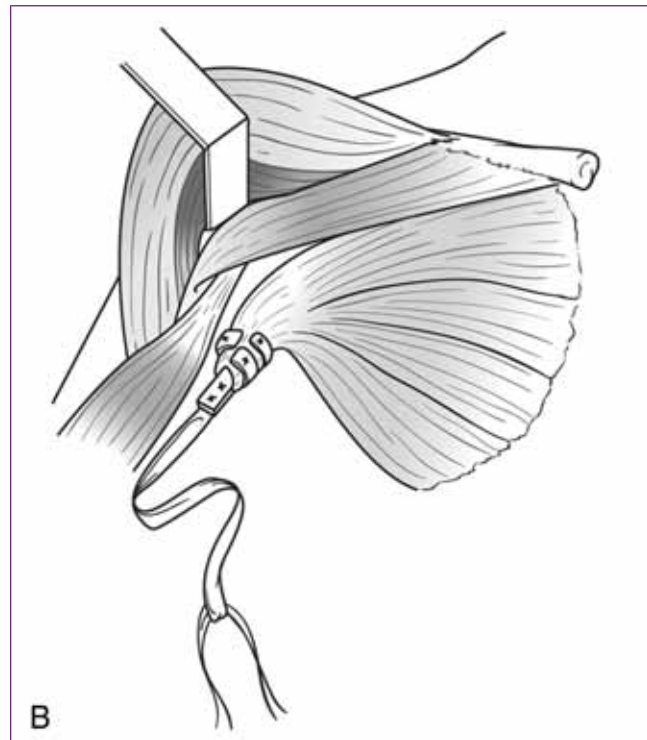
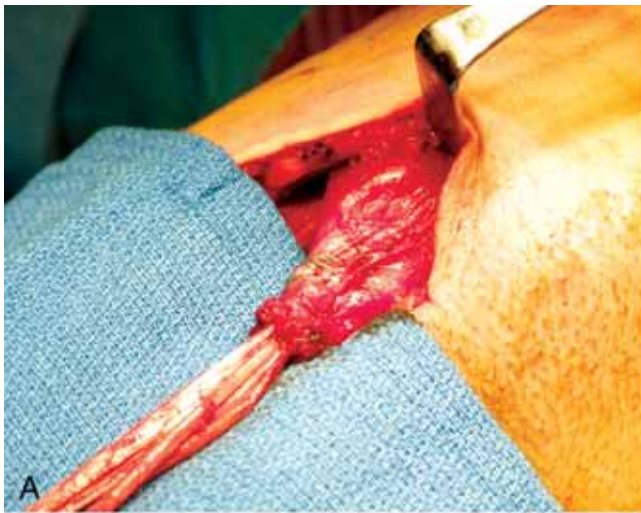


Figure 5 **A**, Graft tendon woven through the sternal head of the pectoralis major. **B**, Intraoperative photograph demonstrating the graft woven through the pectoralis major.

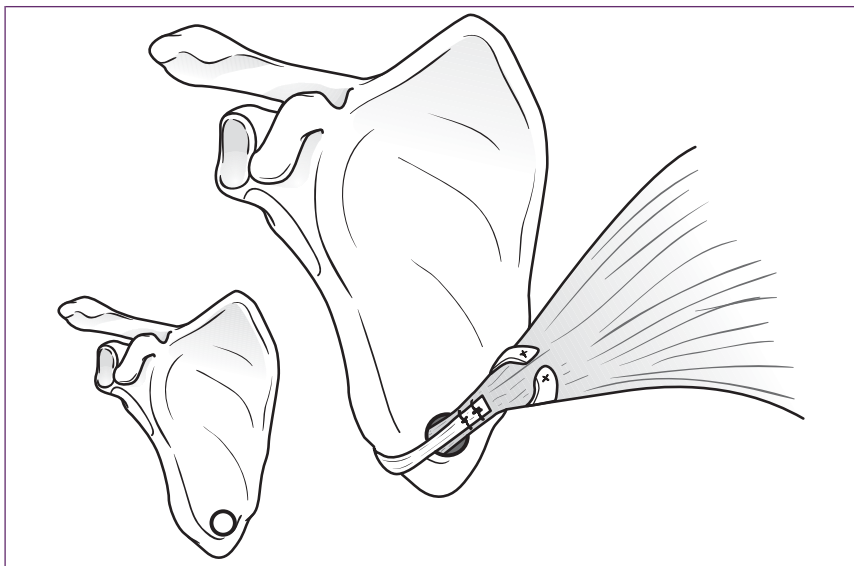


Figure 6 Drill hole through the inferior scapular margin.

tact with the scapula, which should be protracted and pushed as far lateral as possible during this step. The graft tendon is then sewn to itself, the pectoralis major tendon, and the scapular margin with heavy nonabsorbable suture (**Figure 7**).

Wound Closure

Meticulous hemostasis is essential to reduce the risk of hematoma formation; a drain can be used as necessary. The incisions are irrigated and closed in multiple layers to reduce the potential dead space created during the dis-

section, and the skin is closed with a subcutaneous monofilament suture or staples.

Postoperative Regimen

Postoperatively, the upper extremity is immobilized in a sling for 4 weeks. Gentle passive range-of-motion exercises are started on the first postoperative day, preferably performed while supine to stabilize the scapula, to avoid adhesions of the tendon to the surrounding soft tissues. Formal physical therapy is initiated 7 to 10 days postoperatively with scapular isometric exercises with the arm at the side, as along with closed chain protraction and retraction exercises, pendulum exercises, and passive and active assisted forward elevation to 90°, abduction to 90°, and external rotation to 50°. After 6 to 8 weeks, active range of motion without limitations is

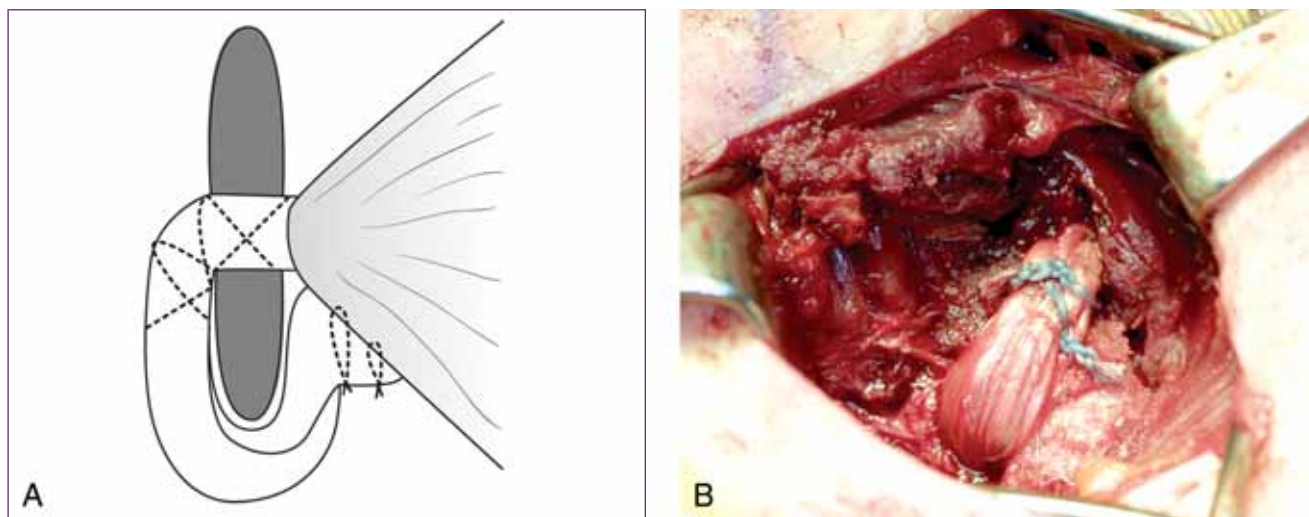


Figure 7 **A**, The graft tendon sutured to itself and the pectoralis major tendon. **B**, Intraoperative photograph demonstrating the graft tendon passed through the scapular drill hole and sutured to itself.

initiated in all planes. At 8 weeks, gentle periscapular strengthening is initiated, which at 12 weeks is expanded to include all muscles about the shoulder. Patients are asked to refrain from lifting more than 25 lb, and to avoid contact sports or significant overhead activities until 6 to 8 months postoperatively.

As with other muscle or tendon transfers, patients will require retraining of the transferred muscle tendon unit. During retraining, the patient is asked to adduct the flexed arm against resistance, which facilitates activation of the muscle transfer. Maintaining adduction and flexing the shoulder anterior to the scapular plane advances this activity. Good results have been reported with additional biofeedback training as part of the postoperative protocol, usually beginning 2 months postoperatively.

Avoiding Pitfalls and Complications

Correct identification of the raphe separating the clavicular and sternal heads of the pectoralis major muscle is essential to avoid injuring the muscle, which could result in denervation and limited excursion.

Correct graft tunnel placement is important to avoid compression of the brachial plexus between the graft and the chest wall. To avoid this complication, the surgeon has to carefully elevate the latissimus and brachial plexus off the chest wall before passing the tendon.

Fracture of the inferior pole of the scapula can occur if the hole is drilled too close to the scapular edge or if overly aggressive physical therapy begins before graft incorporation.

A potential space is created during the dissection between the chest wall and latissimus muscle, placing the patient at risk for hematoma de-

velopment. Meticulous hemostasis, a drain, and activity restriction during the first postoperative week minimize the occurrence of this complication.

To decrease the risk of graft stretching, it is advisable to use a hamstring rather than fascia lata graft, and to double the graft onto itself for added strength. However, the avascular graft is still at risk for elongation and should therefore be used only to augment, not to extend the vascularized pectoralis tendon. If used correctly, the pectoralis major tendon should be in direct contact with the inferior angle of the scapula to allow direct healing of tendon to bone while the graft acts solely to reinforce the tenodesis. To obtain maximum length, the pectoralis tendon should be taken directly off its insertion on the humerus, and fascial bands that are frequently encountered medially should be carefully released during mobilization.

References

- Connor PM, Yamaguchi K, Manifold SG, Pollock RG, Flatow EL, Bigliani LU: Split pectoralis major transfer for serratus anterior palsy. *Clin Orthop Relat Res* 1997;341:134-142.
- Fox JA, Cole BJ: Pectoralis major transfer for scapular winging. *Operative Techniques in Orthopaedics* 2003;13:301-307.
- Litts CS, Hennigan SP, Williams GR: Medial and lateral pectoral nerve injury resulting in recurrent scapular winging after pectoralis major transfer: A case report. *J Shoulder Elbow Surg* 2000;9:347-349.
- Noerdlinger MA, Cole BJ, Stewart M, Post M: Results of pectoralis major transfer with fascia lata autograft augmentation for scapula winging. *J Shoulder Elbow Surg* 2002;11:345-350.
- Perlmutter GS, Leffert RD: Results of transfer of the pectoralis major tendon to treat paralysis of the serratus anterior muscle. *J Bone Joint Surg Am* 1999;81:377-384.
- Post M: Pectoralis major transfer for winging of the scapula. *J Shoulder Elbow Surg* 1995;4:1-9.
- Povacz P, Resch H: Dynamic stabilization of winging scapula by direct split pectoralis major transfer: A technical note. *J Shoulder Elbow Surg* 2000;9:76-78.
- Steinmann SP, Wood MB: Pectoralis major transfer for serratus anterior paralysis. *J Shoulder Elbow Surg* 2003;12:555-560.
- Warner JJ, Navarro RA: Serratus anterior dysfunction: Recognition and treatment. *Clin Orthop Relat Res* 1998;349:139-148.
- Wiater JM, Flatow EL: Long thoracic nerve injury. *Clin Orthop Relat Res* 1999;368:17-27.

Coding

CPT Codes

23395	Muscle transfer, any type, shoulder or upper arm; single
-------	--

Corresponding ICD-9 Codes

736.89	
--------	--

CPT copyright © 2006 by the American Medical Association. All Rights Reserved.