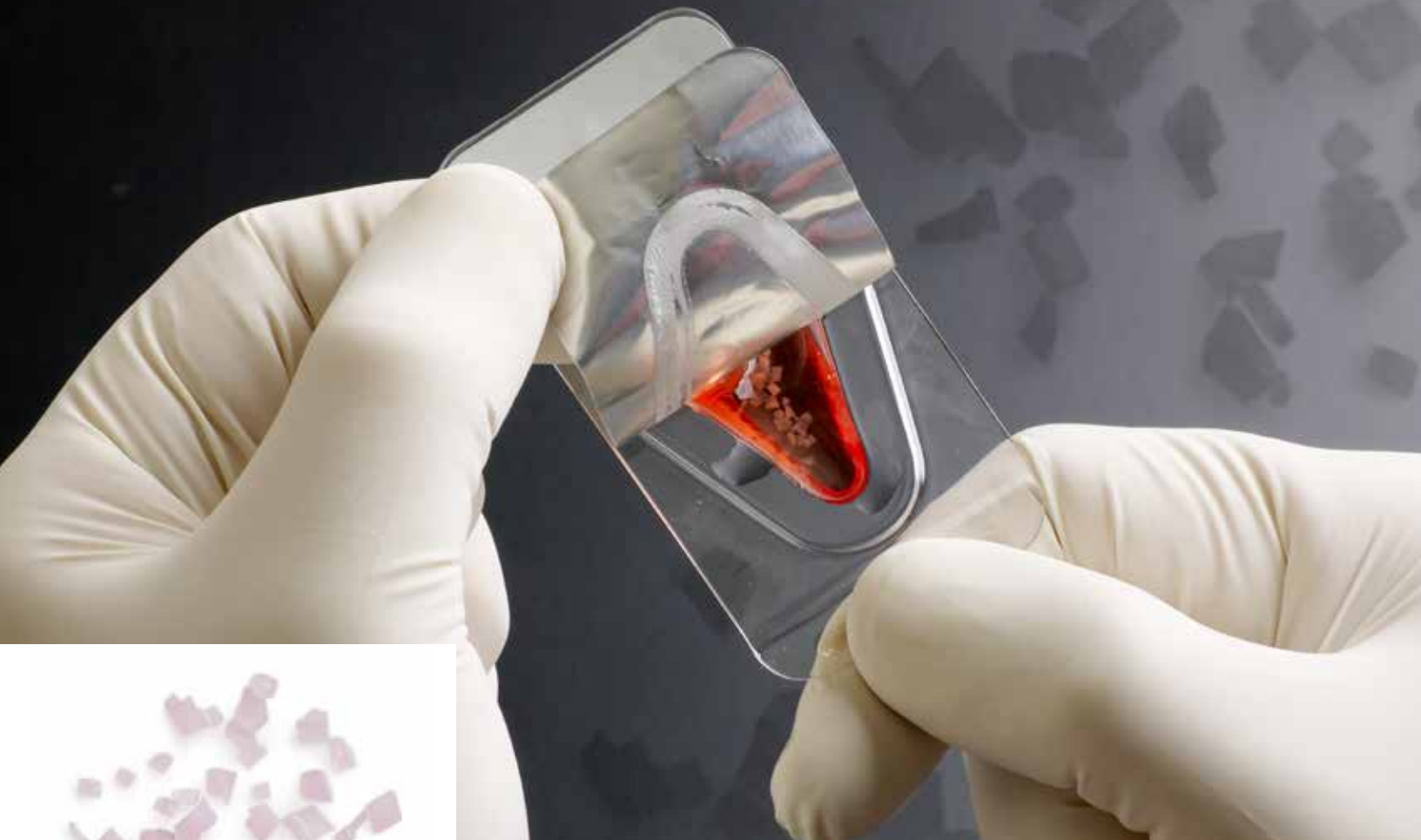



Zimmer®  
DeNovo® NT  
Natural  
Tissue Graft



Biologic treatment for early intervention and cartilage repair.

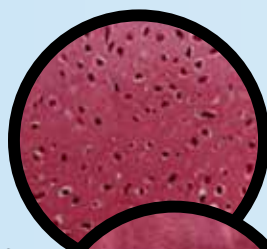


## DeNovo NT Graft – Advancing the Science of Cartilage Repair.

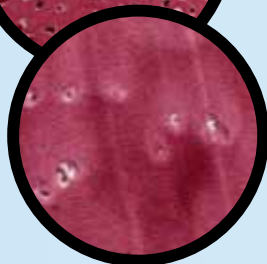*DeNovo NT* Natural Tissue Graft is a juvenile cartilaginous allograft tissue intended to provide surgeons with an early-intervention option for the repair of articular cartilage in a wide range of anatomic focal cartilage defects. It offers a single-stage procedure with fibrin fixation that eliminates the need for harvesting a periosteal flap. With *DeNovo NT* Graft, Zimmer demonstrates its commitment to leadership in providing surgeons – and their patients – with a complete continuum of joint care.

### Juvenile Cartilage Tissue

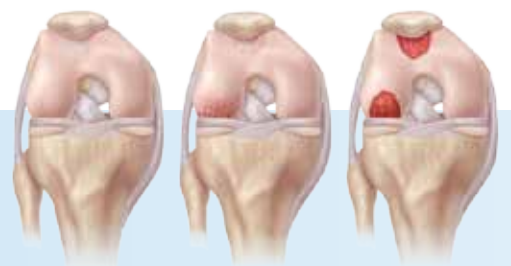
*DeNovo NT* Graft consists of scaffold-free living articular cartilage, displaying biochemical properties similar to those of articular cartilage found in young, healthy joints.



Juvenile Cartilage  
400X



Adult Cartilage  
400X



### Cartilage Injury and Treatment

- Adult articular cartilage has limited capacity for self-repair.<sup>1</sup>
- Untreated focal defects begin a cycle of cartilage breakdown, arthritic degeneration and ultimately, the need for joint replacement.

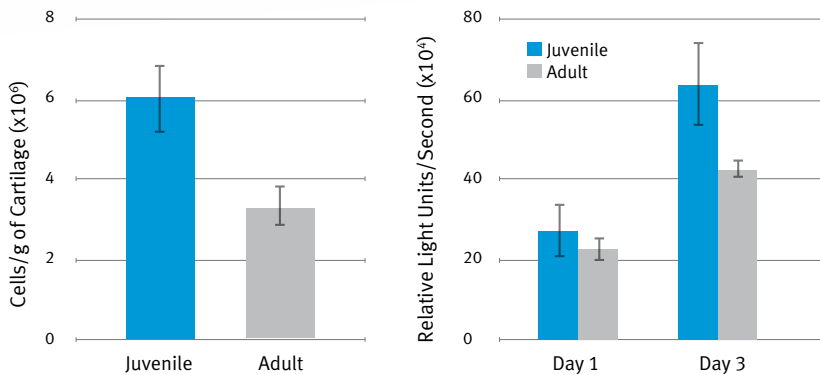
*DeNovo NT* Graft offers a simple alternative to focal cartilage defect treatment.



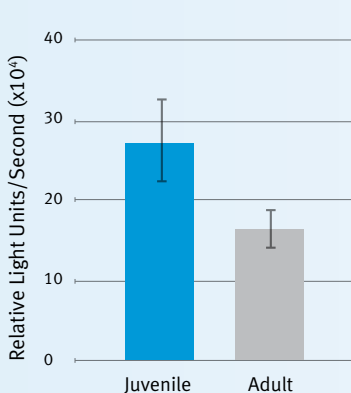
## Clinical Experience

- Human clinical experience includes 6 years of implant history and greater than 7,000 grafts.
- *DeNovo* NT Graft has been used to treat focal defects in a wide range of anatomical applications, including:
  - Knee (i.e., condyle, trochlea, patella, tibial plateau)
  - Foot and ankle (i.e., talus, MPJ)
  - Elbow
  - Shoulder (i.e., humeral head, glenoid)
  - Hip (i.e., acetabulum, femoral head)
- Clinical trials in both the ankle and knee demonstrate significant improvement in patient reports of pain, function, and activity scores (KOOS, AOFAS, FAAM, and VAS Pain Scale)<sup>2-4</sup>

Pre-Clinical Evidence from Studies of Bovine Chondrocytes\*

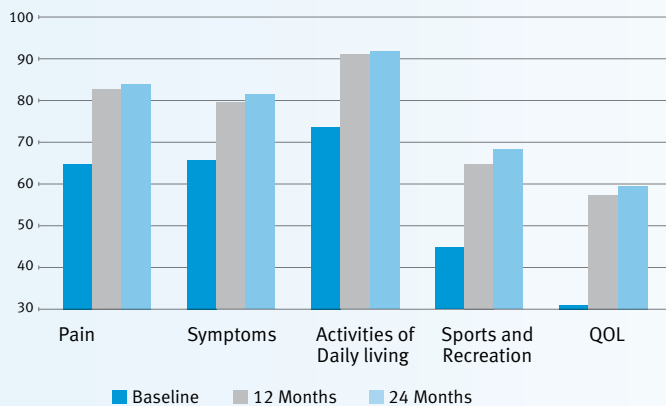


Juvenile bovine cartilage has a significantly higher cell density than adult cartilage ( $p < 0.05$ ), and juvenile bovine chondrocytes have significantly higher proliferation rate than adult chondrocytes (Day 3,  $p < 0.01$ ).

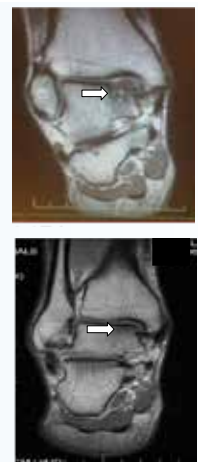

Juvenile chondrocytes synthesize significantly greater amount of GAG than adult chondrocytes ( $p < 0.05$ ). ("GAG" is glycosaminoglycan, a naturally occurring carbohydrate found in cartilage that decreases inflammation and serves as the building blocks of new cartilage.)

Knee Injury and Osteoarthritis Outcome Survey Results for Study Patients



Outcome scores in 25 knee patients 24 months following *DeNovo* NT Graft implant. Significant improvement over baseline is seen for pain, symptoms, functions and sports ( $p < 0.05$ ).



MRI of 35 year old male with medial talus lesion, preoperative (top) and 6 months after *DeNovo* NT Graft surgery (bottom).

\* Animal Study results are not necessarily predictive of human results.

## Comparing Cartilage Defect Repair Treatment Alternatives

	Defect Characteristics	Tissue Characteristics	Procedure Characteristics
<i>DeNovo</i> NT Graft	Chondral defects up to 5 cm <sup>2</sup> (greater at surgeon's discretion)	Juvenile ( $\leq$ 13 yrs) hyaline cartilage, risk of disease transmission	Single stage surgery, simple technique with fibrin fixation, may be done arthroscopically, used in multiple joints including knee (patellofemoral & condyle)
Autologous Chondrocyte Implantation (ACI)	Chondral femoral defects; routinely 5 to 10 cm <sup>2</sup>	Adult autologous chondrocytes	One or two-stage surgical procedure, fixation from scaffold or cover subsequent reoperations common <sup>5</sup>
Bone Marrow Stimulation*	Chondral; limited treatment area < 2 cm <sup>2</sup>	No tissue implanted, fibrous repair tissue <sup>6-7</sup>	Single stage surgery, simple technique, may be done arthroscopically
Osteochondral Autograft	Osteochondral; limited treatment area < 2 cm <sup>2</sup>	Adult autologous tissue from non-weight bearing surface	Single stage complex procedure, perpendicular access to defect required, donor site morbidity
Osteochondral Allograft	Osteochondral; large defects > 2 cm <sup>2</sup>	Adult allograft tissue, risk of disease transmission, typical wait period for graft availability	Single stage complex procedure, perpendicular access to defect required
Micronized Cartilage Matrix (BioCartilage®)	Chondral; limited treatment area < 2 cm <sup>2</sup>	Dehydrated, micronized adult cartilage	Single stage surgery, augment to bone marrow stimulation procedures, no published clinical evidence

\* e.g., debridement, microfracture, chondroplasty, subchondral drilling, etc.

### References:

1. Liu, Zhao, Clarke, Gao, Garrett, Margerrison. Enhanced Tissue Regeneration Potential of Juvenile Articular Cartilage. *Am J Sp Med*. 2013. In Press
2. Farr and Yao. *Cartilage* Oct 2011; 2(4):346-353
3. Cole, Farr, and Tabet. Arthroscopy Association of North America Annual Meeting, April 2013.
4. Coetzee, Giza, Schon, Berlet, Neufeld, Stone, and Wilson. Treatment of Osteochondral Lesions of the Talus With Particulated Juvenile Cartilage. *Foot Ankle Int*, online 10 April 2013. DOI: 1071100713485739.
5. Harris, Siston, Brophy, Lattermann, Carey, and Flanigan. Failures, re-operations and complications after autologous chondrocyte 400 implantation – a systematic review. *Osteoarthritis and Cartilage*, 2011. 19: 779-791.
6. M. Asik, F. Ciftci, C. Sen, M. Erdil and A. Atalar. The microfracture technique for the treatment of full-thickness articular cartilage lesions of the knee: Midterm results. *Arthroscopy: The Journal of Arthroscopic and Related Research*, 2008. 24(11): 1214-1220.
7. Mithoefer, K., McAdams, T., Williams, R. J., Kreuz, & Mandelbaum, B. Clinical Efficacy of the Microfracture Technique for Articular Cartilage Repair in the Knee. *Am. J. Sports. Med*, 2009. 37(10): 2053-2063.

Contact your Zimmer representative or visit us at [www.zimmer.com](http://www.zimmer.com)

